

# Central airway abnormalities - More than meets the eye

Swish Kumar Singh<sup>1</sup>, Manisha Jana<sup>1</sup>, Ashu Seith Bhalla<sup>1</sup>, Priyanka Naranje<sup>1</sup>, Animesh Ray<sup>2</sup>, Manish Soneja<sup>2</sup>, Adil Rashid Khan<sup>2</sup>

<sup>1</sup>Department of Radiodiagnosis, AIIMS, New Delhi, India, <sup>2</sup>Department of Medicine, AIIMS, New Delhi, India

## ABSTRACT

Central airway abnormalities are the most overlooked part of the respiratory system during high-resolution computed tomography thorax specifically when these are subtle and read by less experienced eyes. In this article, we have tried to emphasize the importance to include central airways in reporting checklist. Systematically, analysis of airways can give important clues and narrow down the differentials and clinch the diagnosis in some cases like in our index one.

**KEY WORDS:** Central airways, stridor, virtual bronchoscopy

**Address for correspondence:** Dr. Manisha Jana, Department of Radiodiagnosis, AIIMS, New Delhi, India.  
E-mail: manishajana@gmail.com

**Received:** 08-Feb-2021    **Accepted:** 12-Feb-2021    **Published:** 30-Apr-2021

## INTRODUCTION

Abnormalities of the airways may be overlooked on imaging; more so if it is subtle. Evaluation of airways with great details has become possible with proper acquisition and reformations in modern day CT scanners. This article describes the imaging findings of central airway abnormality in a lady; with an approach to diagnosis for the same.

## CASE REPORT

A 37-year-old female presented to our medicine outpatient department with shortness of breath for the last 3 months, which was progressively increasing. She had a history of joint stiffness and polyarthralgia involving small as well as large joints for the last 9 months. Four months later, she developed pain and redness in the right eye which was followed by its blackish discoloration. Similar complaints were noted in the left eye also after 1 month. Subsequently, discoloration of the right toes was also noted 10 days back, which progressed to all toes of bilateral

upper and lower limbs. Initially, she was being treated elsewhere with a provisional diagnosis of rheumatoid arthritis. Simultaneously, she was also on some unknown ayurvedic treatment.

She was a nondiabetic but hypertensive, which was diagnosed 1 year back, but she was not on any antihypertensive regimen. Detailed history did not reveal any significant prior comorbidities.

On general examination, mild pallor was noted. Diffuse respiratory wheeze was noted on auscultation. All peripheral pulses were palpable and of normal rate and rhythm. Ophthalmic examination revealed scleral thinning with bilateral necrotizing scleritis. Laboratory parameters revealed raised total leukocyte count at the time of admission (22,000/cumm) but during the hospital course reduced to 13,000/cumm. Kidney function tests were within normal limits. D-dimer was markedly raised with a value of 4728 (N: 0–255 ng/ml), but screening for lupus anticoagulant was negative. Galactomannan level in bronchoalveolar

This is an open access journal, and articles are distributed under the terms of the Creative Commons Attribution-NonCommercial-ShareAlike 4.0 License, which allows others to remix, tweak, and build upon the work non-commercially, as long as appropriate credit is given and the new creations are licensed under the identical terms.

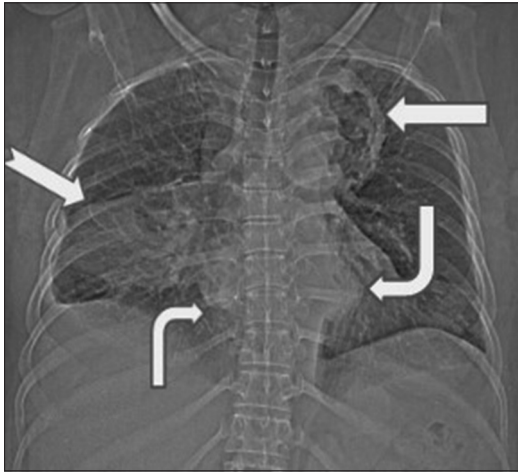
**For reprints contact:** WKHLRPMedknow\_reprints@wolterskluwer.com

**How to cite this article:** Singh SK, Jana M, Bhalla AS, Naranje P, Ray A, Soneja M, *et al.* Central airway abnormalities – More than meets the eye. Lung India 2021;38:280-3.

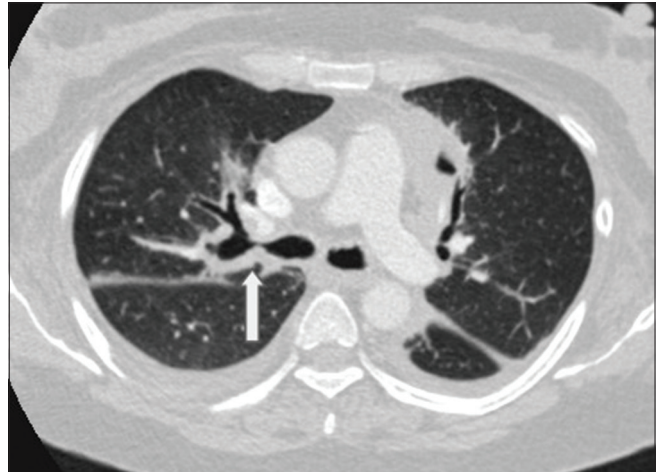
Access this article online	
<b>Quick Response Code:</b> 	<b>Website:</b> www.lungindia.com
	<b>DOI:</b> 10.4103/lungindia.lungindia_87_21

lavage fluid was also within normal limits. Ziehl-Neelsen stain for acid-fast bacilli from the aspirate was also negative.

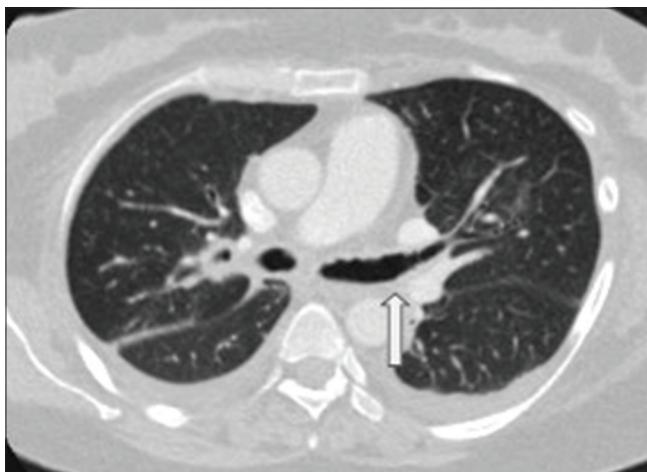
High-resolution computed tomography (CT) thorax was done for her imaging work-up.



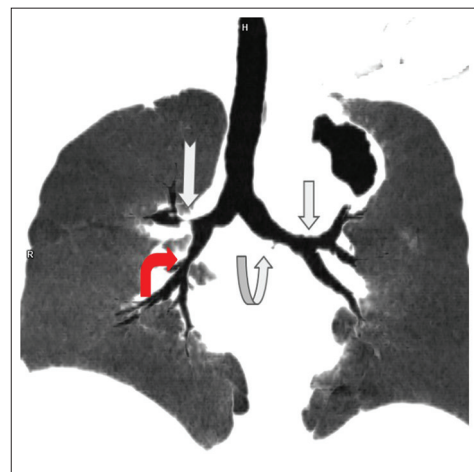
**Figure 1:** Computed tomography topogram reveals thick-walled cavitory lesion in the left upper zone (arrow). Large mass-like consolidation in the right lower zone (curved arrow). Two paravertebral opacities on either side in the retrocardiac region (curved arrows)



**Figure 2:** Computed tomography thorax axial lung window reveals narrowing of the right main bronchus (arrow)



**Figure 3:** Coronal Minimum intensity projection (MinIP) image reveals mucosal irregularity of the left main bronchus (arrow), small diverticulum (curved arrow), marked stenosis of the right upper lobar segmental bronchus (notched arrow), and mild attenuation of the right lower lobe bronchus (bent arrow)



**Figure 4:** Volume-rendering technique image reveals small diverticulum (curved arrow) and marked stenosis of the right upper lobar segmental bronchus (notched arrow)

**QUESTION**

What is the likely diagnosis?

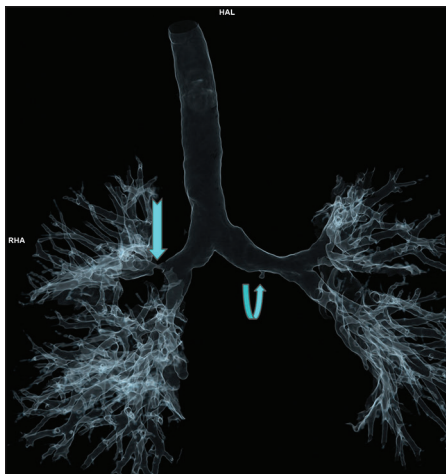
**ANSWER**

Central airway involvement in granulomatous polyangiitis (GPA).

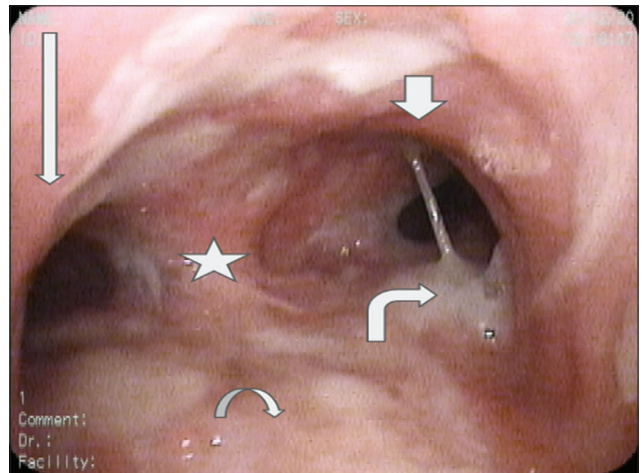
CT topogram [Figure 1] revealed a large irregular thick-walled cavity in the paramediastinal region of the left upper zone. Large mass-like consolidation was also noted in the right lower zone. Two paravertebral masses were also noted on either side in the retrocardiac region.

Ill-defined narrowing of the right main bronchus lumen was also seen [Figures 2-4]. Mucosal surface irregularity in the proximal segment of both main bronchi along with low-density mural thickening of main bronchi was also noted [Figure 5]. Small diverticulum arising from the inferomedial surface of the left main bronchus was also present [Figures 3 and 4]. These findings were also confirmed on fiber-optic bronchoscopy.

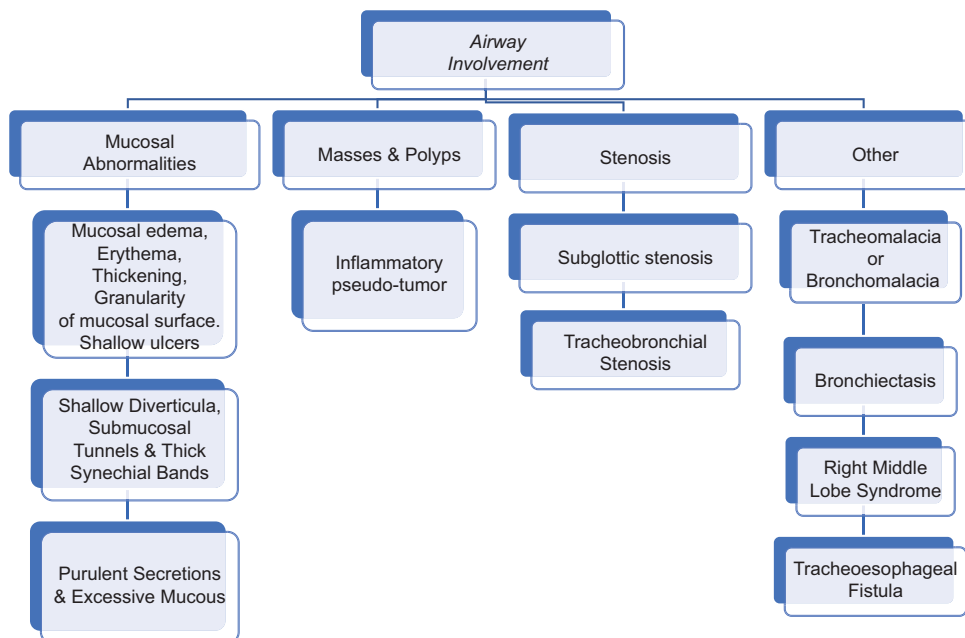
Routine examination of urine revealed active urinary sediments. Vasculitic work-up revealed raised cytoplasmic antineutrophil cytoplasmic antibody (ANCA) level (44 U/ml), whereas perinuclear ANCA was normal (2 U/ml). Bronchoscopy revealed multiple tracheal erosions from which sampling was done [Figure 6].



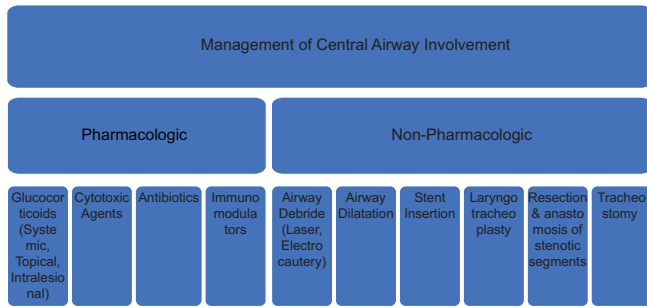
**Figure 5:** Computed tomography thorax axial lung window reveals mucosal irregularity of the left main bronchus (arrow)



**Figure 6:** Bronchoscopy image reveals left main bronchus (long arrow), right main bronchus (short arrow), carina (star), posterior tracheal wall (curved arrow), and tracheal wall necrosis with whitish exudate (bent arrow)



**Organogram 1:** Airway involvement in granulomatous polyangiitis



**Organogram 2:** Management of airway involvement in granulomatous polyangiitis

Based on the clinical, biochemical, imaging, and bronchoscopy findings, a diagnosis of GPA was made.

## DISCUSSION

Granulomatous polyangiitis (previously known as Wegener's granulomatosis) is characterized by necrotizing granulomatous inflammation of small arteries, arterioles, capillaries, and venules. Its clinical spectrum ranges from "limited disease" affecting the nasal and paranasal tract to "aggressive multisystem inflammation" causing multi-organ failure. Pulmonary parenchymal involvement of GPA is well described in literature, but central airway (tracheobronchial) involvement is a relatively less commonly described entity in literature in spite of 15%–55% of involvement in patients with GPA.<sup>[1]</sup> Patients younger than 30 years of age and females are at higher risk to develop central airway involvement.<sup>[1]</sup>

Common symptoms in airway involvement of GPA are usually nonspecific which include hoarseness, cough, hemoptysis, dyspnea, stridor, and wheezing. Subglottic stenosis is the most common cause of stridor in GPA.<sup>[1]</sup> For stridor, differential diagnoses include foreign body aspiration, trauma, acute vocal cord paralysis, papillomatosis, and malignancy. GPA should be kept in differentials in asthmatic patients, particularly not responding to therapy.<sup>[1]</sup> Ulcerated lesions can cause hemoptysis, but usually, it is mild in amount.

Spirometric analysis, particularly inspiratory and expiratory flow volume tracings, can help in determining the severity of the tracheobronchial stenosis and its assessment for its therapeutic success.<sup>[1]</sup>

Airway abnormalities are difficult to pick on imaging. Usually, they are in the form of focal segmental stenosis, intra- or extraluminal soft-tissue lesions, or mural thickening causing luminal attenuation<sup>[2]</sup> [Organogram 1]. Associated calcification and thickening of the tracheal rings as well as

bronchiectasis is also noted. Most commonly, these findings are picked up on CT. Postprocessing techniques such as virtual bronchoscopy and volume-rendered techniques can also be used to make three-dimensional images of airway involvement. Magnetic resonance imaging can also be used to demonstrate these findings because of its higher soft-tissue resolution, although findings are nonspecific.

Bronchoscopy is the major procedure for evaluation as well as management of central airway involvement in any disease. It can localize and assess the severity of airway involvement which could further be used for bronchoscopic management. Sampling can also be done at the time of the procedure. Follow-up for the efficacy of management could also be done by bronchoscopy.

For central airway involvement, management is classified into pharmacological and nonpharmacological types [Organogram 2]. General principles of pharmacological management of GPA are also applied in central airway lesions, which consist of two main components:<sup>[3]</sup>

- Induction of remission with initial immunosuppressive therapy
- Maintenance of remission with immunosuppressive therapy for a variable period to prevent relapse.

Nonmedical therapies are usually invasive procedures which relieve the airway obstruction by mechanical method<sup>[1]</sup> [Organogram 2].

### Declaration of patient consent

The authors certify that they have obtained all appropriate patient consent forms. In the form the patient(s) has/have given his/her/their consent for his/her/their images and other clinical information to be reported in the journal. The patients understand that their names and initials will not be published and due efforts will be made to conceal their identity, but anonymity cannot be guaranteed.

### Financial support and sponsorship

Nil.

### Conflicts of interest

There are no conflicts of interest.

## REFERENCES

1. Polychronopoulos VS, Prakash UB, Golbin JM, Edell ES, Specks U. Airway involvement in Wegener's granulomatosis. *Rheum Dis Clin North Am.* 2007;33:755-75, vi.
2. Screaton NJ, Sivasothy P, Flower CD, Lockwood CM. Tracheal involvement in Wegener's granulomatosis: Evaluation using spiral CT. *Clin Radiol* 1998;53:809-15.
3. Yates M, Watts RA, Bajema IM, Cid MC, Crestani B, Hauser T, *et al.* EULAR/ERA-EDTA recommendations for the management of ANCA-associated vasculitis. *Ann Rheum Dis* 2016;75:1583-94.