



OPEN ACCESS

Transcatheter aortic valve replacement: a palliative approach to infective endocarditis

Christine P Shen , Marissa A Munsayac, Austin A Robinson, Curtiss T Stinis

Cardiology, Scripps Health, San Diego, California, USA

Correspondence to

Dr Christine P Shen;
shen.christine@scrippshealth.org

Accepted 19 April 2022

SUMMARY

An 88-year-old man with small lymphocytic lymphoma presented to the hospital with shortness of breath and was diagnosed with heart failure. Serial blood cultures and echocardiography revealed *Staphylococcus epidermidis* endocarditis, complicated by severe aortic regurgitation. Despite intravenous antibiotic therapy and aggressive intravenous diuresis therapy in the hospital, he decompensated into cardiogenic shock, requiring invasive haemodynamic monitoring and inotrope therapy. With multidisciplinary discussion involving the patient and his children, there was a joint decision that at his advanced age, he would not pursue surgical aortic valve replacement and instead proceed with a transcatheter aortic valve replacement (TAVR) with palliative intent. He underwent TAVR with subsequent symptomatic and functional improvement as well as resolution of cardiogenic shock.

BACKGROUND

Despite medical advances and new therapies, infective endocarditis has an extremely high 1-year mortality risk of 30% that has not improved.¹ Patients presenting with endocarditis are often older and with multiple comorbidities.² While staphylococcal microorganisms are the most common cause of endocarditis, coagulase-negative staphylococci such as *Staphylococcus epidermidis* are less common and when present typically involve prosthetic valve endocarditis or hospital-acquired native valve endocarditis.¹ Nosocomial infection has an even greater mortality, often occurring in patients already acutely ill.³ Antibiotic therapy and surgery are key components of the management of infective

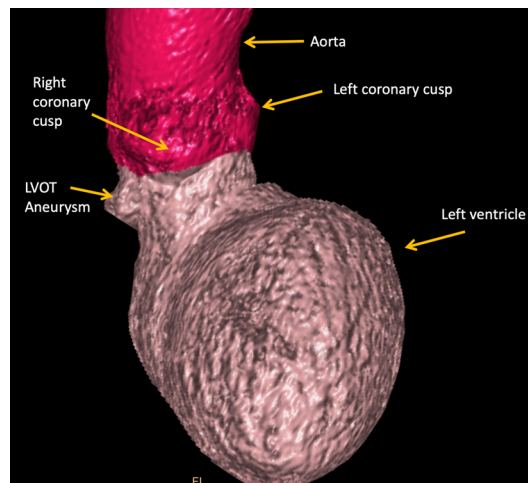


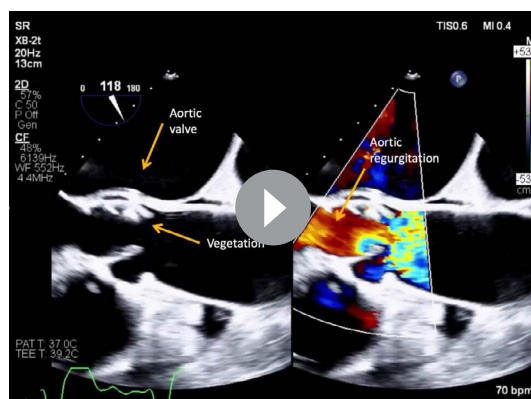
Figure 1 CT reconstruction of aortic root showing a left ventricular outflow tract (LVOT) aneurysm by the right coronary cusp.

endocarditis, and because of the high mortality, it is recommended to have a multispecialty team approach to the disease.⁴

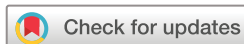Our patient was critically ill with infective endocarditis complicated by cardiogenic shock, but with his advanced age and comorbidities, there was a joint decision with the patient to not pursue surgical intervention. After his subsequent clinical decline into critical condition with aggressive medical therapy, the patient and family requested full-spectrum palliative measures. A focus of this case is an alternative palliative therapy with transcatheter aortic valve replacement (TAVR) for symptomatic and clinical improvement.

CASE PRESENTATION

An 88-year-old man with small lymphocytic lymphoma presented to the hospital with shortness of breath and was diagnosed with heart failure. He had a medical history of benign prostatic hyperplasia status post transurethral resection of prostate, moderate aortic stenosis, paroxysmal atrial fibrillation, essential hypertension and hyperlipidemia. At home, he was taking amlodipine, aspirin, ibuprofen, rosuvastatin and tamsulosin, and he did not have any allergies. He had never smoked and consumed about six alcoholic drinks per week. He was not found with splinter haemorrhages, Osler nodes or Janeway lesions, but he had a new mid-systolic and soft, early diastolic murmur. Transthoracic echocardiogram showed moderate-to-severe aortic stenosis and moderate aortic regurgitation with aortic valve area 1.4 cm² (indexed for body

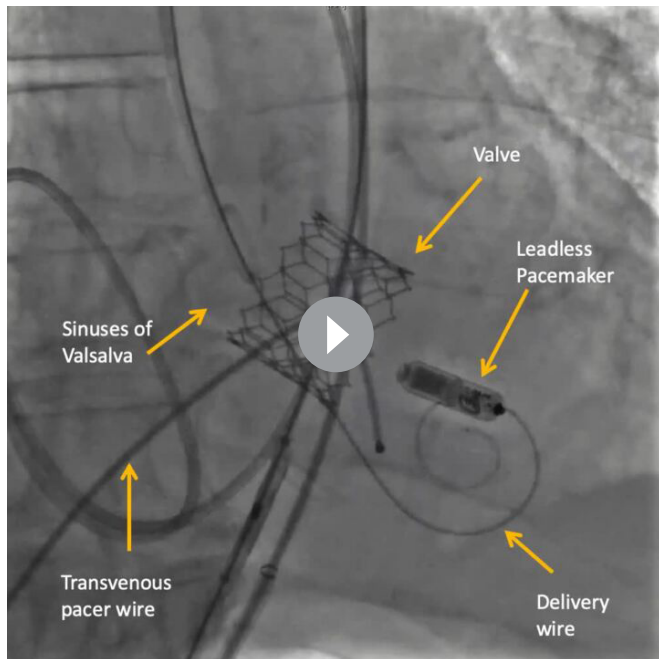


Video 1 Transesophageal echocardiogram showed a large, 13×10 mm vegetation on the non-coronary cusp of the aortic valve contributing to significant leaflet prolapse and severe aortic regurgitation.



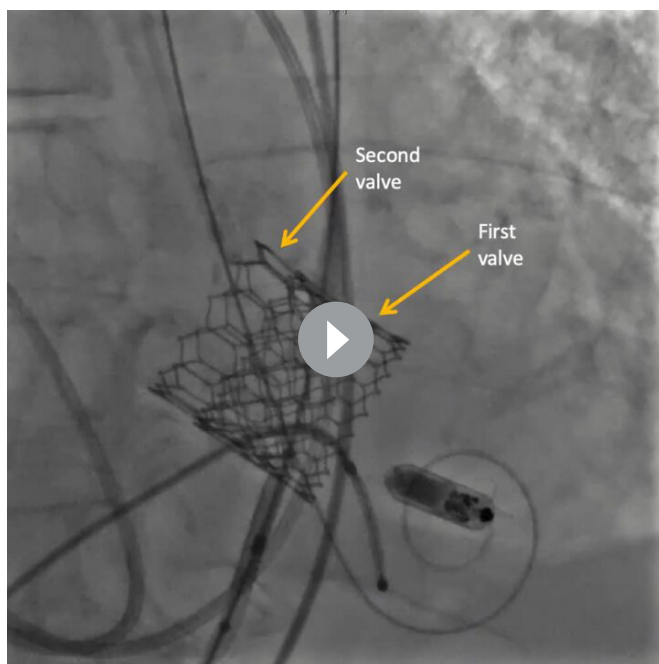
© BMJ Publishing Group Limited 2022. Re-use permitted under CC BY-NC. No commercial re-use. See rights and permissions. Published by BMJ.

To cite: Shen CP, Munsayac MA, Robinson AA, et al. *BMJ Case Rep* 2022;**15**:e248951. doi:10.1136/bcr-2022-248951



Video 2 A 29 mm Edwards Sapien S3 valve was deployed with subsequent perivalvular leak and a partially covered aneurysm of the right coronary cusp on root aortography.

surface area 0.70 cm^2 , peak gradient 75 mm Hg , mean gradient 35 mm Hg , dimensionless index 0.37 , vena contracta 0.63 cm , effective regurgitant orifice 0.47 cm^2 , and pressure half time 173.4 ms . He was initially treated with non-invasive mechanical ventilation and aggressive intravenous diuretic therapy with improvement in his respiratory status. On telemetry monitoring, he was observed to be in slow atrial fibrillation with frequent pauses symptomatic with lightheadedness. Therefore, shortly after admission, he was taken for implantation of a transcatheter



Video 3 A second 29 mm Edwards Sapien S3 valve was advanced across the aortic annulus and deployed in an overlapping fashion. Final aortography showed no significant aortic insufficiency.

leadless pacemaker. Subsequently, his blood culture on admission became positive for *S. epidermidis*, a finding confirmed on multiple repeat blood cultures.

INVESTIGATIONS

Procalcitonin was elevated at 0.50 ng/mL . He did not have a fever on evaluation, highest temperature 37.6°C . He was taken for transesophageal echocardiogram showing a large, $13 \times 10 \text{ mm}$ vegetation on the non-coronary cusp of the aortic valve, with leaflet prolapse and severe aortic regurgitation (video 1). After subsequent decompensation in respiratory status, he was taken for right heart catheterisation showing pulmonary capillary wedge pressure of 32 mm Hg , mixed venous oxygen saturation 34.2% , systemic vascular resistance of $2054 \text{ dyn} \times \text{s/cm}^5$, cardiac output of 2.57 L/min , index of 1.37 L/min/m^2 by thermodilution, and cardiac output of 2.7 L/min , index of 1.4 L/min/m^2 by Fick calculation.

DIFFERENTIAL DIAGNOSIS

While initially thought to be a contaminant, *S. epidermidis* grew on two sets of aerobic and anaerobic bottles, and repeat cultures on two subsequent days were persistently positive, consistent with bacteremia. On review of prior culture data, he had a urine culture growing *S. epidermidis*, untreated, 4 months prior to the hospital presentation in the setting of a bladder stone status post cystolitholapaxy. Further evaluation with transesophageal echocardiography revealed endocarditis with a vegetation, not seen on transthoracic echocardiogram.

TREATMENT

For *S. epidermidis*, he was initially treated with intravenous vancomycin (minimum inhibitory concentration ≤ 0.5). Because of concern for vancomycin-induced acute kidney injury (glomerular filtration rate $36 \text{ mL/min/1.73 m}^2$), the antibiotic was exchanged for daptomycin 8 mg/kg IV every 24 hours for a total of 6 weeks (minimum inhibitor concentration ≤ 1). At his advanced age, he decided not to pursue surgical aortic valve replacement. However, after nearly 2 weeks of intravenous antibiotic therapy, he decompensated into cardiogenic shock requiring three vasopressor and inotrope infusions. He was treated with continuous infusions of bumetanide, dobutamine, milrinone and norepinephrine under close haemodynamic monitoring in the intensive care unit. Several multidisciplinary discussions took place with his primary care physician, palliative care, pulmonary critical care, infectious disease, cardiology, interventional cardiology, and cardiothoracic surgery involving the patient and his children concerning a TAVR versus comfort care measures. Challenges included the potential for embolisation of the vegetation and the presence of a left ventricular outflow tract aneurysm just beneath the level of the annulus (figure 1). His overall goal was to be able to leave the hospital and spend time with his children. Ultimately, there was a joint decision with the team, the patient and his children to proceed with a TAVR with palliative intent. Nearly 4 weeks since his initial presentation, he was then taken for TAVR. This was performed via the percutaneous transfemoral approach under conscious sedation. A Sentinel cerebral embolic protection device was positioned in the brachiocephalic and left carotid arteries at the beginning of the procedure given the vegetations present on the native aortic valve leaflets and retracted after the valves were deployed. Two 29 mm balloon expandable transcatheter valves were deployed in a telescoping manner to successfully

Patient's perspective

Daughter's perspective

My father has had relatively good health all his life. He has always been in charge. My father has always lived independently and even recently renewed his driver's license. A month before he was hospitalised, my father travelled to Hawaii for a month. When I picked him up from the airport, he appeared unusually fatigued. I knew he was in pain from his back, and it was a long trip, so I was not overly concerned. He walked without aid from the car to his bed and slept hard.

The day before he was hospitalised, my sister called to say that my dad was not doing well. I drove down immediately and saw that his legs, feet and ankles were exceptionally swollen. His breathing was also laboured. I thought we should take him to the emergency room, and my sister agreed. My father wanted to wait for his primary doctor, who came by the house a few hours later and asked that we bring my father to his offices the next Monday. On Sunday morning, my father called him and told him that he was feeling worse and having difficulty breathing, and he asked that we bring him to the hospital. In the hospital, he was having trouble breathing and they put him on an oxygen machine that covered his face. That seemed to help immensely. They seemed happy and relieved to offer the care. My father was given Lasix and his legs were leaking fluid onto absorbent pads. The doctor made it clear that my father was in bad shape, stating 'if he makes it'.

The following day, he was feeling better and issuing instructions to pay the housekeeper, flip his mattress at home and asking where his watch is. He was moved out of intensive care unit (ICU). We thought it would be a short stay and quick recovery. The next day, a pacemaker was inserted to stabilise his heart rate. He did not have any discomfort from the pacemaker procedure. Vitals seemed to improve too. We were informed that dad had a blood infection and that would know more in a few days when the culture results were ready. My brother who was visiting reported that dad was in great spirits and eating a spinach omelette, fruit and yoghurt. Another brother reported that dad was speaking clearer and had his spark back. He began IV antibiotic for infection and the doctors were going to check his heart valves.

The day the procedure was scheduled to check valves, his back was hurting. He took a few Tylenols and declined anything stronger. Dad was sleeping during the visit and breathing deeply. This was comforting. I am all too familiar with heart valve infections and am no longer comforted. Dad was up for physical therapy and getting IV treatment for infection. He told me that he lost 20 pounds in water. I had never seen the bones in his feet before. I assumed this was a good thing.

Dad looked the best he had in 2 weeks. I walked with him and the physical therapist up and down the hallway. Small, slow steps but his spirits were good, and he seemed uplifted by the challenge of a little exercise. His appetite was non-existent. The mention of food made him angry. He hated the hospital food, and did not eat food we brought from outside either. Dad was also on fluid restriction. The fluid restriction was by far the worst part of his experience. Truly torture. The doctors asked dad how he was doing. He said, 'Great!' Clearly, he was not great. He was muttering, grunting, sighing continuously. I told him in front of the doctors that it was ok to say how he was really feeling. He was annoyed with me. I was feeling frustrated too.

Unfortunately, he moved back to the ICU, putting him on a BiPAP machine so he could breathe easier. I texted my siblings that dad was losing heart function because of the valve infection. Dad had a restless night and they drugged him up. His cognition was in serious decline.

The next day, there was a team meeting at 3:30. All siblings were there (my sister by phone). This was an amazing day—the entire team of cardiologists, infectious disease, ICU and who knows whom—along with our primary care doctor—were there to discuss my father's case and what options might be available. The risks were clearly presented, no promises were made. I could read body language that not all in attendance thought my father was a good candidate for the transcatheter aortic valve replacement (TAVR). (Valve infection, no FDA approval, body weakening). But my father was up for the task. He asked good questions and reflected on the risks and made his decision. He did not want open-heart surgery (rough, long, recovery). He also did not want to give up and die, so the MacGyver TAVR it was. Now we were going to have to wait and see if he had the right anatomy.

The cardiothoracic surgeon came by to discuss open-heart surgery. He did both my son's open-heart surgeries. Neither dad nor the surgeon thought open heart was a good option despite the valve infection. Dad was appreciative of the conversation and completely at peace with his decision to have the TAVR. We were moving forward with TAVR—yeah!

Another day, I needed to hold him down while the on-duty doctor inserted a probe into his wrist, so they could get a better reading of his heart. I spoke softly to dad during the procedure, held his shoulder steady and asked him to stay very still. This seemed a small thing, but I am not good with blood or anything to do with wrists.

A few days prior to TAVR, dad was deteriorating. My dad's cognition and speech were at a low point. The good news was the interventional cardiologist came by the next morning and dad was alert and clear headed. They had a good conversation and agreed to go ahead with the TAVR. Dad had the necessary tests and procedures for the surgery. His kidney function held. At times, he was completely out of it. Muttering to himself 'I got this', and 'I can do it'.

BIG DAY—SURGERY! Go MacGyver. Praise the Lord, dad made it through the surgery without a breathing tube or general anaesthesia.

The day after, he was back. Dad was issuing orders and asking for visitors. A week later, he did a lap around the nurses' station. He even watched the NBA playoffs with his grandson, looking the best he has for months. Finally, he had sunshine therapy, and he was transferred to a skilled nursing facility. Two months since he first went to the hospital, my brother and I finally picked up dad from the skilled nursing facility. Luckiest day ever! The care from the doctors and nurses was nothing short of amazing. Truly something to behold—brilliant minds, professional behaviour, out of the box thinking and extraordinary communication. I'm not sure how they do it, and I am deeply grateful.

Patient's perspective

Before entering the hospital, I had shortness of breath, weakness and a painful lower back that was a gradual increase over several months. I had swelling in my lower legs, that was gradual with increasing oedema in the ankle and foot. I noticed a gradual loss of mental acuteness and energy for several months. I thought it might have been from a bladder infection that I had.

Continued

Patient's perspective Continued

I do not recall much about the hospital. The worst part was the lower back pain from being moved from bed to gurney etc. The best part was the improvement in my symptoms. I recall talking to the doctors about options. The TAVR procedure seemed like the best choice for me because it would have allowed me to go home.

Immediately after the surgery, I had no chest pain at all. The main discomfort was in my lower back. I could breathe easier, and my cognitive abilities improved. I continue to slowly get better day by day.

How does it feel to be home? GREAT! Oh ya. It feels great to be home.

treat the aortic insufficiency in the setting of a large left ventricular outflow tract aneurysm (figure 1, videos 2 and 3). Final aortography showed no significant aortic insufficiency and complete exclusion of the aneurysm.

OUTCOME AND FOLLOW-UP

Following his TAVR, he did not have any evidence of complications and had significant improvement in his haemodynamics. He was weaned from inotrope and vasopressor support and transferred out of the intensive care unit 7 days after TAVR. Functionally, he improved, able to ambulate 50 feet with a walker around the unit and subsequently discharged home in stable condition 13 days after TAVR and 39 days after initial hospital admission. Follow-up echocardiography showed his bioprosthetic valve without paravalvular leak or evidence of vegetation. His daptomycin therapy completed 6 weeks after the first negative blood culture, 20 days after his TAVR, and thereafter he was treated with doxycycline 100 mg two times per day indefinitely. Six months after his TAVR, he is gaining weight, increasing in exercise tolerance and enjoying time with his family.

DISCUSSION

The diagnosis of infective endocarditis was made by two major criteria: a microorganism consistent with infective endocarditis from persistently positive blood cultures from samples drawn >12 hours apart as well as echocardiography positive for infective endocarditis defined by the presence of a vegetation.¹⁴ Our patient had a nosocomial infective endocarditis with a previous invasive procedure. The vegetation was not seen on transthoracic echocardiogram, which is only moderately sensitive (75%) compared with transesophageal echocardiography (>90%).¹

Guidelines support the evaluation and management of a patient with a multispecialty team.⁴ A transthoracic echocardiogram is recommended as well as transesophageal echocardiogram when the transthoracic is non-diagnostic.⁴ Heart failure is the most common complication of endocarditis.² In our patient, it was a class 1 indication to pursue early surgery for valve dysfunction resulting in heart failure, because surgery has been demonstrated to decrease mortality.^{2 4 5} Overall, surgery is required in 25%–50% of acute cases.⁶ Our patient had multiple factors contributing to an extremely poor prognosis and high mortality risk, including his advanced age, heart failure and haemodynamic compromise.¹ Nosocomial infections in particular are difficult to treat, with mortality higher than that of overall infective endocarditis at 44%, and often even when surgery is indicated, it is not performed because of the critical condition of the patient.^{3 7}

There is a class 2a recommendation for complete removal of pacemaker systems even without evidence of device infection.⁴ Bacteria, in particular staphylococci with a variety of surface adhesions, adhere to host matrix proteins that coat the surface of an implanted device, and further bacteria

accumulates as a biofilm, which is more resistant to antibiotics.⁸ The evidence for leadless pacemakers is limited, but the smaller surface area and encapsulation in the right ventricle decreases the incidence of leadless pacemaker endocarditis even among patients with bacteremia.⁹ Therefore, with the overall low risk of infection and his advanced age, we made a joint decision not to remove his leadless pacemaker.

To our knowledge, there are limited data on the use of TAVR for infective endocarditis management, and active endocarditis is a contraindication for TAVR according to guidelines.^{10 11} In fact, the presence of infective endocarditis following TAVR is a feared complication, with a 1-year mortality of 74.5%.^{12 13} Perhaps future research trials can investigate the safety and efficacy of TAVR for palliation in high surgical risk patients with cardiogenic shock from active endocarditis. While TAVR was not expected to cure his endocarditis, it was hoped to achieve his goal of weaning from haemodynamic support and returning home and an alternative to pursuing comfort care measures in the intensive care unit. Multidisciplinary team discussions took place with extensive discussions regarding the risks, benefits and alternatives. Without intervention, his heart failure required management in the intensive care unit with invasive monitoring and multiple vasopressor and inotrope therapies. Therefore, instead of pursuing comfort care, to help achieve his goal of leaving the hospital and spending time with family, we proceeded with transcatheter valve replacement.

Learning points

- ▶ Nosocomial infective endocarditis complicated by heart failure and cardiogenic shock in an elderly patient has a high mortality risk with limited management options.
- ▶ Future research may investigate the potential role of transcatheter aortic valve replacement for palliation of aortic valve endocarditis with cardiogenic shock in high surgical risk patients.
- ▶ A multidisciplinary approach is crucial to direct complex medical decisions to achieve a patient's goals.

Twitter Christine P Shen @iconsideritjoy

Contributors CPS, MAM, AAR and CTS have contributed to the planning and writing of this manuscript.

Funding The authors have not declared a specific grant for this research from any funding agency in the public, commercial or not-for-profit sectors.

Competing interests CTS is a speaker and proctor for Edwards Lifesciences.

Patient consent for publication Consent obtained directly from patient(s)

Provenance and peer review Not commissioned; externally peer reviewed.

Open access This is an open access article distributed in accordance with the Creative Commons Attribution Non Commercial (CC BY-NC 4.0) license, which permits others to distribute, remix, adapt, build upon this work non-commercially, and license their derivative works on different terms, provided the original work

is properly cited and the use is non-commercial. See: <http://creativecommons.org/licenses/by-nc/4.0/>.

Case reports provide a valuable learning resource for the scientific community and can indicate areas of interest for future research. They should not be used in isolation to guide treatment choices or public health policy.

ORCID iD

Christine P Shen <http://orcid.org/0000-0003-4652-0899>

REFERENCES

- Cahill TJ, Prendergast BD. Infective endocarditis. *The Lancet* 2016;387:882–93.
- Murdoch DR, Corey GR, Hoen B, Presentation C, *et al*. Clinical presentation, etiology, and outcome of infective endocarditis in the 21st century: the International collaboration on Endocarditis-Pro prospective cohort study. *Arch Intern Med* 2009;169:463.
- Prendergast BD. The changing face of infective endocarditis. *Heart* 2006;92:879–85.
- Nishimura RA, Otto CM, Bonow RO, *et al*. 2014 AHA/ACC guideline for the management of patients with valvular heart disease: a report of the American College of Cardiology/American heart association Task force on practice guidelines. *J Am Coll Cardiol* 2014;63.
- Habib G, Hoen B, Tornos P, *et al*. Guidelines on the prevention, diagnosis, and treatment of infective endocarditis (new version 2009): the task force on the prevention, diagnosis, and treatment of infective endocarditis of the European Society of cardiology (ESC). *Eur Heart J* 2009;30:2369–413.
- Prendergast BD, Tornos P. Surgery for infective endocarditis: who and when? *Circulation* 2010;121:1141–52.
- Bouza E, Menasalvas A, Muñoz P, *et al*. Infective endocarditis--a prospective study at the end of the twentieth century: new predisposing conditions, new etiologic agents, and still a high mortality. *Medicine* 2001;80:298–307.
- Baddour LM, Epstein AE, Erickson CC, *et al*. Update on cardiovascular implantable electronic device infections and their management. *Circulation* 2010;121:458–77.
- Bacteraemia after leadless pacemaker implantation - Garweg - 2020 - Journal of Cardiovascular Electrophysiology - Wiley Online Library. Available: <https://onlinelibrary.wiley.com/doi/> [Accessed 20 Jul 2021].
- Santos-Martínez S, Alkhodair A, Nombela-Franco L, *et al*. Transcatheter Aortic Valve Replacement for Residual Lesion of the Aortic Valve Following "Healed" Infective Endocarditis. *JACC Cardiovasc Interv* 2020;13:1983–96.
- Vahanian A, Beyersdorf F, Praz F, *et al*. 2021 ESC/EACTS guidelines for the management of valvular heart disease. *Eur Heart J* 2022;43:561–632.
- Habib G. Infective endocarditis after transcatheter aortic valve replacement: the worst that can happen. *J Am Heart Assoc* 2018;7:e010287.
- Mangner N, Woitek F, Haussig S, *et al*. Incidence, Predictors, and Outcome of Patients Developing Infective Endocarditis Following Transfemoral Transcatheter Aortic Valve Replacement. *J Am Coll Cardiol* 2016;67:2907–8.

Copyright 2022 BMJ Publishing Group. All rights reserved. For permission to reuse any of this content visit <https://www.bmj.com/company/products-services/rights-and-licensing/permissions/>
BMJ Case Report Fellows may re-use this article for personal use and teaching without any further permission.

Become a Fellow of BMJ Case Reports today and you can:

- ▶ Submit as many cases as you like
- ▶ Enjoy fast sympathetic peer review and rapid publication of accepted articles
- ▶ Access all the published articles
- ▶ Re-use any of the published material for personal use and teaching without further permission

Customer Service

If you have any further queries about your subscription, please contact our customer services team on +44 (0) 207111 1105 or via email at support@bmj.com.

Visit casereports.bmj.com for more articles like this and to become a Fellow