

# Successful stent implantation for superior vena cava injury during transvenous lead extraction



Xiaoying Lou, BS,\* Michael P. Brunner, MD,<sup>†</sup> Bruce L. Wilkoff, MD, FHRS,<sup>†</sup>  
David O. Martin, MD, MPH,<sup>†</sup> Daniel G. Clair, MD,<sup>†</sup> Edward G. Soltesz, MD, MPH<sup>†</sup>

From \*Northwestern University Feinberg School of Medicine, Chicago, Illinois, and <sup>†</sup>Cleveland Clinic Foundation, Cleveland, Ohio.

## Introduction

The increased number of implantations of pacemaker and implantable cardioverter-defibrillator (ICD) devices has also generated a rise in the number of lead extraction procedures, with an estimated 10,000 to 15,000 devices extracted annually worldwide.<sup>1</sup>

The difficulty of lead extraction is directly proportional to the severity of the fibrotic and adhesive scar tissue that encases the lead, vascular endothelium, and cardiac chambers. In long-standing leads, calcification can occur. Although a traction and countertraction approach has traditionally been used to facilitate extraction, current methodology favors adding laser-assisted lead extraction to dissect through the fibrosis. Pulses of ultraviolet light are delivered fiberoptically to the distal end of the sheath, promoting sheath advancement. Transvenous extraction with laser sheaths can be performed, with a reported clinical success rate in excess of 95%.<sup>2</sup> However, with or without laser assistance, the risk of complications include death, bleeding, vascular tear, cardiac avulsion, pulmonary embolism, and pericardial effusion.<sup>3</sup>

A recent Cleveland Clinic study of catastrophic complications occurring during transvenous lead extraction demonstrated 25 cases (0.8%) over a 16-year period that required emergent surgical or endovascular intervention.<sup>4</sup> The majority (64%) of deaths and injuries were the result of laceration of the right atrium, superior vena cava (SVC), or innominate vein. Tears in the SVC usually prompt sudden hemodynamic compromise associated with high mortality and generally necessitate immediate surgical intervention. Several cases of SVC rupture have been described in the literature, including a few that were managed successfully with endovascular

stenting.<sup>5–9</sup> We report a rare case of successful, urgent SVC stenting for SVC tear in a patient with previous cardiac surgery undergoing laser lead extraction for ICD pocket infection.

## Case report

The patient was a 58-year-old man with a medical history significant for coronary artery disease, prior coronary artery bypass graft surgery 14 years ago, multiple percutaneous coronary interventions, diabetes mellitus type 2, hypertension, and hyperlipidemia. He also had a history of nonsustained ventricular tachycardia and syncope, for which a dual-chamber ICD was implanted from the left side 4 years earlier. The right ventricular ICD lead was a dual-coil Sprint Fidelis (model 6949, Medtronic Inc, Minneapolis, MN). The patient presented with evidence of pocket infection manifested by erythema and purulent drainage over the superior aspect of the incision. He was nonbacteremic and afebrile, and reported no other systemic symptoms. He was evaluated by the infectious disease department, and the patient was advised to undergo ICD system extraction.

ICD and lead extraction was performed with the patient under general anesthesia in the electrophysiology laboratory. The pocket capsule was dissected out and removed, and the right atrial lead was removed with simple traction. The right ventricular ICD lead could not be removed with simple traction. The lead was secured using a locking stylet (Liberator Universal Locking Stylet, Cook Medical, Bloomington, IN), and a laser sheath (Spectranetics CVX-300 Excimer Laser and Spectranetics Laser Sheath (SLS II), Colorado Springs, CO) was used. There were dense adhesions along the SVC. Countertraction using a snare deployed from a Byrd Workstation Femoral Intravascular Retrieval Set (Cook Vascular, Leechburg, PA) was needed to free the lead. Shortly after the lead and laser sheath were removed, the patient became hypotensive with systolic blood pressure dropping to 30 mm Hg. Intravenous fluids were administered and cardiopulmonary resuscitation was initiated, with restoration of hemodynamic stability. Transthoracic echocardiography was performed to exclude pericardial effusion, and a venogram obtained from the femoral vein demonstrated

**KEYWORDS** Implantable cardioverter-defibrillator; Laser lead extraction; Superior vena cava injury; Stenting

**ABBREVIATIONS** ICD = implantable cardioverter-defibrillator; SVC = superior vena cava (*Heart Rhythm Case Reports* 2015;1:394–396)

**Address reprint requests and correspondence:** Dr. Edward G. Soltesz, Thoracic and Cardiovascular Surgery, Cleveland Clinic Foundation, Mail Code J4-1, 9500 Euclid Ave, Cleveland, OH 44195. E-mail address: SOLTESE@ccf.org.

### KEY TEACHING POINTS

- Complications of laser lead extractions include death, bleeding, vascular tear, cardiac avulsion, pulmonary embolism, and pericardial effusion.
- The majority of deaths and injuries associated with laser lead extractions are the result of laceration of the right atrium, superior vena cava (SVC), or innominate vein.
- Prior to laser lead extraction, a formal evaluation by the cardiothoracic surgery department should be performed for all patients to determine their surgical candidacy.
- In surgically unfit patients or those with hemodynamic instability, endovascular intervention with a covered abdominal aortic stent graft is a viable option for rapid repair of iatrogenic SVC injury sustained during implantable cardioverter-defibrillator lead extraction.

continuous contrast extravasation along the SVC lateral wall extending into the right pleural space (Figure 1). The decision was then made to proceed with an endovascular approach as the quickest access to control the bleeding in light of the prior median sternotomy and comorbidities. A 34-mm CODA endovascular occlusion balloon catheter (Cook Medical) was introduced via the right femoral vein into the SVC and placed at the site of injury to provide temporary occlusion.

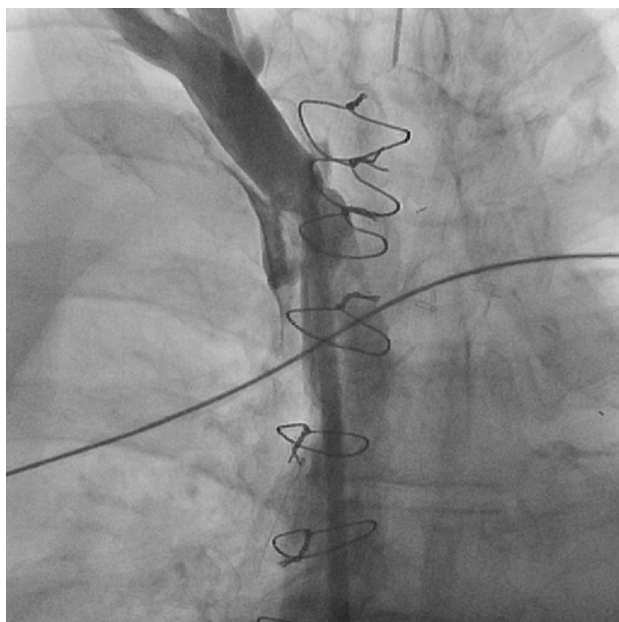
The right common femoral vein was accessed with a 16Fr sheath, and a 23- × 33-mm Gore Excluder Aortic Extender

bioprosthesis (WL Gore & Associates Inc, Fremont, CA) was deployed at the site of SVC injury. The stent graft was subsequently dilated with a 12-mm and 16-mm angioplasty balloon, with exclusion of the injury noted on completion venogram (Figure 2). A right chest tube placed in the pleural cavity drained 4 L of dark blood, and the lung was re-expanded. A total of 12 units of packed red blood cells was transfused intraoperatively.

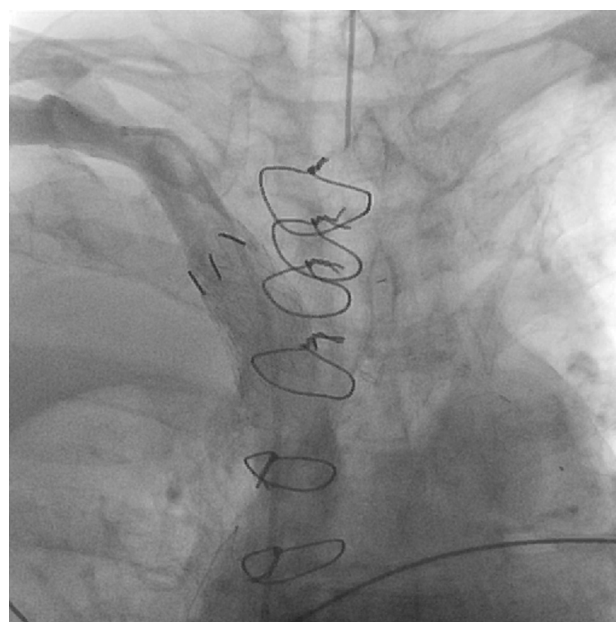
The patient was transferred to the intensive care unit in hemodynamically stable condition. His postoperative course was significant for a stable, asymptomatic right pleural effusion but was otherwise uneventful. He underwent reimplantation of a single-chamber ICD on postoperative day 9 and was discharged to home with a course of intravenous antibiotics on postoperative day 10.

### Discussion

Iatrogenic perforation of the SVC is an uncommon but potentially fatal complication of transvenous lead extraction. Depending on its location, perforation can result in pericardial, mediastinal, or pleural bleeding. Tears below the pericardial reflection leading to pericardial bleeding and tamponade are the most common causes of hemodynamic collapse associated with lead extraction.<sup>5</sup> Bleeding into the pericardium usually can be managed with pericardiocentesis. In this case, however, injury to the lateral wall of the SVC led to bleeding into the right pleural cavity and subsequent lung collapse and hemodynamic compromise that was unresponsive to fluid administration. Mediastinal adhesions from prior cardiac surgery prevented bleeding into the pericardium, and intraoperative transthoracic echocardiography excluded pericardial effusion. Insertion of a chest tube without first managing the tear could have led to the patient's exsanguination.



**Figure 1** Superior vena cava venogram showing a lateral wall tear with extravasation of contrast dye extending into the right pleural space.



**Figure 2** Superior vena cava venogram after covered stent placement showing exclusion of the area of injury.

Historically, SVC perforation has required an open approach with emergency thoracotomy or sternotomy<sup>1</sup> and repair by stitch or patch closure. However, given our patient's comorbidities and history of prior cardiac surgery, rapid access via a reoperative median sternotomy or right anterior thoracotomy would be time consuming, so an endovascular approach was chosen.

General consensus recommends that all patients undergo preoperative evaluation by the cardiothoracic surgery department to determine their surgical candidacy.<sup>5,6</sup> We propose that the decision for open vs endovascular management be based on this initial evaluation. At our institution, a policy is now in place for the cardiothoracic surgery department to formally evaluate before extraction in all patients with leads more than 5 years old or in those perceived to be at high risk (eg, severe calcification of leads, visible adhesion of lead to SVC on preoperative computed tomographic scan). These cases are performed in a hybrid operating room. If the patient is determined to be a surgical candidate, formal surgical backup is provided in the room, and an open or endovascular repair can be immediately attempted depending on the site of SVC perforation and the patient's hemodynamic status. If the patient is determined to not be a surgical candidate, endovascular or conservative management is then decided on preoperatively.

A conservative approach has been successfully used to manage 1 reported case of SVC injury.<sup>7</sup> The patient was a 68-year-old man who underwent placement of a tunneled dialysis catheter complicated by perforation of the SVC. This patient developed a right-sided hemothorax and subsequent hemodynamic instability, with systolic blood pressure dropping to 60 mm Hg. However, normalization of hemodynamic parameters was achieved after fluid resuscitation, transfusion of 2 units of packed red blood cells, and placement of a right-sided thoracostomy tube, which drained 400 mL of blood from the right pleural cavity. Repeat venogram 2 days later revealed a small-contained hematoma beyond the confluence of brachiocephalic veins with no active extravasation of contrast medium into the chest. In contrast, our patient likely suffered a longer, full-thickness SVC perforation with continuous extravasation leading to right lung collapse and more severe hemodynamic compromise that was unresponsive to fluid resuscitation. These factors favored rapid endovascular stenting over conservative management.

A review of the literature has revealed sporadic cases of endovascular stenting in the management of SVC rupture from balloon dilation for SVC syndrome<sup>8,9,10,11</sup> or during left subclavian tunneled dialysis catheter placement.<sup>12</sup> The present case is the first to be described in a patient with previous cardiac surgery and SVC rupture secondary to ICD and laser lead extraction.

Burket<sup>8</sup> reported the first case of an endovascular approach to SVC perforation, which was diagnosed by venography and managed with a 10- × 50-mm Wallgraft stent (Boston Scientific Corp, Natick, MA) deployed in the SVC. A subsequent case reported the use of a 10- × 50-mm Gore Viabahn stent (Gore, Flagstaff, AZ), which was possible given that the SVC measured only 8 mm in diameter at the level of injury.<sup>12</sup>

The SVC is reported to have a mean diameter of 20 mm.<sup>10</sup> To achieve an adequate seal after stenting, the previously mentioned stent grafts may not be large enough. The Wallgraft and Viabahn stents have maximum diameters of 12 and 13 mm, respectively.<sup>10</sup> Larger-diameter covered stents such as those used in abdominal aortic aneurysm repair may thus be necessary. Jean-Baptiste et al<sup>10</sup> reported 2 cases of SVC rupture secondary to balloon dilation of the SVC in which a 20-mm × 3.75-cm AneuRx Aortic cuff (Medtronic AVE, Santa Rosa, CA) and a 16-mm × 5.5-cm AneuRx iliac cuff were successfully stented across the SVC. One additional documented case of an SVC laceration < 10 mm long repaired using two 23- × 33-mm Gore Aortic Extender stent grafts has been reported.<sup>11</sup> However, subsequent dilation with a 16-mm balloon extended the tear, which was managed with deployment of another aortic cuff stent graft. To our knowledge, the present case is the only other successful application of an abdominal aortic stent graft to repair an SVC injury.

Use of endovascular stent grafting to repair central venous perforations and control hemorrhage has been successfully demonstrated through several case reports as an alternative to open surgical repair. In surgically unfit patients or those with hemodynamic instability, endovascular intervention is a viable option for rapid repair of iatrogenic SVC injury sustained during ICD lead extraction. Immediate diagnosis of SVC injury by intraoperative venography and rapid stent deployment were key to the successful management of this patient.

## References

- Hauser RG, Katsiyannis WT, Gornick CC, Almquist AK, Kallinen LM. Deaths and cardiovascular injuries due to device-assisted implantable cardioverter-defibrillator and pacemaker lead extraction. *Europace* 2010;12:395–401.
- Wazni O, Epstein LM, Carrillo RG, et al. Lead extraction in the contemporary setting: the LEXiCon study: an observational retrospective study of consecutive laser lead extractions. *J Am Coll Cardiol* 2010;55:579–586.
- Wilkoff BL, Love CJ, Byrd CL, et al. Transvenous lead extraction: heart rhythm society expert consensus on facilities, training, indications, and patient management. *Heart Rhythm* 2009;6:1086–1104.
- Brunner MP, Cronin EM, Wazni O, Baranowski B, Saliba WI, Sabik JF, Lindsay BD, Wilkoff BL, Tarakji KG. Outcomes of patients requiring emergent surgical or endovascular intervention for catastrophic complications during transvenous lead extraction. *Heart Rhythm* 2014;11:419–425.
- Henrikson CA, Brinker JA. How to prevent, recognize, and manage complications of lead extraction. Part III: procedural factors. *Heart Rhythm* 2008;5:1352–1354.
- Gaca JG, Lima B, Milano CA, Lin SS, Davis RD, Lowe JE, Smith PK. Laser-assisted extraction of pacemaker and defibrillator leads: the role of the cardiac surgeon. *Ann Thorac Surg* 2009;87:1446–1451.
- Kabutay N, Rastogi N, Kim D. Conservative management of iatrogenic superior vena cava perforation after attempted dialysis catheter placement: case report and literature review. *Clin Imaging* 2013;37:1138–1141.
- Burket MW. Challenging cases: superior vena cava rupture. *Endovasc Today* 2003;2:11–13.
- Mansour M, Altenburg A, Haage P. Successful emergency stent implantation for superior vena cava syndrome perforation during malignant stenosis venoplasty. *Cardiovasc Intervent Radiol* 2009;32:1312–1316.
- Jean-Baptiste R, Williams D, Gemmette J. Successful treatment of superior vena cava rupture with placement of a covered stent: a report of two cases. *Cardiovasc Intervent Radiol* 2011;34:667–671.
- Anaya-Ayala JE, Charlton-Ouw KM, Kaiser CL, Peden EK. Successful emergency endovascular treatment for superior vena cava injury. *Ann Vasc Surg* 2009;23:139–141.
- Azizadeh A, Pham MT, Estrera AL, Coogan SM, Safi HJ. Endovascular repair of an iatrogenic superior vena caval injury: a case report. *J Vasc Surg* 2007;46:569–571.