



Contents lists available at ScienceDirect

# AAACE Clinical Case Reports

journal homepage: [www.aaaceclinicalcasereports.com](http://www.aaaceclinicalcasereports.com)



## Case Report

# Voriconazole-Induced Diffuse Periostitis

Simona Stefan, MD<sup>1</sup>, Nadera Altork, MD<sup>2</sup>, Yazan Alzedaneen, MD<sup>2</sup>, Hilary Whitlatch, MD<sup>3</sup>, Kashif M. Munir, MD<sup>3,\*</sup>

<sup>1</sup> Division of Endocrinology & Diabetes, Albert Einstein College of Medicine, Montefiore Medical Center, Bronx, New York

<sup>2</sup> Department of Medicine, University of Maryland Medical Center, Midtown Campus, Baltimore, Maryland

<sup>3</sup> Division of Endocrinology, Diabetes, and Nutrition, University of Maryland School of Medicine, Baltimore, Maryland

## ARTICLE INFO

### Article history:

Received 2 March 2022

Received in revised form

25 April 2022

Accepted 9 May 2022

Available online 13 May 2022

### Key words:

voriconazole

periostitis

alkaline phosphatase

fluorosis

## ABSTRACT

**Background/Objective:** Voriconazole treatment has been associated with diffuse periostitis, especially in immunocompromised patients who have had transplants or are on immunosuppressants. Here, we present a case of diffuse periostitis induced by prophylactic low-dose voriconazole for pulmonary aspergillosis.

**Case Report:** A 66-year-old woman presented with 1 year of progressive, diffuse bone pain most prominent over the left shoulder and bilateral hips. She had a history of sarcoidosis requiring a single orthotopic lung transplant. Left phalangeal soft tissue swelling and painful nodules without clubbing were noted on examination. Prophylactic voriconazole 200 mg twice a day for pulmonary aspergillosis was prescribed for over 7 years. Elevated levels of alkaline phosphatase (469 units/L [reference range, 38–126]), bone-specific alkaline phosphatase (125 µg/L [0–20]), and parathyroid hormone (137 pg/mL [8–54]) and normal c-telopeptide level (842 pg/mL [34–1037]) were noted. Radiographs showed “multifocal periostitis” in both hip joints and bilateral proximal femurs, findings suggestive of voriconazole-induced periostitis deformans. Voriconazole was discontinued, and the patient improved symptomatically, despite persistent bone deformities on imaging.

**Discussion:** Diffuse bone pain can be due to various pathologies, including metabolic or inflammatory diseases and bone tumors. Voriconazole-induced periostitis is caused by skeletal fluorosis, which can result in diffuse bone pain. It is a clinical diagnosis that is supported with radiologic findings, including focal, nodular, dense, and irregular periosteal reactions. Biochemical evaluation may reveal elevated alkaline phosphatase levels, but it is usually related to normal voriconazole trough levels. Periostitis is a benign condition, and discontinuation of the drug usually leads to clinical improvement.

**Conclusion:** Voriconazole-induced periostitis should be considered as a diagnosis in elderly, immunosuppressed patients with diffuse bone pain on antifungal treatment. Early recognition of voriconazole-induced periostitis may result in both improved patient clinical outcomes and avoidance of unnecessary diagnostic testing.

© 2022 AAACE. Published by Elsevier Inc. This is an open access article under the CC BY-NC-ND license (<http://creativecommons.org/licenses/by-nc-nd/4.0/>).

## Introduction

Voriconazole has been linked to the development of diffuse periostitis especially in immunocompromised patients who have had transplants or are on immunosuppressants.<sup>1</sup> Voriconazole is an antifungal that is commonly used in the treatment of invasive

aspergillosis. It is also used as a prophylactic antifungal in patients with solid organ and hematopoietic stem cell transplant.<sup>2</sup> We present a case of periostitis caused by voriconazole with symptomatic improvement after discontinuation of the drug.

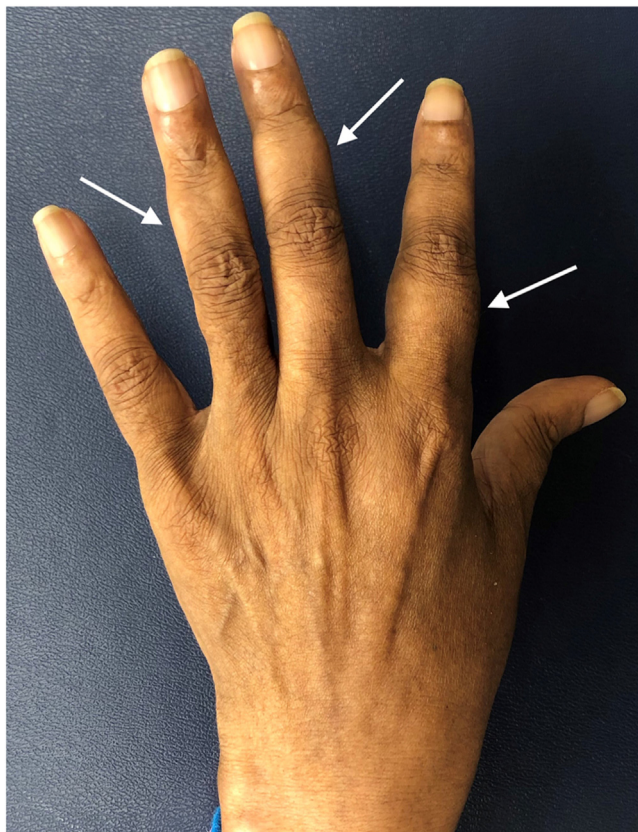
## Case Report

A 66-year-old woman presented with 1 year of progressive, diffuse bone pain, most prominently in the left shoulder and bilateral hips. She had a history of pulmonary sarcoidosis requiring a single orthotopic lung transplant. She had been on pulmonary aspergillosis prophylaxis for 7 years with voriconazole 200 mg

Abbreviation: ALP, alkaline phosphatase.

\* Address correspondence to Dr Kashif M. Munir, Division of Endocrinology, Diabetes, and Nutrition, University of Maryland School of Medicine, 827 Linden Avenue, 2nd Floor, Baltimore, MD 21201.

E-mail address: [kmunir@som.umaryland.edu](mailto:kmunir@som.umaryland.edu) (K.M. Munir).



**Fig. 1.** Left hand, soft tissue swelling, nodules of the middle and proximal phalanges (arrows).

twice a day. She presented to the emergency department after a mechanical fall. Owing to worsening pain, she required assistance with ambulating. The pain was attributed to avascular necrosis of the hips and arthritis (demonstrated on bilateral hip computed tomography) because of chronic immunosuppression therapy with prednisone 10 mg daily and cyclosporine. Her pain was treated with oxycodone, hydrocodone, and tramadol, along with intra-articular injections of triamcinolone and ropivacaine. On physical examination, decreased range of motion of the left shoulder was noted, along with bilateral hip pain with passive and active range of motion. In addition, left hand phalangeal soft tissue swelling and painful nodules were observed without clubbing (Fig. 1). Pain or swelling was not noted in the patient's toes. Laboratory evaluation revealed a creatinine level of 1.45 mg/dL (reference range, 0.52–1.04), calcium level of 7.8 mg/dL (8.6–10.2), albumin level of 2.5 g/dL (3.2–4.6), alkaline phosphatase (ALP) level of 469 units/L (38–126), bone-specific ALP level of 125  $\mu$ g/L (0–20), c-telopeptide level of 842 pg/mL (34–1037), parathyroid hormone level of 137 pg/mL (8–54), and 25-hydroxyvitamin D level of 25 ng/mL (20–80). Imaging on admission demonstrated “multifocal periostitis” in both hip joints and bilateral proximal femurs and avascular necrosis of bilateral hips. Hand radiographs showed numerous areas of well-defined calcification/ossification along the phalanges and metacarpals (Fig. 2 A). Subsequently, computed tomography of the abdomen/pelvis showed a new periosteal reaction surrounding the hips and femurs (Fig. 3). The patient had been on voriconazole for pulmonary aspergillosis prophylaxis for over 7 years. Laboratory and imaging findings were characteristic of voriconazole-induced periostitis. Voriconazole was discontinued, and despite the persistent bone deformities, symptomatic improvement was noted

### Highlights

- Voriconazole induced periostitis should be considered in the differential diagnosis in immunosuppressed patients with diffuse bone-pain on antifungal treatment to avoid misdiagnosis
- Periostitis is a benign condition and usually discontinuation of the drug leads to clinical improvement
- Early recognition of voriconazole induced periostitis results in a better outcome for patients and avoidance of unnecessary testing

### Clinical relevance

This case report demonstrates the presentation of bone-pain related to voriconazole used for prophylaxis in immunocompromised patients. The diagnostic approach and imaging findings in this case elaborate how to differentiate from other cause of bone pain such as hypertrophic osteoarthropathy.

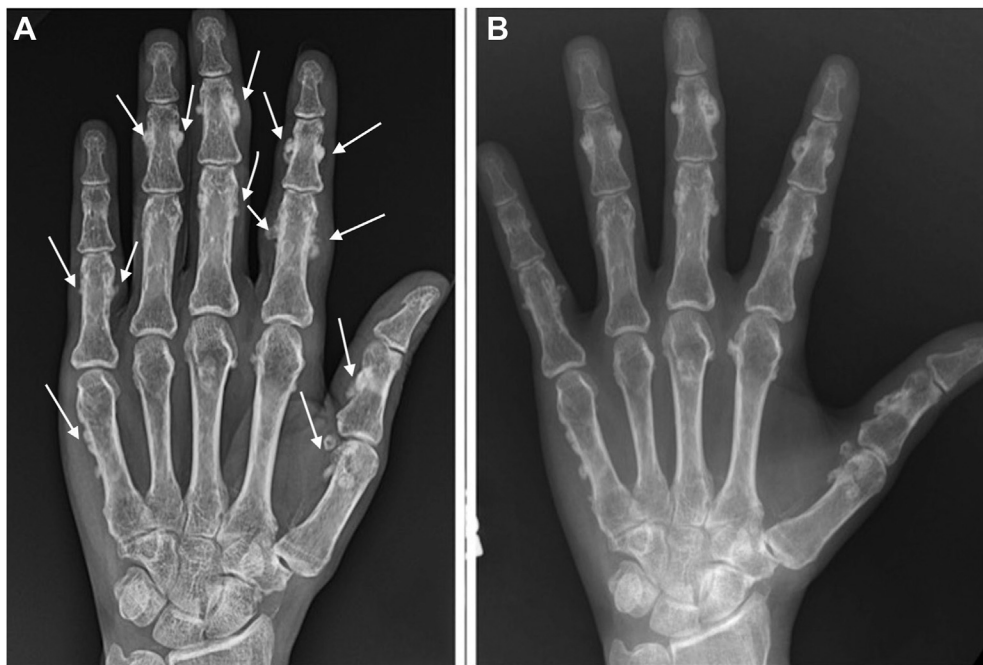over the next 6 months (decrease in joint pain), and the ALP level normalized to 74 units/L. No further fungal prophylaxis was given. Her x-ray changes progressed over 8 months' time (Fig. 2 B).

### Discussion

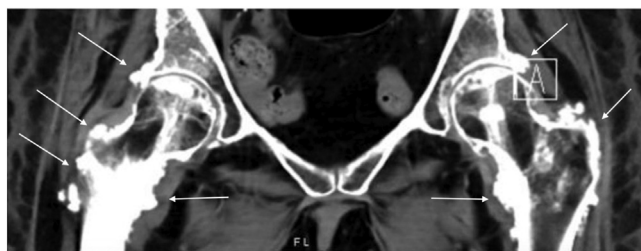
Voriconazole-induced periostitis is a clinical diagnosis supported with laboratory and radiologic findings. It presents with localized diffuse bone pain, mainly affecting the lower extremity joints, but may also affect the upper extremity joints. Recommended biochemical testing includes bone-specific ALP, which is consistently elevated. Despite higher doses being related to periostitis, voriconazole trough levels are typically within the normal range (1–5.5 mg/L).<sup>1</sup> While higher levels of plasma fluoride would strongly support the diagnosis, low or normal plasma fluoride levels do not exclude it.<sup>3</sup> The majority of cases are reported in immunocompromised patients.<sup>1</sup> Because a higher dose or longer duration of voriconazole is often needed in immunocompromised patients for fungal prophylaxis or treatment, exposure to the drug level is higher, thereby increasing the risk of periostitis as a complication. In addition, drug-drug interactions and genetic CYP2C19 polymorphism may result in faster metabolism of voriconazole, necessitating higher doses to maintain target trough levels. In this case, periostitis developed with the use of a relatively lower dose of voriconazole (200 mg twice a day) for prophylaxis, whereas it is more prevalent when using higher doses for invasive pulmonary aspergillosis in patients with lung transplant.

In the context of immunosuppression, voriconazole-induced periostitis must be differentiated from hypertrophic osteoarthropathy. Periostitis owing to voriconazole is asymmetrical and affects flat bones (eg, ribs, clavicle, scapula, acetabulum, and hands), whereas, hypertrophic osteoarthropathy is symmetrical with a predilection for a tubular portion of long bones with digital clubbing.<sup>4</sup> The periosteal reaction in voriconazole-induced periostitis is focal, nodular, dense, and irregular compared with the linear reaction in hypertrophic osteoarthropathy.<sup>5</sup>

It is postulated that voriconazole is a trifluorinated molecule and the elevation of fluoride blood content is responsible for the fluoride-induced osteoblastic proliferation and skeletal fluorosis.<sup>1</sup> The main clinical manifestation of skeletal fluorosis is diffuse



**Fig. 2.** A, The posterior radiograph of the left hand is notable for multifocal periosteal reaction involving the metacarpals and proximal and middle phalangeal shafts (arrows). The right hand (not shown) had similar radiographic appearances. B, Radiographic changes progressed over time.



**Fig. 3.** Abdominal/pelvic computed tomography/coronal view: diffuse periosteal reactions with some nodular areas surrounding the hips and both proximal femurs (white arrows).

bone pain. Both upper and lower extremity joints are commonly affected. The symptoms of periostitis improve upon discontinuation of voriconazole, which supports the diagnosis, as in this case. However, radiographic findings do not usually improve after stopping the medication. If clinically warranted, transition to nonfluorinated antifungals will reduce the risk of periostitis.<sup>1</sup>

Voriconazole-induced periostitis should be considered in the differential diagnosis in elderly immunosuppressed patients with

diffuse bone pain on antifungal treatment. Periostitis is a benign condition, and usually, discontinuation of the drug leads to clinical improvement. Early recognition of voriconazole-induced periostitis results in both improved patient clinical outcomes and avoidance of unnecessary diagnostic testing.

**Disclosure**

The authors have no multiplicity of interest to disclose.

**References**

1. Guarascio AJ, Bhanot N, Min Z. Voriconazole-associated periostitis: pathophysiology, risk factors, clinical manifestations, diagnosis, and management. *World J Transplant.* 2021;11(9):356–371.
2. Husain S, Camargo JF. Invasive aspergillosis in solid-organ transplant recipients: guidelines from the American Society of Transplantation Infectious Diseases Community of Practice. *Clin Transplant.* 2019;33(9):e13544.
3. Moon WJ, Scheller EL, Suneja A, et al. Plasma fluoride level as a predictor of voriconazole-induced periostitis in patients with skeletal pain. *Clin Infect Dis.* 2014;59(9):1237–1245.
4. Reber JD, McKenzie GA, Broski SM. Voriconazole-induced periostitis: beyond post-transplant patients. *Skeletal Radiol.* 2016;45(6):839–842.
5. Yap FY, Skalski MR, Patel DB, et al. Hypertrophic osteoarthropathy: clinical and imaging features. *Radiographics.* 2017;37(1):157–195.