

Isoniazid: A rare drug-induced cause for bilateral dentate nuclei hyperintensity

S Senthil Raj Kumar, S Shanmuga Jayanthan, G Rupesh

Senior Consultant Radiologist and HOD, Consultant Radiologist, Consultant Radiologist, Department of Radiology and Imaging Sciences, Meenakshi Hospital, Tanjore, Tamil Nadu, India

Correspondence: Dr. S Senthil Raj Kumar, Department of Radiology and Imaging Sciences, Meenakshi Hospital, 244/2 Trichy Main Road, Near New Bus Stand, Nilagiri Therku Thottam, Tanjore - 613 005, Tamil Nadu, India. E-mail: senthil_raj कुमार@yahoo.com

Abstract

Dentate nucleus, the largest deep nucleus of the cerebellum, is affected by numerous conditions, including leukodystrophies, toxins, drugs, infections, and various metabolic and inflammatory conditions. This case report is a drug-induced cerebellitis, caused by isoniazid (INH), characterized in magnetic resonance imaging (MRI) as bilateral dentate nuclei hyperintensity. Isoniazid, an antituberculosis therapy (ATT) drug, is both neurotoxic and hepatotoxic but cerebellitis is a rare complication. INH-induced cerebellitis is characterized in MRI by bilateral and symmetrical T2/fluid-attenuated inversion recovery (FLAIR) hyperintensity in dentate nuclei. Though metronidazole is the most common drug associated with such MRI signal changes in the dentate nucleus, the uncommon association with INH has been described in literature especially in patients with renal function impairment. MRI findings together with clinical signs of cerebellar involvement, in a patient with abnormal renal function tests and in whom the ATT regimen was recently initiated, favors the diagnosis of INH toxicity. INH withdrawal and pyridoxine supplementation can reverse this condition.

Key words: Dentate nucleus hyperintensity; drug-induced cerebellitis; isoniazid neurotoxicity

Introduction

The dentate nucleus is the largest deep cerebellar nuclei and is affected by many benign and potentially treatable conditions with favorable prognosis.^[1] Metronidazole is the most common cause for drug-induced cerebellitis, affecting the bilateral dentate nuclei.^[1] In developing countries where tuberculosis (TB) is prevalent, isoniazid (INH) an antituberculosis drug, induced cerebellitis, though rare,^[2] is a possible condition to be aware of. Though INH toxicity is more common in children, patients with chronic kidney disease (CKD) are more prone to its toxicity due to reduced renal clearance.^[3] The classical history of initiation of four-drug regimen (that includes INH) for tuberculosis and onset of cerebellar symptoms in a CKD patient, should promptly raise the suspicion of INH-induced cerebellitis.^[3-5]

The findings in magnetic resonance imaging (MRI) include bilateral and symmetrical T2 and fluid-attenuated inversion recovery (FLAIR) hyperintensity of dentate nuclei and classically being an isolated finding.^[2-5] There are only a few cases documented in literature.^[2-4] Often a diagnosis of exclusion, withdrawal of INH, and pyridoxine supplementation can potentially reverse the clinical and imaging findings, thus confirming the diagnosis.^[5]

Case History and Imaging Findings

A case of 55-year-old male patient was diagnosed with pulmonary tuberculosis and was initiated with four-drug antituberculosis regimen that includes, INH, rifampin (R),

This is an open access journal, and articles are distributed under the terms of the Creative Commons Attribution-NonCommercial-ShareAlike 4.0 License, which allows others to remix, tweak, and build upon the work non-commercially, as long as appropriate credit is given and the new creations are licensed under the identical terms.

For reprints contact: WKHLRPMedknow_reprints@wolterskluwer.com

Cite this article as: Senthil Raj Kumar S, Shanmuga Jayanthan S, Rupesh G. Isoniazid: A rare drug-induced cause for bilateral dentate nuclei hyperintensity. *Indian J Radiol Imaging* 2020;30:218-21.

Received: 15-Oct-2019

Revised: 16-Jan-2020

Accepted: 08-Apr-2020

Published: 13-Jul-2020

Access this article online

Quick Response Code:



Website:
www.ijri.org

DOI:
10.4103/ijri.IJRI_421_19

pyrazinamide (Z), and ethambutol (E). After two weeks, the patient presented with acute onset of dysarthria and gait disturbance. He was not a known alcoholic or hypertensive and the blood pressure recorded was normal at the time of presentation. Clinical investigations showed elevated serum creatinine (2.0 mg/dl) and there was no electrolyte imbalance. His liver function tests were normal. Ultrasound (USG) was advised to assess the renal status and it showed features of bilateral medical renal disease in the form of increased renal cortical echoes with small-sized kidneys.

Computed tomography (CT) of brain was suggested to rule out intracranial pathology. CT brain, however, showed no evidence of hemorrhage or infarcts [Figure 1]. Hence, MRI was further planned and it showed areas of bilateral and symmetrical T2 and FLAIR hyperintensities in dentate nuclei of the cerebellum [Figures 2 and 3]. The corresponding areas also showed hyperintensity in diffusion weighted imaging (DWI), without any signal changes in apparent diffusion coefficient (ADC) [Figures 4 and 5]. Metronidazole toxicity was suspected but there was no drug history of that kind, on retrospective clinical history. Cerebrospinal fluid (CSF) analysis did not show any signs of infection. Through the process of diagnosis of exclusion, we have made a possible diagnosis of INH-induced cerebellitis, which is also described in literature and case reports, in the background of renal function impairment.

Accordingly, the INH was withdrawn from the regimen and pyridoxine supplementation was started. The patient started to show dramatic improvement clinically within a week and with complete resolution of cerebellar symptoms after two weeks. Follow-up MRI was done after 2 weeks, which showed complete resolution of signal changes in cerebellar dentate nuclei, at T2/FLAIR images [Figures 6 and 7]. No abnormal signals were seen in DWI/ADC [Figures 8 and 9], thus confirming the diagnosis of INH-induced cerebellitis.

Discussion

The four paired deep nuclei of the cerebellum are very important in the formation of cerebro-cerebellar circuit that

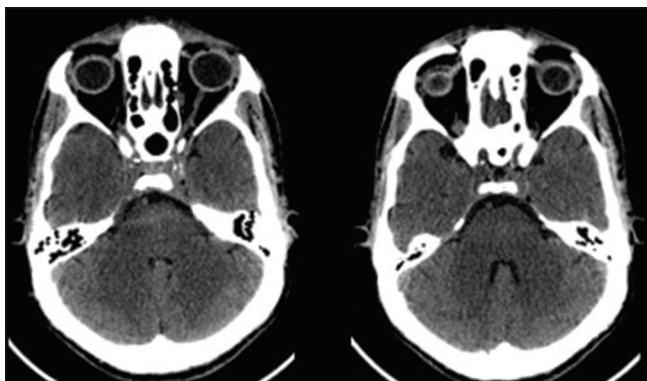


Figure 1: Axial sections of CT show no infarct or haemorrhage in cerebellar hemispheres

relay information from the cerebellum to supratentorial cortical and subcortical targets.^[1] The dentate nuclei are the most lateral and largest among them and they are located adjacent to vermis and roof of the fourth ventricle, on either side.^[1] They are involved in the planning and execution of voluntary movements, higher-level cognition, and sensory processing.^[1]

Drug-induced cerebellitis involving dentate nuclei is classically seen with metronidazole toxicity.^[1,2] Rare association with INH, an antituberculous drug, has been documented in patients with renal function impairment.^[3-5] INH is both hepatotoxic and neurotoxic.^[4] The later often manifest in the form of peripheral neuropathy,^[2,4] due to its interference with pyridoxine metabolism resulting in vitamin deficiency.^[3] Central nervous system (CNS) involvement by its metabolite, known as isonicotinylhydrazide, can result in encephalopathy.^[3] Cerebellum involvement is rare, but do occur, involving the bilateral dentate nuclei with resultant edema due to reduced gamma-aminobutyric acid (GABA) levels and down regulation of N-methyl-D-aspartate (NMDA) receptors.^[2] INH is primarily excreted through kidneys and hence reduced clearance in CKD patients is responsible for neurotoxicity.^[5] Hence, patients with CKD are prone to INH-induced cerebellitis.^[2-5]

The clinical presentations of cerebellitis include unsteady gait, dysarthria, impaired finger-nose test, and past pointing.^[4] Association of drug initiation and the origin of such symptoms in a patient with CKD should raise the suspicion of INH-induced cerebellitis.^[3,5]

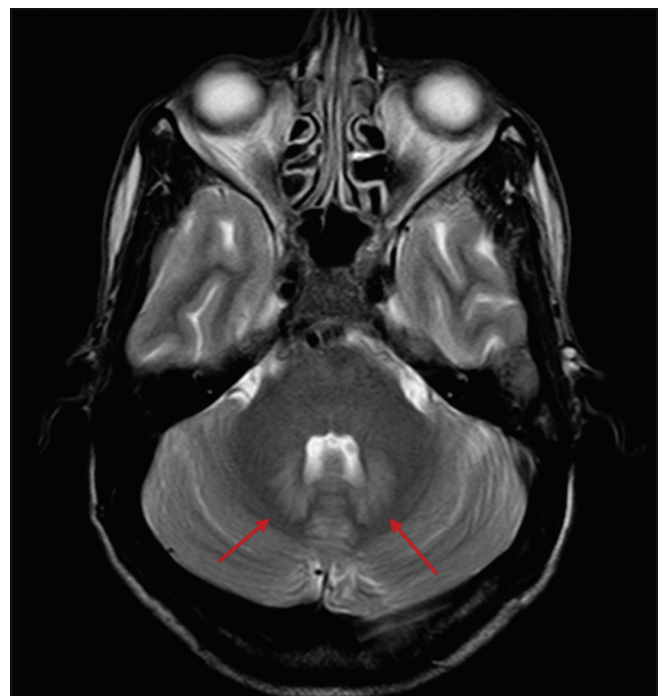

Figure 2: Axial T2 W image shows bilateral symmetrical hyperintense signal in dentate nuclei of cerebellum

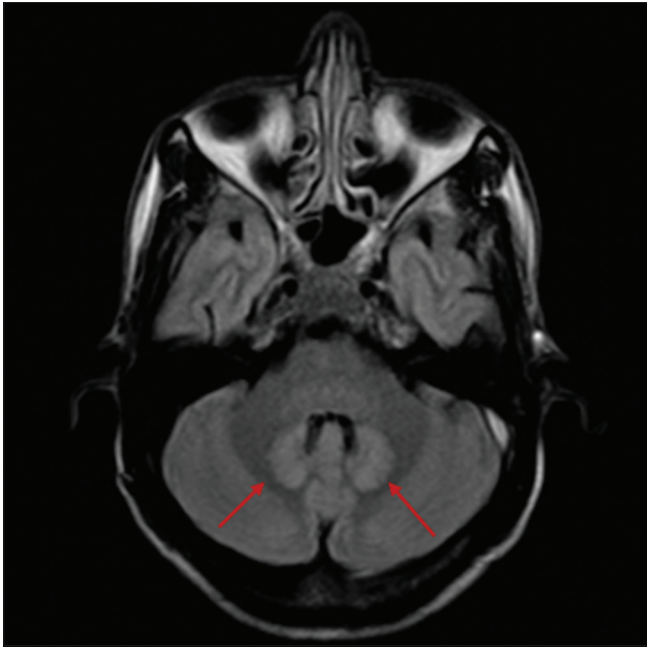


Figure 3: Axial FLAIR image shows bilateral symmetrical hyperintense signal in dentate nuclei of cerebellum

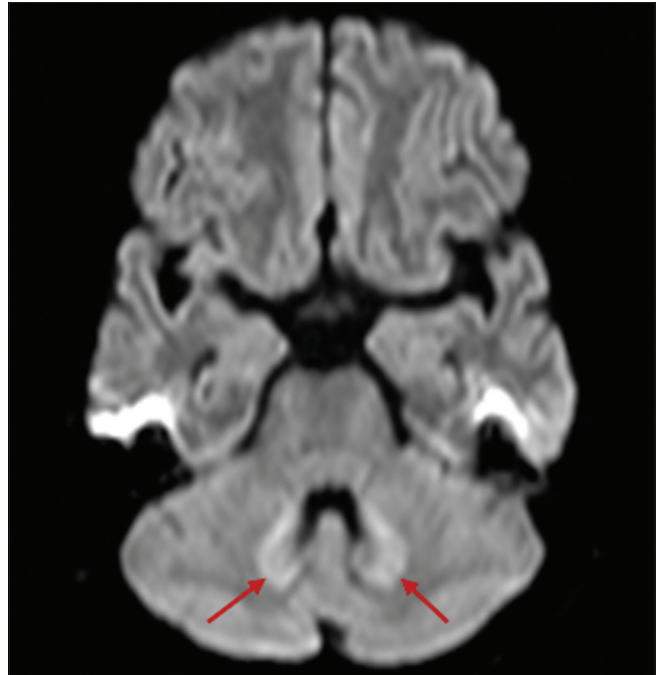


Figure 4: Axial DWI shows the bilateral symmetrical hyperintense signal in dentate nuclei of cerebellum

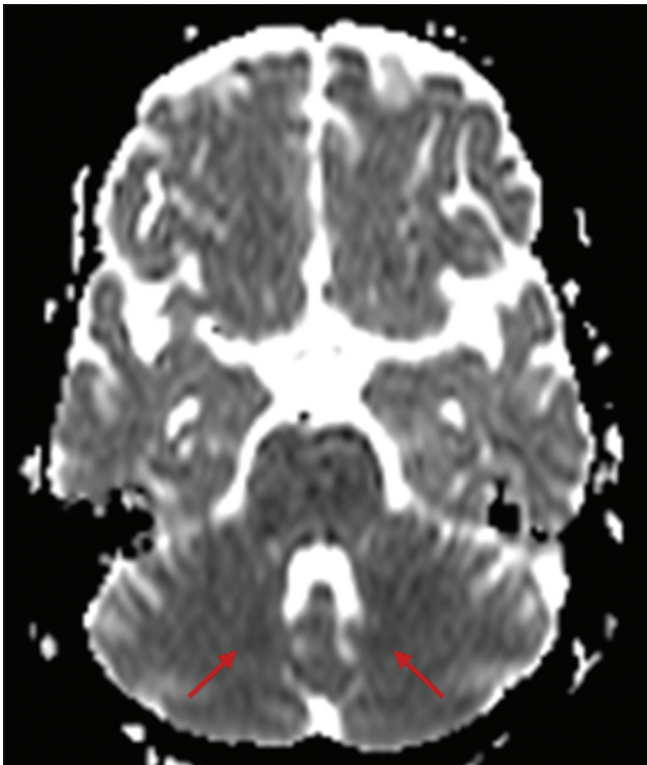


Figure 5: Axial ADC image shows no abnormal signals in the dentate nuclei of cerebellum

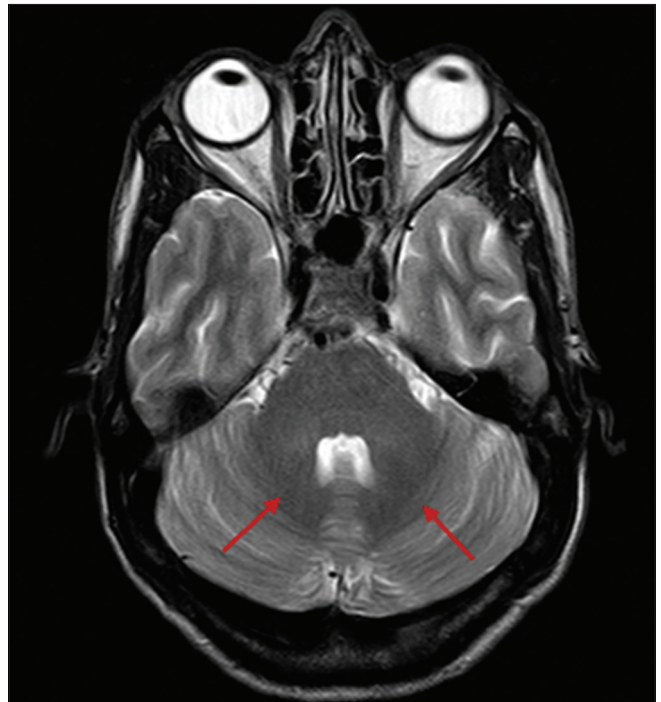

Figure 6: Axial T2 W image shows resolved hyperintense signal in both dentate nuclei of cerebellum

MRI findings include classical bilateral and symmetrical T2/FLAIR hyperintensity involving the dentate nuclei, suggestive of edema.^[2-5] Differential diagnosis includes methyl bromide toxicity, enteroviral infections, maple syrup urine disease, and metronidazole toxicity.^[2,5] Atypical Wernicke's encephalopathy can be considered in the differential diagnosis if the

involvement of the dentate nuclei is not an isolated finding.^[5] In our case, meticulous medical history and clinical investigations excluded all other possible differential diagnoses.

Conclusions

INH-induced cerebellitis should be considered in the differential diagnosis of bilateral dentate nuclei hyperintensity

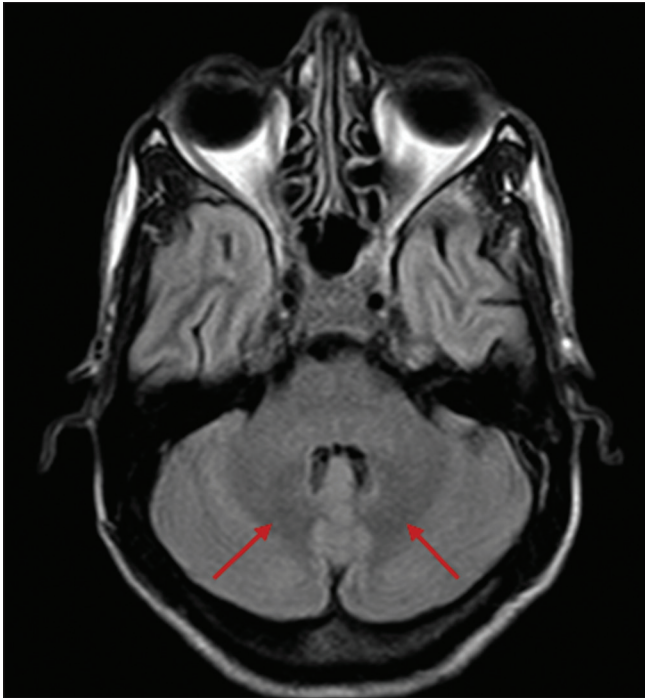


Figure 7: Axial FLAIR image shows resolved hyperintense signal in both dentate nuclei of cerebellum

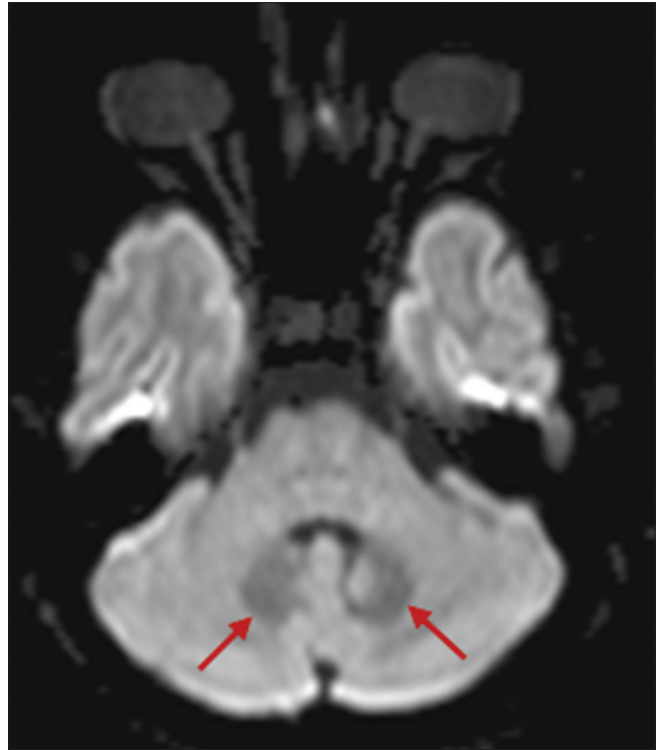

Figure 8: Axial DWI shows no restriction in both dentate nuclei of cerebellum

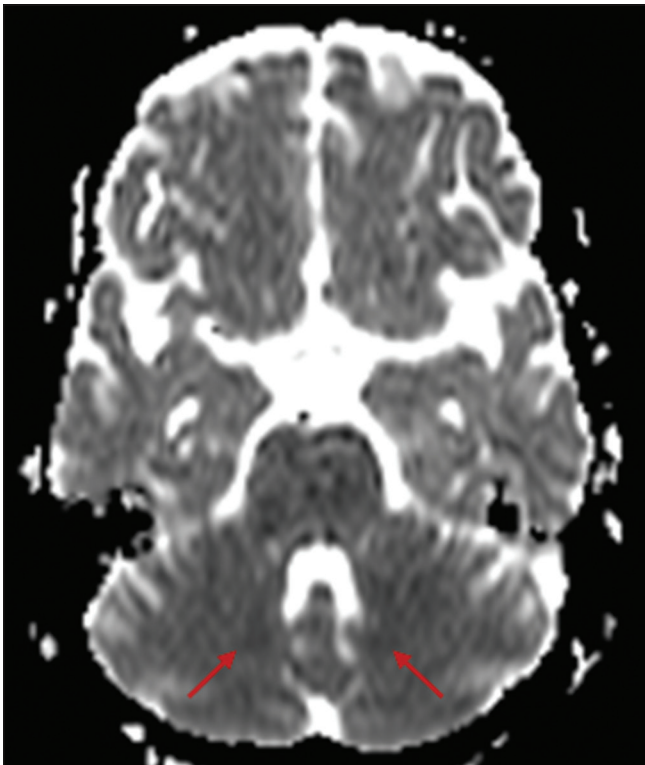


Figure 9: Axial ADC image shows no abnormal signals in the dentate nuclei of cerebellum

especially in patients with renal function impairment. Early diagnosis and treatment in the form of INH withdrawal and pyridoxine supplementation can potentially reverse the edema and cause dramatic improvement in the patient's symptoms.

Declaration of patient consent

The authors certify that they have obtained all appropriate patient consent forms. In the form the patient(s) has/have given his/her/their consent for his/her/their images and other clinical information to be reported in the journal. The patients understand that their names and initials will not be published and due efforts will be made to conceal their identity, but anonymity cannot be guaranteed.

Financial support and sponsorship

Nil.

Conflicts of interest

There are no conflicts of interest.

References

1. Bond KM, Brinjikji W, Eckel LJ, Kallmes DF, McDonald RJ, Carr CM. Dentate update: Imaging features of entities that affect the dentate nucleus. *AJNR Am J Neuroradiol* 2017;38:1467-74.
2. Deepesh A, Pendharkar HS. Isoniazid toxicity presenting as bilateral dentate hyperintensities. *Neurol India* 2017;65:1193.
3. Binwal VK, Syed T, Ahir D. Isoniazid-Induced cerebellitis and psychosis in chronic kidney disease patient with tubercular pleural effusion. *J Integr Nephrol Androl* 2016;3:60-1.
4. Pathania D, Phanish MK, Vishal J, Kher V. Ataxia in a chronic kidney disease patient on anti-tubercular therapy. *Indian J Nephrol* 2016;26:52-4.
5. Peter P, John M. Isoniazid-induced cerebellitis: A disguised presentation. *Singapore Med J* 2014;55:e17-9.