Internal Medicine
The Japanese Society of Internal Medicine

doi: 10.2169/internalmedicine.3892-19
Intern Med 59: 1541-1547, 2020
http://internmed.jp

【 CASE REPORT 】

An Autopsy Case of Idiopathic Pleuroparenchymal Fibroelastosis with Left Vocal Cord Paralysis and a Rapid Deterioration without an Acute Exacerbation

Chizuru Futatsuya[1], Hiroshi Minato[1], Yurie Okayama[1], Kazuyoshi Katayanagi[1], Hiroshi Kurumaya[1], Mizuki Yuasa[2] and Koichi Nishi[2]

Abstract:
Idiopathic pleuroparenchymal fibroelastosis (IPPFE) is a generally slow-progressing rare disorder of unknown etiology. The direct cause of death in cases of IPPFE is rarely investigated. We experienced an autopsy case of a Japanese man with IPPFE and found aspiration pneumonia to be the major trigger of death. The individual had left vocal cord paralysis at admission, which may have contributed to aspiration pneumonia, and which probably was affected by the fibrous adhesion of the left apex of the chest wall resulting from IPPFE. The prevention of aspiration pneumonia is important for maintaining the respiratory function, especially in IPPFE patients with repeated pneumothorax.

Key words: idiopathic pleuroparenchymal fibroelastosis, idiopathic pulmonary upper-lobe fibrosis, interstitial pneumonia, aspiration pneumonia, autopsy, cause of death

(Intern Med 59: 1541-1547, 2020)
(DOI: 10.2169/internalmedicine.3892-19)

Introduction

Idiopathic pleuroparenchymal fibroelastosis (IPPFE) is a rare disorder that has been included in the official American Thoracic Society/European Respiratory Society (ATS/ERS 2013) classification (1) as a group of rare idiopathic interstitial pneumonias. The symptoms of IPPFE largely overlap with those of idiopathic pulmonary upper lobe fibrosis initially reported by Amitani et al. (2), which is also known as "Amitani disease" in Japan. Patients with these diseases are characterized by 1) a slender stature with flat rib cage; 2) progressive bilateral fibrosis causing volume loss, mainly in the upper lung lobes; 3) predominant fibrosis of the subpleural parenchyma; 4) multiple bullae without honeycombing; 5) recurrent pneumothorax; 6) absence of extrathoracic lesions; 7) absence of identified acid-fast bacteria; 8) possible complication with aspergillus infection; and 9) slow progression, over approximately 10-20 years. Although the disease appears to progress gradually, the prognosis of IPPFE has varied widely among reported case studies (2), with some cases showing rapid deterioration (2-5); however, few patients die within a year of onset of the disease (4-6). In cases of IPPFE, progression of the disease itself is usually considered the cause of death, but the precise cause has been rarely discussed.

We herein report the autopsy of a patient with IPPFE who showed rapid disease progression and died within a year of the onset of respiratory symptoms. With this case report, we aimed to identify the cause of death and thereby aid in the improvement of therapeutic choices for this disease in the future.

Case Report

A Japanese man in his 70s presented to the emergency room with a fever and respiratory distress. He had a history of bilateral pneumothorax for the past two years and four months, since he had undergone thoracoscopic partial resection of the right lower lobe and left tube thoracostomy. He

[1]Department of Diagnostic Pathology, Ishikawa Prefectural Central Hospital, Japan and [2]Department of Respiratory Medicine, Ishikawa Prefectural Central Hospital, Japan
Received: September 3, 2019; Accepted: February 4, 2020; Advance Publication by J-STAGE: March 19, 2020
Correspondence to Dr. Hiroshi Minato, hminato@ipch.jp

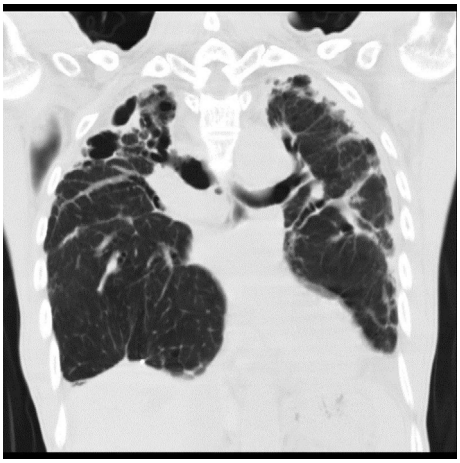

Figure 1. Chest CT scan showing emphysematous changes or traction bronchiectasis and subpleural fibrosis predominant in the upper lobes (five months before death).

had developed exertional dyspnea in the 10 months prior to disease presentation and his condition had gradually deteriorated. Five months earlier, he had undergone computed tomography (CT) that showed subpleural scarring, predominantly in the bilateral upper lobes, suggesting PPFE (Fig. 1). He had received expectorants three months earlier and had planned to begin home oxygen therapy (HOT) one month before admission.

The patient had never received radiation therapy, chemotherapy, or transplantation. He worked as a bank clerk and had no history of occupational exposure, hypersensitivity pneumonia, or family history of pulmonary fibrosis. He was an ex-smoker (50 cigarettes/day from 20 to 35 years old) and did not own birds. His serum Krebs von den Lungen (KL)-6 levels were within normal limits, and his surfactant protein-D (SP-D) was continually elevated (Fig. 2). Serum brain natriuretic peptide (BNP) had markedly increased from 125.4 to 642.1 pg/mL over the past 6 months (Fig. 2). The results of a pulmonary function test performed six months earlier indicated severe restrictive impairment and a reduction in the pulmonary diffusing capacity (Fig. 3). Elevation of residual volume (RV)/total lung capacity (TLC), one of the characteristic features of PPFE, was also seen.

Another pulmonary function test had been scheduled about one month prior, but it had been cancelled due to respiratory distress. On the first 6-minute walk test done on the same day as the pulmonary function test, he was able to walk 300 m, but at the second time one month prior, the test had been discontinued due to his hypoxic condition. Echocardiography performed 6 months earlier revealed a heart rate of 100/min, moderate tricuspid regurgitation, mild mitral regurgitation, and an increase in the right ventricular systolic pressure to 41 mmHg (normal <30 mmHg). His peak transmitral velocity/peak mitral annular velocity (E/e') ratio was 8.3, and his left ventricular ejection fraction (LVEF) was 57%. An electrocardiogram showed frequent premature atrial contraction, incomplete right bundle brunch block, right ventricular hypertrophy, and right axis deviation. The patient showed severe exertional dyspnea and coldness of limbs.

On a physical examination, inspiratory crackles and later pitting edema were observed. His body mass index was 14.2 kg/m^2, and his weight was 42.5 kg at admission and 54 kg two years before. Digital clubbing was absent. Although autoantibodies were not examined, he had no symptoms of autoimmune disease, such as rheumatoid arthritis, ulcerative colitis, psoriasis, and ankylosing spondylitis. His serum IgG level was normal. He showed an increased sputum production, and his serum C-reactive protein (CRP) level was high at 7.3 mg/dL (normal <1.0 mg/dL).

Chest CT revealed a *de novo* infiltrative shadow in the lower lobes, especially in the right lobe (Fig. 2). Sputum culture did not isolate significant organisms, and Gram staining of the sputum revealed polymicrobial pattern. An otolaryngological evaluation was performed due to his presentation with hoarseness at admission, revealing left vocal cord paralysis due to idiopathic cause. His PaO_2 at admission was decreased to 58.7 mmHg even under administration of 1 L of oxygen, although his respiratory symptoms were mildly improved by sputum sucking. With a diagnosis of aspiration pneumonia and cardiac failure, he received antibiotics, diuretics, oxygen, and bronchodilators under fasting. Oral care, breathing training by rehabilitation staff, and postural drainage were also provided.

Because of the possibility of persistent aspiration due to left laryngeal palsy, we proposed gastrostomy or nasal intubation, but the patient rejected these treatments. Although the serum CRP level decreased, the accumulation of CO_2 in the blood gas and acidosis gradually progressed (Fig. 2), probably due to respiratory muscle fatigue. Despite respiratory failure, the patient declined to use a ventilator. His respiratory function gradually deteriorated, and he ultimately died nine days later.

At an autopsy, the lungs were heavy with bilateral volume loss in the upper lobes. Bilateral pleurae showed fibrous thickening, mainly in the apex, with the left apex firmly adhered to the chest wall. The cut surface of the lungs showed remarkable subpleural fibrosis and traction bronchiectasis in the bilateral upper lobes and consolidation areas, mainly in the right lower lobe. Microscopically, subpleural fibrosis consisted primarily of elastic fibrosis with intraalveolar fibrosis (Fig. 4-6). The lower lobes also showed relatively mild subpleural fibrosis (Fig. 4). Focal collagenous fibrosis and micro-ossification were seen in the subpleural areas near the pleural fibrosis. There were very few fibroblastic foci localized only in the upper lobe fibrosis; however, there was no interstitial fibrosis with temporal and geographic variegation or honeycomb change suggesting usual interstitial pneumonia (UIP). Focal saprophytic *Aspergillus* infection was seen in the ectatic bronchioles of the right upper lobe. No granulomas were observed. Many D2-40-positive lymphatic vessels were seen within the elastofibrotic lesions (approximate lymph vessel density was 5.5%) (7) (Fig. 6B). The bi-

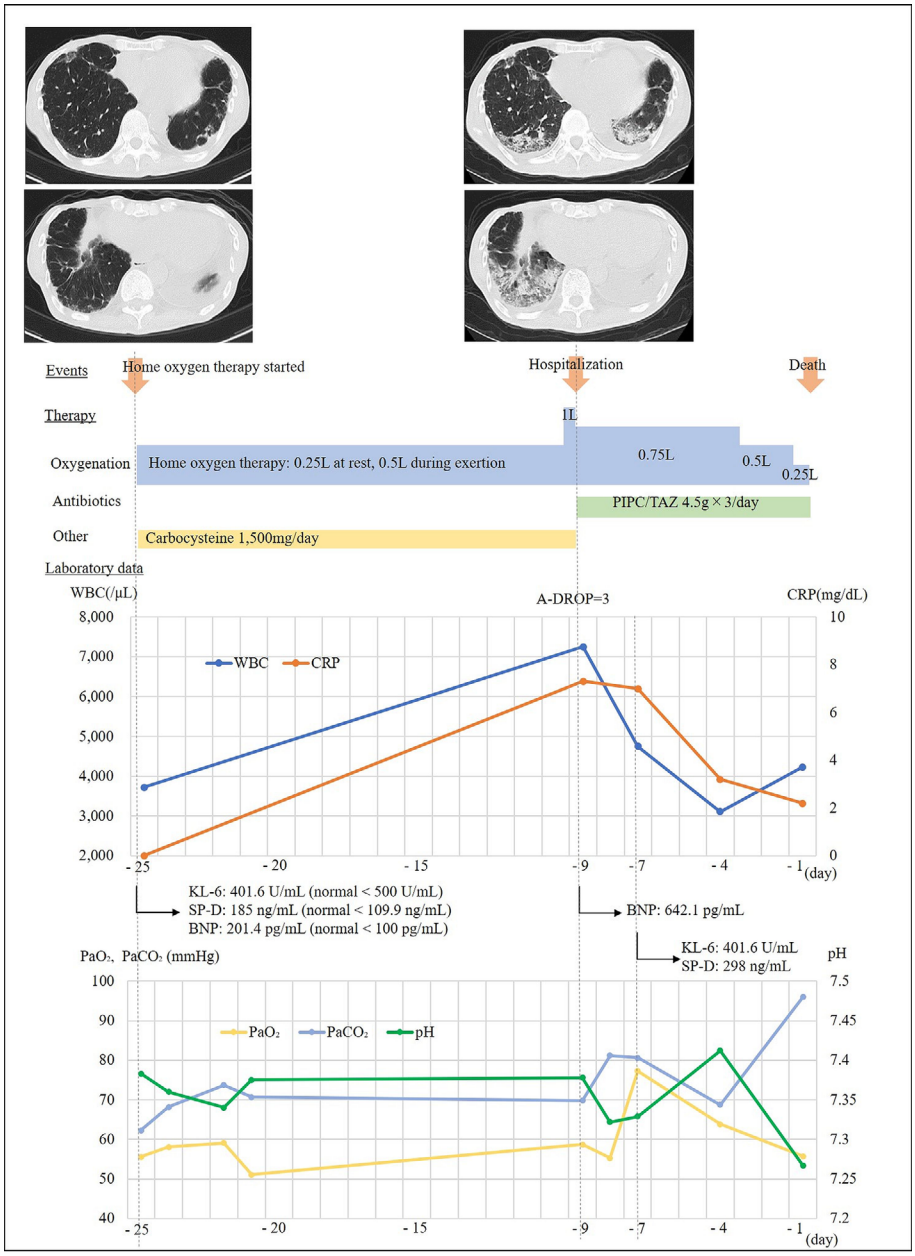

Figure 2. Summary of the clinical course and treatment. PIPC/TAZ: piperacillin/tazobactam, BNP: serum brain natriuretic peptide

lateral lower lobes were congested and edematous. The right lower lobe contained keratinizing debris with foreign body-type giant cells and the accumulation of neutrophils. Although food residue could not be confirmed, these pathological changes were pathognomonic for aspiration pneumonia (Fig. 7). The organizing pneumonia was localized in the right lower lobe. There were no hyaline membranes, diffuse interstitial edema and organization, diffuse pneumocyte hyperplasia with squamous metaplasia, arterial thrombosis, or honeycombing suggesting acute exacerbation of interstitial pneumonia (6).

Based on these clinicopathological findings, IPPFE was diagnosed. Aspiration pneumonia with a background of IPPFE was considered the major trigger of death. We concluded that he had ultimately died from respiratory and heart failure with pneumonia and congestive edema. Fibrosis was identified in the left apical pleura and around the peripheral nerves. The nerves showed focal myelin digestion chambers indicative of axonal degeneration (Fig. 8); however, the possibility of artificial changes created by postmortem specimen preparation cannot be denied, so we cannot safely claim this to be a significant finding.

Discussion

Thus far, cases of IPPFE have been increasingly reported in the English and Japanese literature (2). Regarding the clinicopathological characteristics of IPPFE described by Amitani et al., the patient had the following: 1) a slender stature (height 173 cm, weight 42.5 kg, BMI 14.2) and a

	Measured values	Predicted values	%Predicted
VC	0.96 L	3.39 L	28.3%
ERV	0.22 L	1.44 L	15.3%
FVC	0.96 L	3.39 L	28.3%
FEV1	0.96 L	2.59 L	37.1%
FEV1%	100.0%	64.6%	154.9%
RV	2.17 L	1.92 L	113.0%
TLC	3.13 L	5.55L	56.4%
RV/TLC	69.3%	40.6%	170.9%
DLco	1.60 mL/min/mmHg	14.12mL/min/mmHg	11.3%
DLco/VA	0.71mL/min/mmHg/L	4.31mL/min/mmHg/L	16.5%

VC, vital capacity; ERV, expiratory reserve volume; FVC, forced vital capacity; FEV, forced expiratory volume; RV, residual volume; TLC, total lung capacity; DLco, diffusing capacity for carbon monoxide; VA, alveolar volume

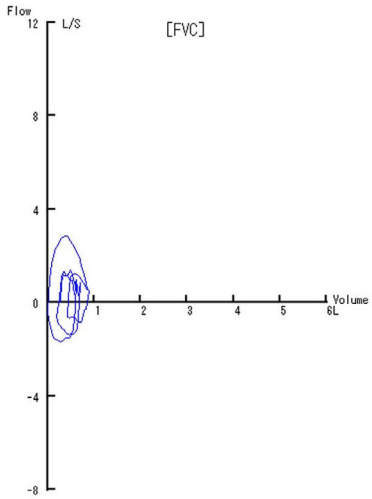

Figure 3. Results of pulmonary function tests and a flow volume curve six months prior to the autopsy, indicating severe restrictive impairment and a reduction in the pulmonary diffusing capacity. Elevation of RV/TLC, which is characteristic features of PPFE, is also seen.

Figure 4. Whole slide images of the bilateral lungs. Subpleural fibroses and bronchiectasis are severe in the upper lobes and mild in the lower lobes. The right lower lobe also contains areas of aspiration and organizing pneumonia.

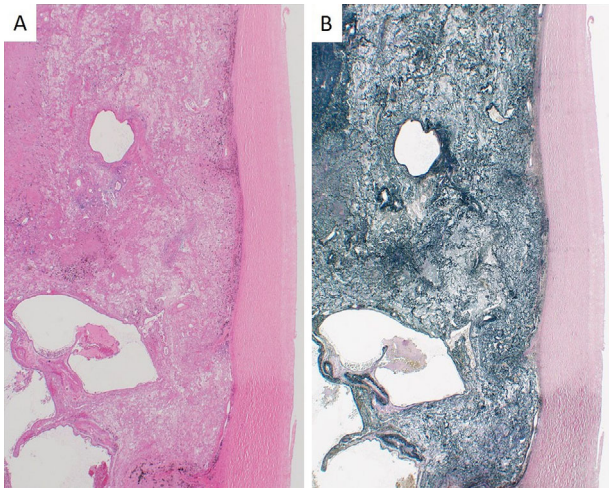

Figure 5. (A) Low-power view of the upper lobe showing fibrous pleural thickening and remarkable subpleural fibroelastosis (original magnification, ×20). (B) Subpleural fibrosis is rich in elastic fibers (Elastica van Gieson stain) (original magnification, ×20).

flat rib cage; 2) progressive bilateral fibrosis causing volume loss, mainly in the upper lobes; 3) predominant fibrosis of the subpleural parenchyma; 4) multiple bullae without honeycombing; 5) a history of recurrent pneumothorax (bilateral pneumothorax two years before his death and six months before his death); 6) neither extrathoracic lesions nor 7) identified acid fast bacteria (T-spot test was negative and no lesion suggestive of mycobacterial infection was observed at the autopsy); and 8) a focal saprophytic aspergillus infection in the autopsy specimen. However, we cannot say the case showed a slow progression, which is in contrast to the traditional characteristics.

Histologically, PPFE is characterized by 1) intense fibrosis of the visceral pleura; 2) prominent, homogenous, subpleural fibroelastosis; 3) sparing of the parenchyma distant from the pleura; 4) mild, patchy lymphoplasmacytic infiltrates; and 5) small numbers of fibroblastic foci (8). Kinoshita et al. (7) reported that the number of lymphatic vessels in PPFE was significantly higher than in the normal lungs, apical cap, and idiopathic pulmonary fibrosis. They also reported that an increased lymphatic vessel density was correlated with the characteristic physiology of PPFE, such as a flattened chest cage and high RV/TLC ratio. In that report, the average lymphatic vessel density in the upper lobes of idiopathic pulmonary fibrosis patients was 0.8%, and that of PPFE patients was 2.97%. Many lymphatic vessels were

also seen in the present case, as shown in Fig. 6B, and the approximate vessel density was 5.5%. These results support the diagnosis of PPFE.

The case presented here is both clinically and pathologically typical of PPFE except for its rapid progression within a year. Fibroblastic foci were localized and mild. We diagnosed IPPFE because of the absence of causative factors, such as a history of chemoradiation therapy, dust exposure, active infection, autoimmune diseases, hypersensitive pneumonitis, and other interstitial pneumonias (2). PPFE was initially considered a disease with a long history, as the median survival of patients has been reported to be 7.3-11 years (2, 9, 10). However, some patients show a rapid progression, and the clinical course seems to vary depending on the case (2-5, 11). Ishii et al. suggested that PPFE might be caused by underlying conditions or comorbidities or be due to coexisting IP (9). Watanabe suggested that there might be a long silent period in the clinical course of PPFE, during which patients may be asymptomatic, followed by acceleration of the clinical course following the onset of symptoms (2).

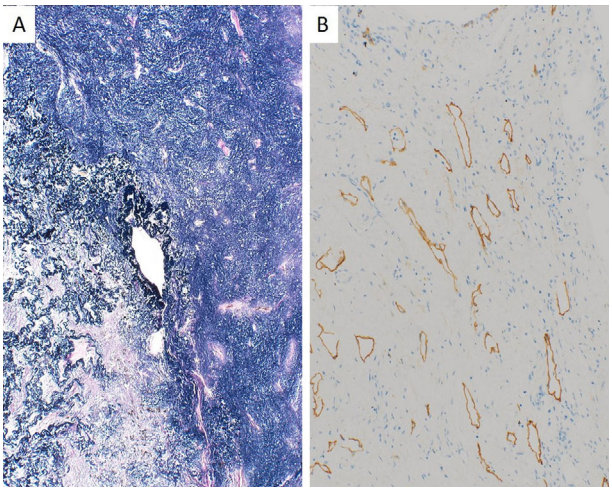

Figure 6. (A) Higher-power view of the subpleural fibrosis showing condensed elastic fibers and intraalveolar fibrosis (Elastica van Gieson stain) (original magnification, ×100). (B) Immunostaining of D2-40 (podoplanin) showing many lymphatics in the fibrosis (original magnification, ×200).

While approximately 40% of patients with PPFE have died from the disease, little attention has been given to the direct cause of death. Although respiratory failure due to chronic deterioration of the disease is conceivable as a general cause of death in PPFE, cases showing acute exacerbation or death due to pneumonia after immunosuppressive therapy have also been reported (4, 5). We found no published report that has reviewed and discussed the cause of death in PPFE. A high serum KL-6 level (>600 U/mL) was listed as an adverse factor in PPFE by a multivariate analysis (9). However, the serum KL-6 level was within the normal range, and no IP pattern other than PPFE was observed in our case. We believe that the poor respiratory status due to IPPFE in the present patient was closely associated with

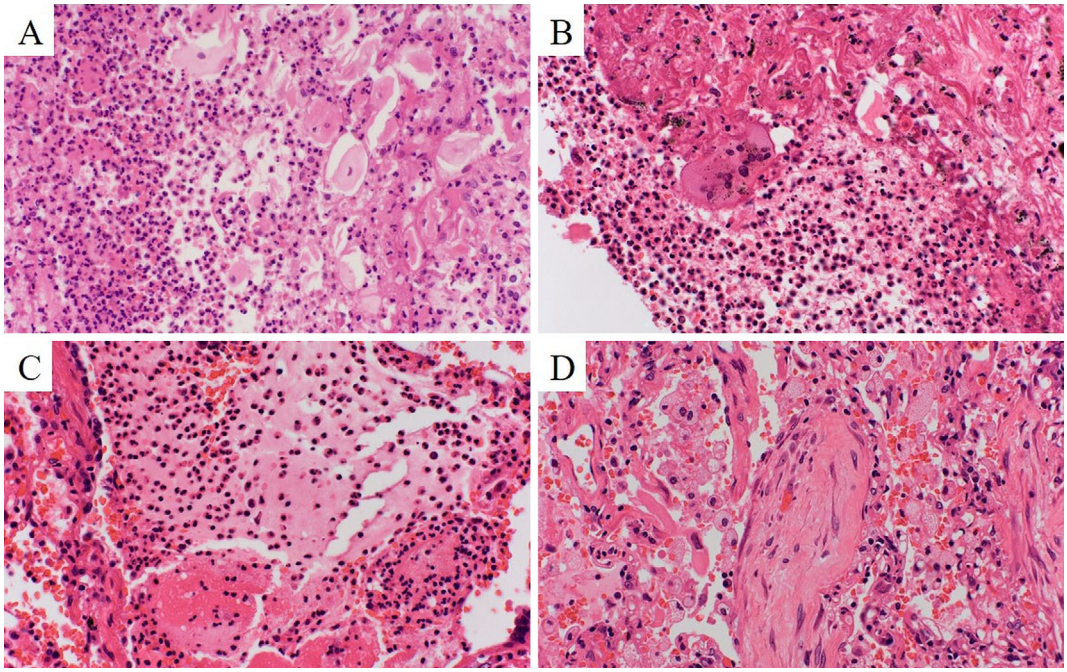

Figure 7. (A) Focal aspiration pneumonia with keratinocytes seen in the right lower lobe (original magnification, ×400). (B) Foreign body-type multinucleated giant cells were seen as well (original magnification, ×400). (C) Pulmonary edema and congestion with neutrophilic infiltration was seen around the aspiration pneumonia (original magnification, ×400). (D) Foamy macrophages, a few neutrophils, and polypoid organization were noted adjacent to the aspiration pneumonia (original magnification, ×400).

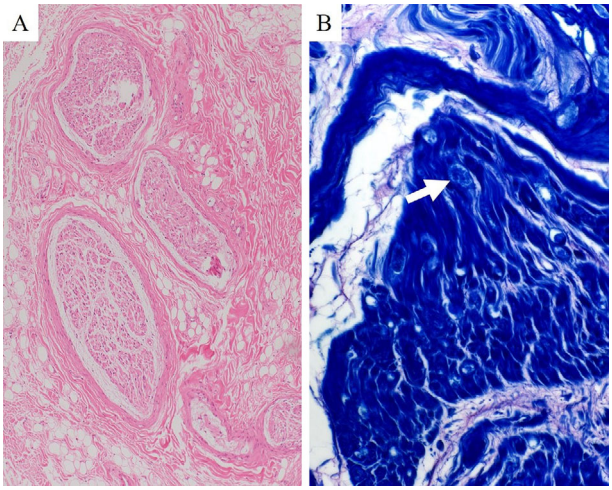

Figure 8. (A) Perineural fibrosis can be seen around the peripheral nerves of the left recurrent nerve, although no morphological changes of the nerves are apparent (original magnification, ×100). (B) A focal myelin digestion chamber (arrow) indicative of axonal degeneration was seen in the nerve; however, the possibility of artificial changes created by postmortem specimen preparation cannot be denied (Kluver-Barrera stain) (original magnification, ×600).

his poor prognosis following aspiration pneumonia, which was apparently related to the patient's left recurrent nerve paralysis. The patient's aspiration pneumonia persisted without disappearing completely, although it was slightly improved by the administration of antibiotics and bronchodilators and fluid replacement under a fasting condition. Eventually, his respiratory function worsened and deteriorated, probably due to respiratory muscle fatigue, leading to his death from heart failure and congestive edema.

There have been no reports evaluating the association between PPFE and aspiration pneumonia. The major etiology of recurrent nerve paralysis is tumors of the thyroid, esophagus, mediastinum, and pleura; tuberculosis; iatrogenic changes after cervical or mediastinal operation; diabetes mellitus; mitral valve stenosis; and rapid swelling of the pulmonary artery. As other rare causes, cases of coal worker pneumoconiosis with massive fibrosis, lung collapse associated cystic fibrosis, and invasive aspergillosis have been reported (12-15). The recurrent nerve paralysis associated with these diseases all occurred on the left side, as in the present case. This may be because the path of the left recurrent nerve in the rib cage is longer than that of the right (13). No other cause for recurrent nerve paralysis, including any of the above causes, was found in the present case aside from severe fibrous adhesion of the left apex to the chest wall associated with IPPFE. The left recurrent nerve paralysis was therefore probably due to fibrous adhesion resulting from pneumothorax and pleural fibrosis. Regarding the mechanism of recurrent laryngeal nerve palsy, tumors or other etiologic lesions can interfere with the nerve function by applying pressure to the nerve, causing nerve stretching by traction, or disrupting the nerve (12-14). In the present case, the nerve function probably suffered interference due to nerve retraction by fibrous tissue or stretching due to adhesion.

At the autopsy, the nerves around the left apex and the trachea showed focal myelin digestion chambers indicative of axonal degeneration, however, the possibility of artificial changes induced by postmortem specimen preparation must be entertained; therefore, we cannot safely claim this to be a significant finding. Regarding the morphological observation of peripheral nerves, glutaraldehyde fixation followed by epon embedding, thin sectioning, various special staining, and observation under electron microscopy are indispensable for observing the state of the myelin sheath and axons in detail (16). However, these methods are not generally performed in Japanese laboratories, and we were only able to perform morphological observations using formalin-fixed, paraffin-embedded specimens. We were thus unable to obtain details regarding the state of the myelin sheaths and axons. As such, while there were no remarkable changes in the nerves observed under light microscopy, it is quite possible that abnormalities might be identified using the above special staining procedures and electron microscopy. However, a previous study reported that although experimental traction of swine recurrent laryngeal nerves caused loss of the electromyographic signal, an electron microscope failed to identify any injury to the nerves (17). To our knowledge, there are no reports detailing the morphological changes in recurrent laryngeal nerve palsy in humans; we hope these will be reported in the future.

We suspected that aspiration pneumonia in the present case led progressive deterioration of the respiratory status due to IPPFE lesions; therefore, aspiration pneumonia may be listed as a trigger of death in patients with IPPFE with declined phase. The present patient might have survived a little longer despite IPPFE if aspiration pneumonia had not occurred. To prevent aspiration pneumonia, a comprehensive multidisciplinary team approach is necessary, including speech therapists, nutritionists, specialized nurses, physical therapists, and dentists. The active administrative commitment and participation by the team, such as in adjusting the body position and meal contents and performing thorough oral care, excretion training, and mastication training, can reduce the risk of aspiration pneumonia (18-20). Lardinois et al. reported a case with left recurrent laryngeal nerve paralysis associated with silicosis (21). They noted that progressive recovery of voice was observed 15 weeks after careful dissection of the nerve and release from scar encasement under video-mediastinoscopy. Therefore, in addition to efforts to prevent aspiration pneumonia, surgery may be another option if the lung function is preserved in such cases.

In conclusion, if pneumothorax associated with PPFE repeatedly occurs, fibrous adhesion can cause recurrent laryngeal nerve palsy. However, if a patient with PPFE suffers unexplained recurrent laryngeal palsy, PPFE-related chest wall adhesions might be present. While there is no definitive treatment for IPPFE at present other than lung trans-

plant (3, 22), efforts to prevent aspiration pneumonia are important for maintaining the respiratory function, especially in IPPFE patients with repeated pneumothorax.

The authors state that they have no Conflict of Interest (COI).

References

1. Travis WD, Costabel U, Hansell DM, et al. An official American Thoracic Society/European Respiratory Society statement: update of the international multidisciplinary classification of the idiopathic interstitial pneumonias. Am J Respir Crit Care Med **188**: 733-748, 2013.
2. Watanabe K. Pleuroparenchymal fibroelastosis: its clinical characteristics. Curr Respir Med Rev **9**: 229-237, 2013.
3. Righi I, Morlacchi L, Rossetti V, et al. Lung transplantation as successful treatment of end-stage idiopathic pleuroparenchymal fibroelastosis: a case report. Transplant Proc **51**: 235-238, 2019.
4. Kobashi Y, Ohba H, Yoneyama H, Okimoto N, Sakamoto K, Soejima R. A case of so-called "idiopathic pulmonary upper lobe fibrosis" complicated by both mediastinal emphysema and bilateral pneumothorax at different times. Kokyu **19**: 292-298, 2000 (in Japanese, Abstract in English).
5. Nei T, Kawamoto M, Satoh E, et al. A case of suspected idiopathic pulmonary upper lobe fibrosis (Amitani disease) with acute exacerbation. Nihon Kokyuki Gakkai Zasshi (Ann Jpn Respir Soc) **47**: 116-121, 2009 (in Japanese, Abstract in English).
6. Miyamoto A, Uruga H, Morokawa N, et al. Various bronchiolar lesions accompanied by idiopathic pleuroparenchymal fibroelastosis with a usual interstitial pneumonia pattern demonstrating acute exacerbation. Intern Med **58**: 1321-1328, 2019.
7. Kinoshita Y, Watanabe K, Ishii H, Kushima H, Fujita M, Nabeshima K. Significant increases in the density and number of lymphatic vessels in pleuroparenchymal fibroelastosis. Histopathology **73**: 417-427, 2018.
8. Frankel SK, Cool CD, Lynch DA, Brown KK. Idiopathic pleuroparenchymal fibroelastosis: description of a novel clinicopathologic entity. Chest **126**: 2007-2013, 2004.
9. Ishii H, Watanabe K, Kushima H, et al. Pleuroparenchymal fibroelastosis diagnosed by multidisciplinary discussions in Japan. Respir Med **141**: 190-197, 2018.
10. Yoshida Y, Nagata N, Tsuruta N, et al. Heterogeneous clinical features in patients with pulmonary fibrosis showing histology of pleuroparenchymal fibroelastosis. Respir Investig **54**: 162-169, 2016.
11. Watanabe K, Nagata N, Kitasato Y, et al. Rapid decrease in forced vital capacity in patients with idiopathic pulmonary upper lobe fibrosis. Respir Investig **50**: 88-97, 2012.
12. Haffar M, Banks J. Left vocal cord paralysis caused by coalworkers' pneumoconiosis and progressive massive fibrosis. Postgrad Med J **64**: 143-144, 1988.
13. Sherani TM, Angelini GD, Passani SP, Butchart EG. Vocal cord paralysis associated with coalworkers' pneumoconiosis and progressive massive fibrosis. Thorax **39**: 683-684, 1984.
14. Thompson RD, Empey DW, Bailey CM. Left recurrent nerve paralysis associated with complete lung collapse with consolidation in an adult with cystic fibrosis. Respir Med **90**: 567-569, 1996.
15. Nakahira M, Saito H, Miyagi T. Left vocal cord paralysis as a primary manifestation of invasive pulmonary aspergillosis in a nonimmunocompromised host. Arch Otolaryngol Head Neck Surg **125**: 691-693, 1999.
16. Oh SJ. Histological processing and staining of the biopsied nerve. In: Color Atlas of Nerve Biopsy Pathology. CRC Press, Boca Raton, FL, 2002: 25-34.
17. Lee HY, Cho YG, You JY, et al. Traction injury of the recurrent laryngeal nerve: results of continuous intraoperative neuromonitoring in a swine model. Head Neck **38**: 582-588, 2016.
18. Armstrong JR, Mosher BD. Aspiration pneumonia after stroke: intervention and prevention. Neurohospitalist **1**: 85-93, 2011.
19. Iwamoto M, Higashibeppu N, Arioka Y, Nakaya Y. Swallowing rehabilitation with nutrition therapy improves clinical outcome in patients with dysphagia at an acute care hospital. J Med Invest **61**: 353-360, 2014.
20. Aoki S, Hosomi N, Hirayama J, et al. The multidisciplinary swallowing team approach decreases pneumonia onset in acute stroke patients. PLoS One **11**: e0154608, 2016.
21. Lardinois D, Gugger M, Balmer MC, Ris HB. Left recurrent laryngeal nerve palsy associated with silicosis. Eur Respir J **14**: 720-722, 1999.
22. Aljefri NA, Abothenain FF, Hussein AM, et al. Idiopathic pleuroparenchymal fibroelastosis: the first case to be managed with a successful lung transplant at King Faisal Specialist Hospital and Research Center, Riyadh. Ann Thorac Med **14**: 94-98, 2019.

The Internal Medicine is an Open Access journal distributed under the Creative Commons Attribution-NonCommercial-NoDerivatives 4.0 International License. To view the details of this license, please visit (https://creativecommons.org/licenses/by-nc-nd/4.0/).

© 2020 The Japanese Society of Internal Medicine