

Is neuromuscular blocker needed in children undergoing inguinal herniorrhaphy?

A prospective, randomized, and controlled trial

Bon-Wook Koo, MD, PhD^a, Kyu-Whan Jung, MD, PhD^b, Ah-Young Oh, MD, PhD^{a,c,*}, Eun-Young Kim, MD^a, Hyo-Seok Na, MD, PhD^a, Eun-Su Choi, MD, PhD^d, Kwang-Suk Seo, MD, PhD^e

Abstract

Background: Intraoperative neuromuscular blocker is widely used, but is known to be associated with postoperative residual paralysis, which is known to be associated with increased risk of pulmonary complications. Hence, its use should be individualized and restricted to procedures where it is mandatory. We examined whether not using a neuromuscular blocker affects the surgical conditions in children undergoing inguinal herniorrhaphy.

Methods: Anesthesia was induced and maintained with sevoflurane in 60% nitrous oxide, and the airway was maintained using an l-gel. In total, 66 children aged 1 to 6 years were randomized to receive rocuronium (rocuronium group, n=33) or saline (control group, n=33); 61 children of them finished the study. A single surgeon who performed the operation rated the surgical condition of each patient on a 4-point scale (1=poor, 2=acceptable, 3=good, and 4=excellent). Intraoperative patient movement, recovery time, emergence agitation, and postoperative pain scores were evaluated.

Results: One patient in control group and no patient in rocuronium group showed intraoperative movement. When noninferiority test was done for intraoperative patient movement, with the noninferiority margin of 20%, the difference of absolute risk was 3.3% (95% confidence interval -8.0% to 16.7%) and saline group was noninferior to rocuronium group. All of the patients showed good to excellent surgical conditions, and no difference was found between the 2 groups. The recovery time was shorter in the control group than in the rocuronium group (4.5 ± 1.8 vs 5.6 ± 2.2 minutes, respectively; $P = .028$).

Conclusion: In children aged 1 to 6 years undergoing inguinal herniorrhaphy under sevoflurane anesthesia using an l-gel, not using neuromuscular blocker showed similar intraoperative condition and shortened recovery time compared with using neuromuscular blocker.

Abbreviations: PACU = postanesthetic care unit, FLACC = Face, Legs, Activity, Cry, and Consolability, LMA = laryngeal mask airway.

Keywords: inguinal herniorrhaphy, neuromuscular blocker, residual paralysis, surgery

Editor: Helen Gharaei.

B.-W.K. and K.-W.J. contributed equally.

Authors' contributions: B.-W.K.—study design and writing the first manuscript; K.-W.J.—study design and data collection (main operator); A.-Y.O.—revision and final approval of the version to be submitted; E.-Y.K.—data collection; H.-S.N.—data collection; E.-S.C.—random sequence table manage and data analysis; K.-S.S.—data analysis and statistical analysis.

The authors have no conflicts of interest to disclose.

^a Department of Anesthesiology and Pain Medicine, Seoul National University Bundang Hospital, Seongnam, ^b Department of Surgery, Jeju National University Hospital, Jeju, ^c Department of Anesthesiology and Pain Medicine, Seoul National University School of Medicine, ^d Department of Anesthesiology and Pain Medicine, Nowon Eulji Medical Center, Eulji University, ^e Department of Dental Anesthesiology, Seoul National University Dental Hospital, Seoul, Korea.

* Correspondence: Ah-Young Oh, Department of Anesthesiology and Pain Medicine, Seoul National University Bundang Hospital, 166 Gumi-ro, Bundang-gu, Seongnam-si, Gyeonggi-do 463-707, Korea (e-mail: oay1@snuhb.org).

Copyright © 2017 the Author(s). Published by Wolters Kluwer Health, Inc. This is an open access article distributed under the terms of the Creative Commons Attribution-Non Commercial-No Derivatives License 4.0 (CCBY-NC-ND), where it is permissible to download and share the work provided it is properly cited. The work cannot be changed in any way or used commercially without permission from the journal.

Medicine (2017) 96:26(e7259)

Received: 26 December 2016 / Received in final form: 2 May 2017 / Accepted: 31 May 2017

<http://dx.doi.org/10.1097/MD.0000000000007259>

1. Introduction

A neuromuscular blocker is widely used in anesthesia practice as a component of balanced anesthesia. It is used to facilitate endotracheal intubation and to maintain intraoperative surgical relaxation. However, the use of a neuromuscular blocker is not without complications, and vigilance is required for its full reversal at the end of surgery. Up to 50% of patients show postoperative residual curarization even after the use of intermediate-acting neuromuscular blockers.^[1] Postoperative residual curarization is associated with postoperative respiratory complications.^[2,3] The only way to confirm the full recovery of neuromuscular function is the qualitative monitoring of neuromuscular function, but the reality is not ideal. In addition, the intraoperative use of a neuromuscular blocker is a risk factor for accidental awareness during general anesthesia.^[4] In this regard, the use of an intraoperative neuromuscular blocker should be done cautiously and be confined to the procedure necessitating a neuromuscular blockade.

Concerning pediatric inguinal herniorrhaphy, the procedure may be performed using supraglottic airways, and a neuromuscular blockade for endotracheal intubation is not mandatory. Additionally, the surgical procedure is brief and would be completed before spontaneous recovery from the induction dose of the neuromuscular blocker. However, neuromuscular blockers are still used in some institutions for the purpose of improving the

surgical condition and assist intraoperative mechanical ventilation. In this study, we tried to find if not using neuromuscular blocker affects the surgical condition in children undergoing inguinal herniorrhaphy, by using noninferiority test.

2. Materials and methods

The study protocol was approved by the Ethical Committee of the Institutional Review Board on human research of Seoul National University Bundang Hospital (Seongnam, Korea) on August 2013 with the approval code of B-1307/212-002. It was also registered at cris.nih.go.kr (KCT0000991). Written informed parental consent was obtained from all of the patients. Written informed consent from patients was exempted by our Institutional Review Board, because they were preschool-aged young children. Patients aged 1 to 6 years with an American Society of Anesthesiologists Physical Status classification of 1 to 2, who were scheduled to undergo elective inguinal herniorrhaphy, were included. The exclusion criteria were a body mass index >25 m/kg², allergies to any of the study drugs, general conditions impairing neuromuscular function, a history of admission to the neonatal intensive care unit due to prematurity or other causes, and an upper airway infection. Sixty-six children were randomly allocated to receive rocuronium (rocuronium group, $n=33$) or saline (control group, $n=33$) using Random Allocation Software (version 2.0). The random table was kept in a sealed envelope and opened immediately before the induction of anesthesia. Both the anesthesiologist and surgeon assessing the outcome variables were blinded to the patient group. The drugs were prepared by an anesthesiology nurse who was not involved in either patient care or data collection.

All of the patients were transported to the operating room with their parents. After attaching standard monitoring devices for noninvasive blood pressure measurement, electrocardiography, and pulse oximetry, anesthesia was induced by the inhalation of sevoflurane in 60% nitrous oxide. After the loss of consciousness, intravenous access was performed, and rocuronium (0.45 mg/kg) or saline prepared in the same volume was injected. After 60 seconds, a single skilled anesthesiologist inserted the I-gel device (Intersurgical Ltd., Wokingham, Berkshire, UK) according to the manufacturer's instructions and assessed the insertion conditions (coughing, gagging, gross purposeful movements, laryngospasm, or trauma). Anesthesia was maintained with 2% to 3% sevoflurane in 60% nitrous oxide, and the lungs were ventilated to maintain an end-tidal carbon dioxide level of 4 to 4.6 kPa. Alfentanil (10 μ g/kg) was administered 1 to 2 minutes before the skin incision, and an additional dose of alfentanil (5 μ g/kg) was administered as needed according to the hemodynamic changes in the patients. Before the closure of the skin, regional anesthesia using 0.5%

bupivacaine HCl on the ilio-inguinal and ilio-hypogastric nerves was done by the surgeon. The surgeon was allowed to request a neuromuscular blockade if needed. When the surgery was completed, neostigmine (0.04 mg/kg) and glycopyrrolate (0.01 mg/kg) in the rocuronium group and the same volume of saline in the control group were injected. The I-gel was removed when spontaneous breathing and purposeful movements were observed. The time from the cessation of sevoflurane administration to removal of the I-gel was recorded as the recovery time.

A single surgeon who performed the surgery rated the surgical condition scores on a 4-point scale as follows: 1 = poor, surgery cannot proceed because of muscle contractions or gross patient movement; 2 = acceptable, muscle contractions causing some interference in the surgical procedure; 3 = good, only a few muscle contractions that do not affect the surgical procedure; and 4 = excellent, no muscle contractions at all. In addition, the I-gel insertion conditions, intraoperative movement or spontaneous breathing, and time from the cessation of inhalational agent administration to removal of the I-gel (recovery time) were evaluated. In the postanesthesia care unit (PACU), postoperative pain and anxiety scores (at arrival and before discharge from the PACU), additional opioids used, adverse effects, and duration of the PACU stay were recorded. Postoperative pain was evaluated using the pediatric Face, Legs, Activity, Cry, and Consolability (FLACC) pain scale (Table 1),^[5] and postoperative anxiety was evaluated using a 5-point agitation scale as follows: 1 = sleeping; 2 = awake, calm; 3 = irritable, crying; 4 = inconsolable, crying; and 5 = severe restlessness, disorientation.^[6] Fentanyl (1 μ g/kg) was administered as needed when severe pain or agitation was observed in the PACU. The surgical complications including the recurrence of hernia were observed until 1 year after surgery.

2.1. Statistical analysis

The sample size calculation for noninferiority trial was performed according to the priori study. Based on the 6% incidence of movement in the rocuronium group, the sample size to test the noninferiority was 30 patients per group with $\alpha=0.05$, power=0.90, and the noninferiority margin of the absolute risk of 20%. Considering the dropout rate of 10%, 33 patients per group were recruited.^[7] All data are expressed as the mean \pm SD, and number (% incidence). Patient characteristics and other clinical data were compared using Student *t* test, the chi-square test, and Fischer exact test, as appropriate. All *P* values were 2-sided and were deemed to indicate statistical significance at *P*=0.05. A statistical analysis of the data was performed using IBM SPSS Statistics (version 22.0; IBM Corp., Armonk, NY).

Table 1

The Face, Legs, Activity, Cry, Consolability pain scale.

Categories	Scoring		
	0	1	2
Face	No particular expression or smile	Occasional grimace or frown, withdrawn, disinterested	Frequent to constant frown, clenched jaw, quivering chin
Legs	Normal position or relaxed	Uneasy, restless, tense	Arched, rigid, or jerking
Activity	Lying quietly, normal position, moves easily	Squirming, shifting back and forth, tense	Arched, rigid, or jerking
Cry	No cry (awake or asleep)	Moans or whimpers, occasional complaint	Crying steadily, screams or sobs, frequent complaints
Consolability	Content, relaxed	Reassured by occasional touching, hugging, or being talked to, distractible	Difficult to console or comfort

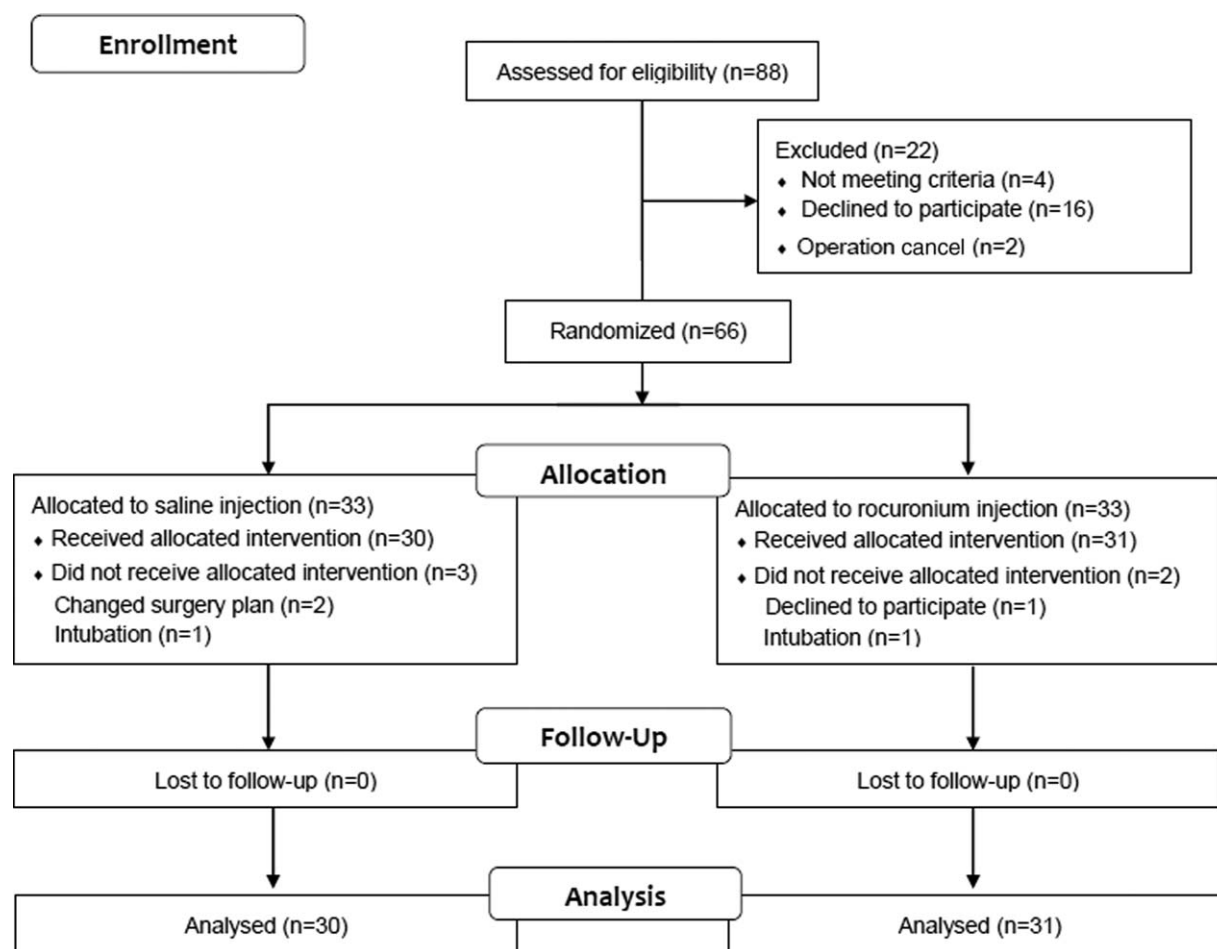


Figure 1. A CONSORT diagram.

3. Results

In all, 88 patients were screened, 66 were enrolled, and 61 were analyzed (Fig. 1). One child from the rocuronium group was excluded from the study because of refusing to participate and 2 children from the control group were also excluded due to changing surgery plan. Also, 1 child in each group was excluded due to laryngeal spasm requiring intubation. No difference in patient characteristics was detected between the groups (Table 2). One patient in control group and no patient in rocuronium group showed intraoperative movement. When noninferiority test was done for intraoperative patient movement, with the noninferiority margin of 20%, the difference of absolute risk was 3.3% (95% confidence interval [CI] -8.0% to 16.7%) and saline

Table 2

Patient characteristics.

	Saline (n=30)	Rocuronium (n=31)
Male/female (n)	22/8	21/10
Age, mos (mean \pm SD)	49.1 \pm 17.3	42.8 \pm 19.5
Weight, kg (mean \pm SD)	17.4 \pm 4.7	16.8 \pm 5.4
Height, cm (mean \pm SD)	104.7 \pm 12.1	100.4 \pm 14.2
BMI, m/kg ² (mean \pm SD)	15.6 \pm 1.8	16.3 \pm 2.2
ASA (I/II) (n)	29/1	30/1

ASA=american society of anesthesiologists physical status, BMI=body mass index, SD=standard deviation.

group was noninferior to rocuronium group. There was no intraoperative additional request from the surgeon for a neuromuscular blocker. All of the patients were rated good to excellent on a surgical rating scale and were not different between the groups (Fig. 2). The recovery time was significantly longer in the rocuronium group than in the control group (5.6 ± 2.2 vs 4.5 ± 1.8 minutes, respectively; $P = .028$). Other intraoperative and postoperative variables such as the operation time, anesthesia time, PACU stay time, and postoperative anxiety and pain scores were not different between the groups. A few patients needed intraoperative or postoperative additional opioids, but did not show a difference between the groups (Tables 3 and 4). One patient in the rocuronium group showed symptoms of postoperative residual curarization in the PACU and had a delayed discharge from the PACU—45 minutes compared with an average time of 23.8 minutes. One patient in the control group showed testicular torsion 2 days after surgery, and no patient showed recurrence of inguinal hernia until 1 year after surgery.

4. Discussion

The main finding of this study is that the use of a neuromuscular blocker did not influence the incidence of intraoperative patient movement or the surgical condition in children undergoing inguinal herniorrhaphy using an I-gel. There was also no difference in postoperative surgical complications including

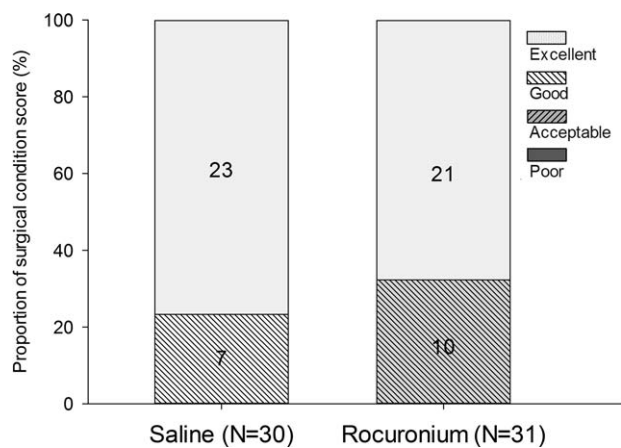


Figure 2. The distribution of a surgical condition score. 1=poor, 2=acceptable, 3=good, 4=excellent ($P=.570$).

recurrence of hernia. Additionally, the recovery times were longer in the rocuronium group than in the control group. The difference was only approximately 1 minute; however, considering the instability of the patients' condition during this period, the difference is meaningful. Because of the short duration of the procedure, we reduced the dose of rocuronium and only used 0.45 mg/kg ($1.5 \times ED_{95}$) instead of 0.6 mg/kg ($2 \times ED_{95}$). Had we used the full intubating dose of rocuronium, the difference in recovery time might have been greater.

We were able to find only a few studies regarding the necessity of neuromuscular blockers in specific surgical procedures, and the studies were concerned exclusively with adults. One concerned radical retropubic prostatectomy, in which significantly more patients showed good to excellent surgical conditions with neuromuscular blockers than patients without them.^[8] However, the authors concluded that the routine use of neuromuscular blockers in adequately anesthetized patients undergoing this process might not be indicated because two-thirds of patients without the use of neuromuscular blockers showed a good to excellent surgical condition. The other study concerned laparoscopic gynecological surgery^[9]; the authors concluded that a neuromuscular blockade was not necessary in general anesthesia using ProSeal laryngeal mask airway (LMA) for this process. They reported that the insertion conditions for ProSeal LMA and surgical conditions were comparable with or without neuromuscular blockers, and that the recovery time was shorter in the group without the neuromuscular blocker. Our

Table 3

Intraoperative characteristics.

	Saline (n=30)	Rocuronium (n=31)	P
Operation times, min (mean \pm SD)	16.5 \pm 10.0	13.0 \pm 5.8	0.106*
Anesthesia times, min (mean \pm SD)	32.3 \pm 10.3	31.6 \pm 7.9	0.761*
Recovery times, min (mean \pm SD)	4.5 \pm 1.8	5.6 \pm 2.2	0.028*
Additional opioids, %	2 (6.6)	1 (3.2)	0.612†
Movement, %	1 (3.3)	0 (0)	0.492†
Spontaneous breathing, %	3 (10)	3 (9.6)	0.934†
I-gel reposition, %	3 (10)	1 (3.2)	0.324†

SD = standard deviation.

* Student *t* test.

† Chi-square test.

Table 4

Postoperative characteristics.

	Saline (n=30)	Rocuronium (n=31)	P
PACU stay times, min (mean \pm SD)	21.3 \pm 3.1	23.8 \pm 7.2	0.082*
Anxiety scores (at arrival) (mean \pm SD)	2.5 \pm 1.2	2.3 \pm 1.0	0.538*
Anxiety scores (before discharge) (mean \pm SD)	2.3 \pm 0.7	2.1 \pm 0.6	0.324*
Pain scores (at arrival) (mean \pm SD)	3.8 \pm 3.0	3.3 \pm 2.6	0.464*
Pain scores (before discharge) mean \pm SD	2.1 \pm 1.8	1.5 \pm 2.1	0.232*
Additional opioids (%)	17 (56.6)	17 (54.8)	0.886†

PACU = postanesthesia care unit, SD = standard deviation.

* Student *t* test.

† Chi-square test.

study is different from previous ones in that we studied young children aged 1 to 6 years, and the surgical procedure was limited to inguinal herniorrhaphy. However, our results are in line with those of previous studies in that the insertion conditions for the I-gel and surgical conditions were comparable between the groups, whereas the recovery time was prolonged in the group that received a neuromuscular blocker.

Although neuromuscular blockers are valuable components of general anesthesia, there are several undesirable effects. First, postoperative residual curarization is the most common complication. With a train-of-four ratio <0.9 , the reported incidence of postoperative residual curarization is as high as 50% after the use of an intermediate-duration neuromuscular blocker, with the highest incidence reported after short surgical procedures.^[1,10,11] In children, however, recovery from a neuromuscular blockade is quicker and postoperative residual curarization is rarer than in adults.^[12] Nevertheless, caution should be used to prevent residual curarization in patients recovering from a neuromuscular blockade. Indeed, 1 of our patients in the rocuronium group had a delayed discharge from the PACU due to symptoms of residual curarization. Second, neuromuscular blockers are the leading cause of perioperative anaphylaxis. Although the incidence of perioperative anaphylaxis is not high, it is a serious life-threatening complication, with a reported mortality of 3% to 9%.^[13] Third, neuromuscular blocker is 1 of the factors increasing the risk of accidental awareness during general anesthesia.^[4] Of the patients who had recall of intraoperative events, all of the paralyzed patients had pain, anxiety, or delayed neurotic symptoms compared with none of the nonparalyzed patients.^[14] In this regard, the routine use of neuromuscular blockers during general anesthesia should be reconsidered and should be confined to procedures with an obvious gain.

Our study has several limitations. First, we used sevoflurane for the maintenance of anesthesia, despite the fact that inhalational anesthetics have some degree of muscle-relaxant properties. It remains to be elucidated what would be the outcome under intravenous anesthesia. Second, our study population was limited to very young children, aged 1 to 6 years, whose muscle power is relatively weak and could be easily controlled. Our results cannot be extended to older children or adults. Third, we did not use intraoperative neuromuscular monitoring and cannot rule out the possibility of postoperative residual curarization in patients who received rocuronium, which might affect the recovery time or postoperative agitation score. However, most of our patients recovered well; only 1 patient in the rocuronium group showed symptoms of residual curarization in the PACU, but fully recovered without complication.

5. Conclusions

In conclusion, not using neuromuscular blocker in children aged 1 to 6 years undergoing inguinal herniorrhaphy under sevoflurane anesthesia using an I-gel does not affect the surgical condition and results in faster recovery from anesthesia.

References

- [1] Murphy GS, Szokol JW, Avram MJ, et al. Intraoperative acceleromyography monitoring reduces symptoms of muscle weakness and improves quality of recovery in the early postoperative period. *Anesthesiology* 2011;115:946–54.
- [2] Murphy GS, Szokol JW, Marymont JH, et al. Residual neuromuscular blockade and critical respiratory events in the postanesthesia care unit. *Anesth Analg* 2008;107:130–7.
- [3] Sikich N, Lerman J. Development and psychometric evaluation of the pediatric anesthesia emergence delirium scale. *Anesthesiology* 2004;100:1138–45.
- [4] Pandit JJ, Andrade J, Bogod DG, et al. 5th National Audit Project (NAP5) on accidental awareness during general anaesthesia: summary of main findings and risk factors. *Br J Anaesth* 2014;113:549–59.
- [5] Merkel SI, Voepel-Lewis T, Shayevitz JR, et al. The FLACC: a behavioral scale for scoring postoperative pain in young children. *Pediatr Nurs* 1997;23:293–7.
- [6] Cole JW, Murray DJ, McAllister JD, et al. Emergence behaviour in children: defining the incidence of excitement and agitation following anaesthesia. *Paediatr Anaesth* 2002;12:442–7.
- [7] Blackwelder WC. Proving the null hypothesis” in clinical trials. *Control Clin Trials* 1982;3:345–53.
- [8] King M, Sujirattanawimol N, Danielson DR, et al. Requirements for muscle relaxants during radical retropubic prostatectomy. *Anesthesiology* 2000;93:1392–7.
- [9] Chen BZ, Tan L, Zhang L, et al. Is muscle relaxant necessary in patients undergoing laparoscopic gynecological surgery with a ProSeal LMA? *J Clin Anesth* 2013;25:32–5.
- [10] Debaene B, Plaud B, Dilly MP, et al. Residual paralysis in the PACU after a single intubating dose of nondepolarizing muscle relaxant with an intermediate duration of action. *Anesthesiology* 2003;98:1042–8.
- [11] Fawcett WJ. Atracurium is associated with postoperative residual curarization. *Br J Anaesth* 2003;90:810[author reply 810].
- [12] Baxter MR, Bevan JC, Samuel J, et al. Postoperative neuromuscular function in pediatric day-care patients. *Anesth Analg* 1991;72:504–8.
- [13] Galvao VR, Giavina-Bianchi P, Castells M. Perioperative anaphylaxis. *Curr Allergy Asthma Rep* 2014;14:452.
- [14] Sandin RH, Enlund G, Samuelsson P, et al. Awareness during anaesthesia: a prospective case study. *Lancet (London, England)* 2000;355:707–11.