

A rare case of a middle ear glomangioma

SAGE Open Medical Case Reports
Volume 10: 1–4
© The Author(s) 2022
Article reuse guidelines:
sagepub.com/journals-permissions
DOI: 10.1177/2050313X211070520
journals.sagepub.com/home/sco



Margaret E Wieser¹ , David R Gilley² ,
Jason G May³ and Arnaldo L Rivera²

Abstract

Glomus tumors are benign hyperplasia of glomus bodies, and they are rarely found in the head and neck. The middle ear is an exceptionally rare site for a true glomus tumor, and there are only three previously reported cases in this location. Glomus tumors are etiologically different than glomus tympanicum, which are paragangliomas of the middle ear that are often mistakenly referred to as “glomus tumors.” This is a common misconception due to the “glomus” misnomer. We report a case of a patient diagnosed with a middle ear glomangioma after initially presenting to our clinic with tinnitus and hearing loss. The mass was surgically removed through a transcanal approach with carbon dioxide laser and sharp dissection. Literature review is also reported and revealed similar presentations in patients with middle ear glomangiomas.

Keywords

Otolaryngology, otology, middle ear tumor, unilateral hearing loss, glomus tumor, histopathology, glomangioma

Date received: 21 October 2021; accepted: 14 December 2021

Introduction

Glomus bodies are neuromyocutaneous structures that are important for regulating temperature via arteriovenous shunting of blood.¹ Benign hyperplasia of glomus bodies results in glomus tumors, which are rare soft tissue tumors usually found in the extremities. However, glomus tumors have been described in almost every location and can even occur in areas that do not contain glomus bodies.² It is important to distinguish them from paragangliomas, which are more common in the head and neck and often erroneously referred to as “glomus tumors.” True glomus tumors can be further categorized based on their histopathology into solid glomus tumors, glomangiomas, and glomangiomyomas. Glomangiomas are the second most common variant and are so named due to their prominence of vascularity.^{1,3}

Glomus tumors of any subtype are especially rare occurrences in the head and neck. They occur most often as nasal glomangiomas, of which there have only been 33 cases described in the literature.^{4,5} The middle ear is an even more exceptionally rare location for these tumors with only three cases reported in the literature to date.⁶ We report a case of a middle ear glomangioma, which is the fourth reported case of a glomangioma in this location.

Case report

A 64-year-old female with history of hypertension and headaches was referred to our clinic after 2 years of gradually

worsening pulsatile tinnitus and feeling of ear fullness that was refractory to medical management. She had a new onset of left otalgia, but otherwise denied otorrhea, acute change in hearing, or any previous injuries or surgeries to either ear. On exam, the left tympanic membrane was intact, but there was a red mass deep to the posteroinferior quadrant. The external auditory canal was unremarkable. On audiologic evaluation, she was found to have mild to moderate mixed hearing loss (sensorineural component was mild) in the left ear, with type A tympanogram.

Computed tomography (CT) of the temporal bones from outside hospital demonstrated an enhancing soft tissue mass arising from the hypotympanum, adjacent to the inferior tympanic canaliculus (Figure 1). Based on exam and imaging findings, the mass was suspected to be a glomus tympanicum. Urinary metanephrines were collected and were negative. CT angiogram identified a tumor blush in

¹Degree Program, University of Missouri School of Medicine, Columbia, MO, USA

²Department of Otolaryngology—Head and Neck Surgery, University of Missouri School of Medicine, Columbia, MO, USA

³Department of Otolaryngology—Head and Neck Surgery, Children’s Mercy Hospital, Kansas City, MO, USA

Corresponding Author:

Margaret E Wieser, University of Missouri School of Medicine, One Hospital Drive, Columbia, MO 65212, USA.
Email: Mel7zd@health.missouri.edu



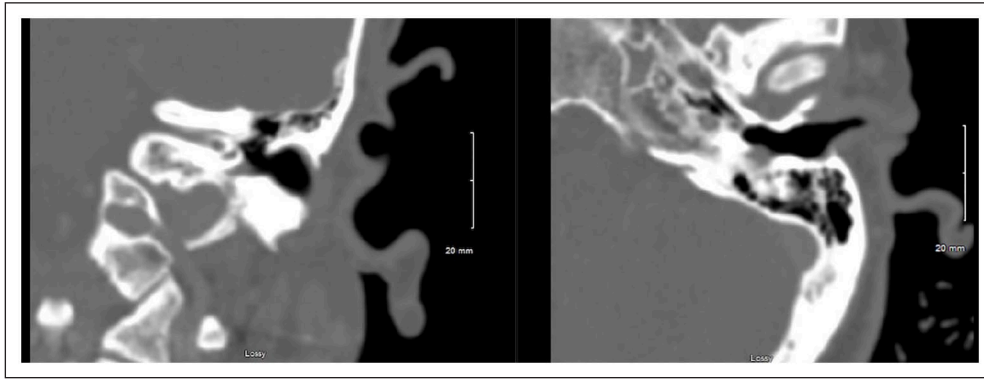


Figure 1. Coronal (left) and axial (right) images from CT temporal bone without contrast demonstrate enhancing soft tissue mass arising from the hypotympanum, adjacent to the inferior tympanic canaliculus.

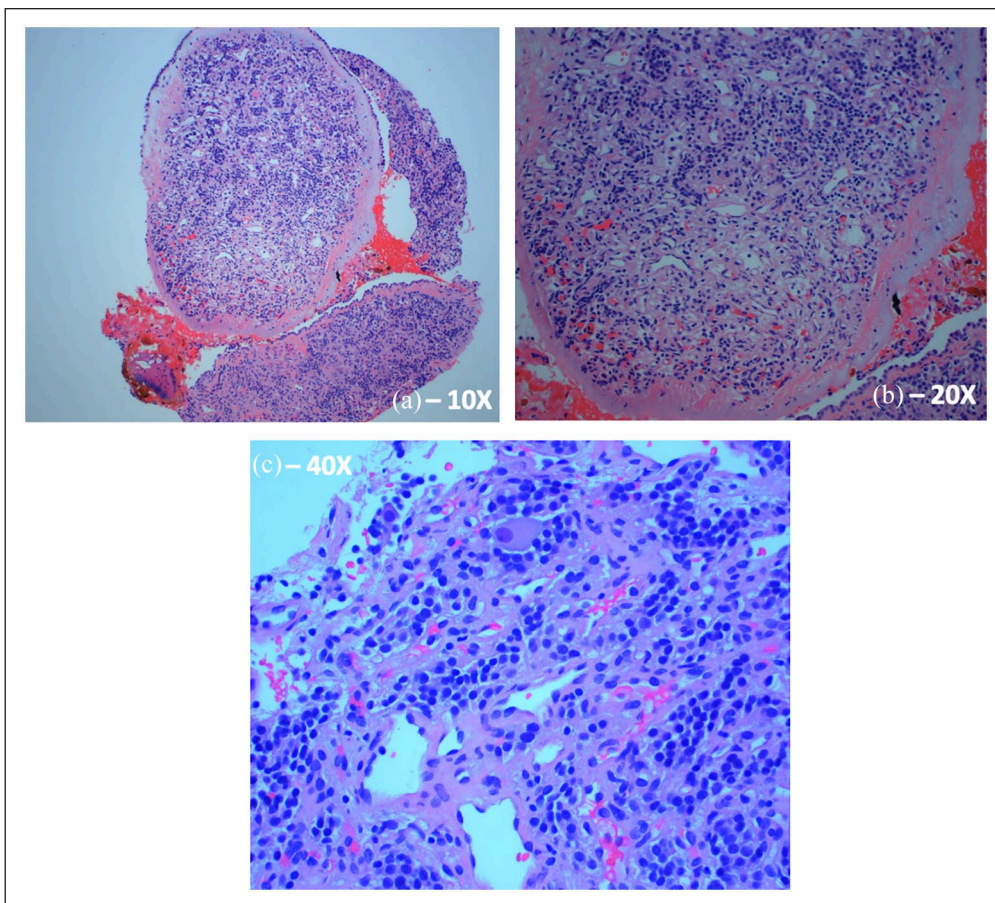


Figure 2. (a, b) Well-circumscribed lesion composed of small capillaries with areas containing discrete nests of blast cells with monomorphic round nuclei. (c) There is significant vascularity throughout the tumor representing a glomangioma variant of the glomus tumor.

left tympanic region supplied by left ascending pharyngeal artery.

The patient underwent a transcanal excision of the tumor with carbon dioxide (CO₂) laser using the Omni guide system 29 days after neurotology visit. The tumor was identified extending into the mesotympanum and was attached to the

inferior promontory and hypotympanum. This was removed completely with a combination of CO₂ laser and sharp dissection. There was no ossicular erosion identified, and normal movement of the ossicles was noted. No complications were observed postoperatively. Surgical specimen was sent to the lab, and histopathology is shown in Figure 2. Final

Table 1. All reported cases of glomangiomas in the middle ear.

Pt.#	Year (Ref. #)	Age/sex	Middle ear	Audius ad antrum	Mastoid air cells	Hearing loss	Tinnitus	EAC
1	2004 ⁷	62/F	Y	Y	Y	Y	Y	Y
2	2012 ⁸	54/F	Y	Y	Y	Y	Y	NR
3	2018 ⁶	36/F	Y	Y	Y	Y	NR	NR
4 ^a	2021	64/F	Y	N	N	Y	Y	NR

F: female; EAC: external auditory canal; Y: yes; N: no; NR: not reported; Ref: reference.

^aPresent case.

report was a glomangioma variant of a glomus tumor. Immunohistochemistry was not performed due to the characteristic appearance of the specimen.

The patient followed up 1 month after procedure. She still had occasional pulsatile tinnitus, but she was otherwise doing well. Otomicroscopy revealed appropriate healing without concerns for recurrent glomus tumor, granulation tissue, tympanic membrane perforation, or purulent otorrhea.

Discussion

Glomus tumors result from hyperplasia of glomus bodies and the vast majority are benign, showing no abnormal mitotic figures. Complete excision is considered to be curative. However, the tumors are not encapsulated, and it is possible to have tumor recurrence if not completely excised.⁶ True glomus tumors are rare in the head and neck. This is the fourth reported case of a middle ear glomangioma, all of which have occurred in females and been further classified as glomangiomas.^{6–8} Our patient presented similarly to previous cases with pulsatile tinnitus, ear fullness, and objective hearing loss (see Table 1). She later developed otalgia.

Pulsatile tinnitus and hearing loss are also the usual presentation of glomus tympanicum tumors,⁹ which are similar to the four reported cases of the middle ear glomangiomas. Glomus tympanicum is a benign highly vascular extra-adrenal paraganglioma⁹ and is the most common primary neoplasm of the middle ear.¹⁰ Since the name of these neoplasms is a misnomer, they are often mistakenly referred to as “glomus tumors,” even though they have different cell origin and etiologies than true glomus tumors. Other head and neck paragangliomas also contain this misnomer, as glomus vagale and glomus jugulare tumors are also paragangliomas.

We initially suspected our patient’s mass to be a glomus tympanicum tumor and further evaluated it with laboratory evaluation for metanephrines, which were negative. Only 1%–8% of extra-adrenal paragangliomas secrete catecholamines,^{11,12} so negative laboratory evaluation does not rule out glomus tympanicum. True glomus tumors are not of neuroendocrine origin and so will not secrete catecholamines; thus, the negative lab workup is consistent retrospectively as well. Even though lab exam is not sensitive for paragangliomas, it is always recommended to evaluate a possible glomus tumor with urinary and/or plasma metanephrines

because of potential complications with unexpected catecholamine release intraoperatively with tumor dissection.^{13,14}

Due to the overlap in clinical presentation, pathology and immunohistochemistry are the only way to truly differentiate glomus tumors like glomangiomas from glomus tympanicum tumors. Unlike glomus tympanicum tumors, glomangiomas stain negatively for neuroendocrine markers such as chromogranin A, S100, and synaptophysin.^{6–8} Instead, pathology shows positive expression of smooth muscle actin (SMA).^{7,8} In our case, immunochemistry was not performed due to the characteristic appearance of the specimen.

Conclusion

Literature review revealed three total cases of patients presenting a middle ear mass that was later diagnosed as a glomangioma. Our case establishes a fourth occurrence of such tumor. Consistent symptoms of these tumors are tinnitus, ear fullness, and objective hearing loss. Although rare, increasing case reports of this entity suggest that glomangiomas should be included on the wide differential diagnosis when a patient presents with a middle ear mass behind an intact tympanic membrane.

Acknowledgements

We thank Dr. Eric Johannesen, assistant professor of clinical pathology and anatomical sciences, for description of pathology and access to slides.

Declaration of conflicting interests

The author(s) declared no potential conflicts of interest with respect to the research, authorship, and/or publication of this article.

Funding

The author(s) received no financial support for the research, authorship, and/or publication of this article.


Ethical approval

Our institution does not require ethical approval for reporting individual cases or case series.

Informed consent

Written informed consent was obtained from the patient(s) for their anonymized information to be published in this article.

ORCID iDs

Margaret E Wieser  <https://orcid.org/0000-0001-6727-504X>

David R Gilley  <https://orcid.org/0000-0003-2421-3847>

References

1. Gombos Z and Zhang PJ. Glomus tumor. *Arch Pathol Lab Med* 2008; 132(9): 1448–1452.
2. Chou T, Pan SC, Shieh SJ, et al. Glomus tumor: twenty-year experience and literature review. *Ann Plast Surg* 2016; 76(Suppl 1): S35–S40.
3. Fletcher CD. Pathology and genetics of tumors of soft tissue and bone. *World Health Organ Classif Tumors* 2002; 4: 35–46.
4. Chirila M and Rogojan L. Glomangioma of the nasal septum: a case report and review. *Ear Nose Throat J* 2013; 92(4–5): E7–E9.
5. Chen PJ and Chen HC. Glomus tumor of the nasal septum. *Clin Surg* 2018; 3: 2079.
6. Kaufman AC, Brant JA, Luu NN, et al. Recurrent glomangioma (“true” glomus tumor) of the middle ear and mastoid. *World J Otorhinolaryngol Head Neck Surg* 2019; 5(4): 175–179.
7. Uyar Y, Ulku CH, Koral H, et al. Glomangioma of the middle ear. *Acta Otolaryngol* 2004; 124(7): 867–869.
8. Choi JH. Glomangioma (“true” glomus tumor) presenting as a white middle ear mass behind an intact tympanic membrane. *Otol Neurotol* 2012; 33(6): e51–e52.
9. Hinerman RW, Amdur RJ, Morris CG, et al. Definitive radiotherapy in the management of paragangliomas arising in the head and neck: a 35-year experience. *Head Neck* 2008; 30(11): 1431–1438.
10. O’Leary MJ, Shelton C, Giddings NA, et al. Glomus tympanicum tumors: a clinical perspective. *Laryngoscope* 1991; 101(10): 1038–1043.
11. Kuhweide R, Lanser MJ and Fisch U. Catecholamine-secreting paragangliomas at the skull base. *Skull Base Surg* 1996; 6(1): 35–45.
12. Schwaber MK, Glasscock ME, Nissen AJ, et al. Diagnosis and management of catecholamine secreting glomus tumors. *Laryngoscope* 1984; 94(8): 1008–1015.
13. Jackson CG, Welling DB, Chironis P, et al. Glomus tympanicum tumors: contemporary concepts in conservation surgery. *Laryngoscope* 1989; 99(9): 875–884.
14. Sweeney AD, Carlson ML, Wanna GB, et al. Glomus tympanicum tumors. *Otolaryngol Clin N Am* 2015; 48(2): 293–304.