

CASE REPORT

# A case of aortic dissection with highly suggestive features of COVID-19

Tahir Shahzad<sup>1,\*</sup>, Mulham Mohamed Salih Mustafa<sup>3</sup>, Zain A. Bhutta<sup>1,2</sup>, TimRichard Edmund Harris<sup>1</sup>

Address for Correspondence:

**Tahir Shahzad<sup>1</sup>**

<sup>1</sup>Emergency Department, Hamad Medical Corporation Qatar, Doha, Qatar

<sup>2</sup>Department of Emergency Medicine and Service, Helsinki University Hospital, Helsinki, Finland

<sup>3</sup>Department of Infectious Diseases, Communicable Disease Centre, Hamad Medical Corporation Qatar, Doha, Qatar

Email: tshahzad@hamad.qa

<http://dx.doi.org/10.5339/qmj.2020.34>

Submitted: 28 June 2020

Accepted: 20 September 2020

© 2020 Shahzad, Mustafa, Bhutta, Harris, licensee HBKU Press. This is an open access article distributed under the terms of the Creative Commons Attribution license CC BY 4.0, which permits unrestricted use, distribution and reproduction in any medium, provided the original work is properly cited.

Cite this article as: Shahzad T, Mustafa MMS, Bhutta ZA, Harris TRE. A case of aortic dissection with highly suggestive features of COVID-19, Qatar Medical Journal 2020;34 <http://dx.doi.org/10.5339/qmj.2020.34>

كيساينس  
QSCIENCE

دار جامعة حمد بن خليفة للنشر  
HAMAD BIN KHALIFA UNIVERSITY PRESS

## ABSTRACT

**Introduction:** Aortic dissection is a cardiovascular emergency with an overall in-hospital mortality rate of 27.4%, and with every hour without intervention, the mortality rate increases by 1%–2% in the first 48 hours. Thoracic aortic dissection typically presents with tearing chest, back, or abdominal pain.

Coronavirus disease 2019 (COVID-19) is a viral disease caused by severe acute respiratory syndrome – coronavirus 2 (SARS – Cov2), which has been declared a pandemic by the World Health Organization (WHO) and usually manifests with respiratory symptoms, including cough, shortness of breath, flu-like symptoms, and fever. This case report highlights an important impact of the COVID-19 pandemic on the identification and management of aortic dissection in the emergency department.

**Case report:** A 35-year-old Bahraini male, a suspected case of Marfan syndrome, presented with complaints of shortness of breath and worsening productive cough after returning from the United States (U.S). He denied any chest, back, or abdominal pain, dizziness, weakness in any limb, gait disturbance, headache, or change in vision. He was considered high risk for COVID-19 because of the recent travel and respiratory symptoms and was diagnosed incidentally with ascending aortic dissection along with a right lung consolidation. His SARS – Cov2 PCR came negative thrice during hospital stay, and he underwent elective cardiothoracic surgery.

**Conclusion:** The COVID-19 pandemic has been a major stressor for the healthcare system worldwide, inflicting serious threats. Aortic dissection is one of the major life-threatening diseases that needs to be identified early on in the emergency department; however, in this case delayed diagnosis raised

significant concerns due to underlying evolving triaging system for COVID-19 and atypical and overlapping clinical presentation. Further research is needed to look for COVID-19 – associated factors, affecting the standard of care in the emergency department. Improving handover can directly impact patient care; therefore, it should be optimized.

Keywords: Aortic diseases, Pandemic, Coronavirus, Asymptomatic diseases

## INTRODUCTION

Aortic dissection is a life-threatening condition with high mortality and morbidity rates without intervention, its overall in-hospital mortality rate being 27.4% [1]. Diagnosing acute aortic dissection (AAD) in the emergency department is of prime importance because with every hour without intervention, the mortality rate increases by 1%–2% in first 48 hours [2]. Thoracic aortic dissection is divided into two types using the Stanford system: type A and type B. Type A includes ascending aorta dissection, while type B includes descending aorta dissection (distal to left subclavian artery origin); Stanford type A has a higher mortality rate than type B [1]. AAD classically presents with a sudden-onset chest, back, or abdominal pain; however, atypical presentations can lead to catastrophic manifestations due to delayed diagnosis [2].

Coronavirus disease 2019 (COVID-19) is a viral disease caused by a novel coronavirus, severe acute respiratory syndrome – coronavirus 2. It started from the city of Wuhan in Hubei province of China in December 2019, later declared as a pandemic by the World Health Organization (WHO). COVID-19 is spreading exponentially worldwide, taking 771,635 lives with 21,756,357 confirmed cases according to WHO's COVID-19 dashboard updated on 18 August 2020 [3]. Its most common manifestations are respiratory symptoms. This case report highlights the importance of identifying the atypical presentation of life-threatening aortic dissection in this time of COVID-19 pandemic, which can act as a serious distractor to emergency physicians.

## CASE REPORT

A 35-year-old Bahraini male was brought by the emergency medical services (EMS) to the emergency department of Hamad General Hospital on 19 March 2020 at 15:30 from one of the quarantine facilities in

Qatar with complaints of shortness of breath (SOB) and worsening productive cough for the last 2 days associated with a small amount (approximately quarter of a teaspoon) of blood-tinged sputum. The patient was triaged to the isolation room in a high-acuity area suspected of COVID-19 based upon his respiratory symptoms and recent travel from the United States (U.S). He denied any chest, back, or abdominal pain, nausea, vomiting, change in vision, weakness in any limb, headache, fever, and black stools. He returned to Qatar from the U.S on 17 March 2020 and was placed in the quarantine facility according to the state protocol for COVID-19 screening. In the U.S, he was operated for thoracoabdominal aortic aneurysm and infra-renal aortic dissection diagnosed in October 2019 at Hamad General Hospital when he came with a left flank pain. The patient was suspected to be a case of Marfan syndrome based on his body habitus during the same visit in 2019, but he had no significant family history or any psychological illness. He also denied any addiction. Patient's vital signs Table 1 shows the patient's vital signs upon arrival to the emergency department.

On examination, the patient was found lying in bed comfortably. He had crepitation and rhonchi in the right chest (lower zone), regular fast pulse. No discrepancy in blood pressure in either of the upper limbs and no neurological deficit were noted, and the power in all limbs was 5/5, with a Glasgow coma scale of 15/15. Pupils were 3 mm bilaterally equal and reactive to light, the abdomen was soft and lax with no tenderness. Initial ECG showed right bundle branch block, extreme axis deviation (north-west), junctional rhythm, and no evidence of acute ischemic changes compared to previous ECGs. The patient was investigated with the suspicion of lower respiratory tract infection, including COVID-19 and pulmonary embolism. Nasopharyngeal and throat swab was performed for COVID-19 PCR testing. The patient's initial blood investigations were not

**Table 1. Patient's vital signs**

Noninvasive blood pressure	110/82 mm Hg
Peripheral pulse rate	124/minute
Oral temperature	36.9°C
Mean arterial pressure	91 mm Hg
Pulse oximetry	98% RA
Respiratory rate	24/minute

**Table 2. Blood Investigations**

Investigations	Results
Trop T (1st)	29 ng/L
Trop T (2nd)	28 ng/L
CRP	39.2 mg/L
Ph	7.48
Po2 (arterial)	77 mmHg
Hemoglobin	10.7 gm/dl
CRP	39.2 mg/L
WBC	9.0 * 10 <sup>3</sup>
Creatinine	70 umol/L
CRP	39.2 mg/L

significantly abnormal, with a negative first PCR result for COVID-19 [Tables 2 and 3]. Chest x-ray showed right-sided lung consolidation, with a similar mediastinum measurement to a previous chest x-ray in October 2019 at Hamad General Hospital for thoracoabdominal aortic aneurysm [Figure 1]. The patient was handed over from the evening shift (15:00 – 23:00 hrs) to the night shift (23:00 – 07:00 hrs) as a suspected COVID-19 case managed initially with 1 liter normal saline 0.9% IV, 1 gm IV paracetamol, 500 mg IV azithromycin, and 2 gm IV ceftriaxone while waiting for internal medicine consultation and COVID-19 PCR result. According to the endorsement, computed tomography pulmonary artery scan (CTPA) showed no filling defect in the pulmonary artery. Upon reviewing the patient chart in

the electronic medical record, we found a report of CTPA (reported at 20:51 hrs) mentioning a dissection of the ascending aorta extending from the root of aorta to the right common carotid artery and a consolidative patch in the right middle and lower lobes of the lungs [Figure 2].

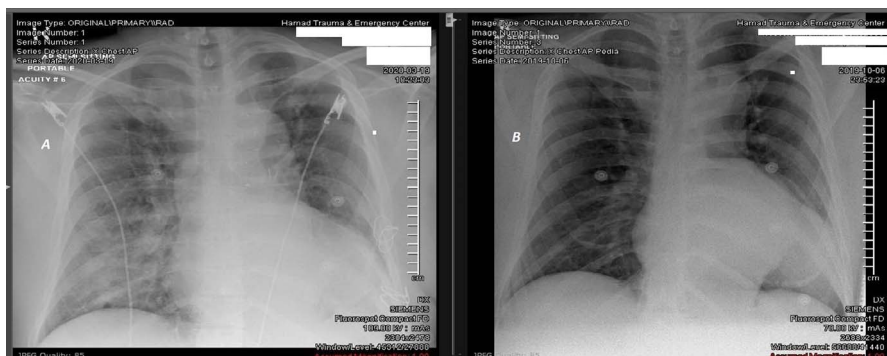
During the entire emergency stay, the patient remained stable hemodynamically and clinically, with no new symptom reported apart from the ones during arrival. ECG-gated CT thorax was planned, and cardiothoracic surgery was immediately consulted. The ECG-gated CT thorax was reported at 03:51 hrs on 20 March 2020 as a Stanford type A dissection, which is a new finding compared to previous CT during admission to the hospital in October 2019 [Figure 2]. The patient was admitted to the cardiothoracic intensive care unit.

The patient was tested two times more for COVID-19, both yielding negative results on 22<sup>nd</sup> March and 18<sup>th</sup> April, 2020 [Table 3].

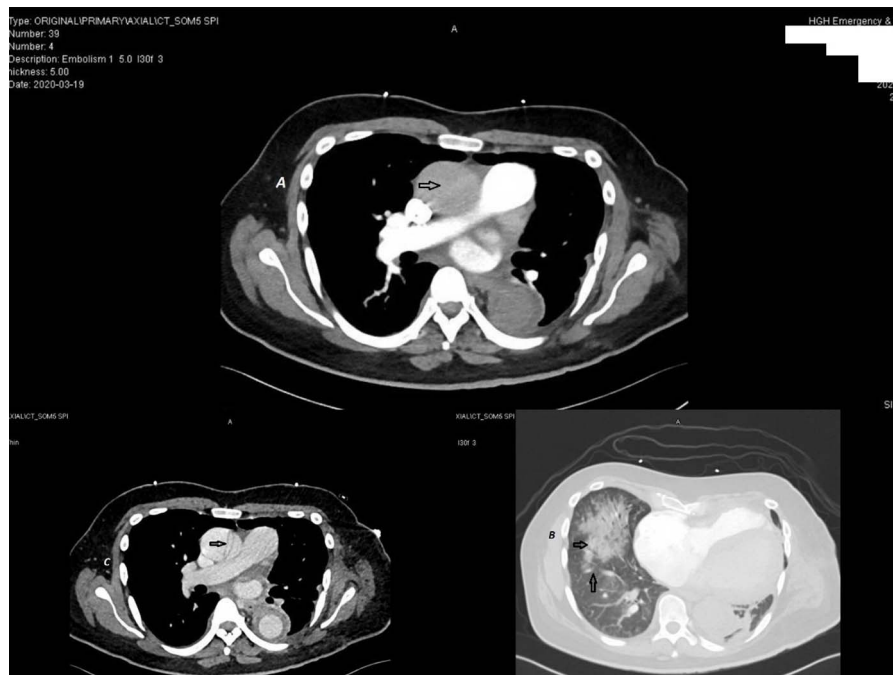The patient was managed conservatively by the cardiothoracic surgery and was monitored closely. Serial chest x-ray and CT aortogram were performed. The patient underwent elective operation (Bentall procedure) on the 25th day of admission. He remained stable after the procedure and was discharged. He is currently being followed up with the cardiology, cardiothoracic, and vascular surgery in outpatient clinics (last seen on 31 August 2020).

**Table 3. COVID-19 testing**

COVID-19	21st March 2020	22nd March 2020	18th April 2020
Nasopharyngeal and throat swab - PCR	Negative	Negative	Negative



**Figure 1. Chest x-ray. (A) Chest x-ray done on 19 March 2020 showing a nonhomogenous opacity in the right lower lung. (B) Chest x-ray done on 6 October 2019 showing opacity at the cardiac region, suggestive of aneurysmal dilatation of the aorta with a rim of calcification.**



**Figure 2.** (A) CTPA showing an aortic dissection involving the root of the aorta extending to the arch of the aorta and right common carotid artery. (B) CTPA showing consolidative opacities in the right middle and lower lobes, (C) ECG-gated CT thorax showing the aortic dissection arising from the root of the aorta and involving the arch of the aorta with a dissection flap extending into the common carotid artery.

## DISCUSSION

The identification and management of aortic dissection in early stages is challenging because of its diverse presentation and life-threatening mimics, including acute coronary syndrome, pulmonary embolism, and stroke [4]. Painless aortic dissection is one of the clinical variants of aortic dissection, which is more common in Stanford type A. According to the International Registry of Acute Aortic Dissection (IRAD), features associated with painless aortic dissection include syncope (33.9%), new-onset neurological deficit (23.7%), stroke, congestive heart failure (19.7%), coma or spinal cord ischemia (17.0%), acute renal failure (13.6%), myocardial infarction (7.1%), and mesenteric ischemia or infarction (6.8%) [5]. In this case, the patient presented with cough and SOB with infiltrates in chest x-ray, making COVID-19 as one of the most preferred differential diagnosis. In the COVID-19 pandemic, a couple of factors have been hypothesized to increase the mortality of aortic dissection, including patients' fear of contracting COVID-19 and delayed presentation to the emergency department, super-saturated emergency departments, and delayed transfer by the EMS [6], but atypical cases of aortic dissection delayed due to

overlapping COVID-19 features are rarely reported. Hemoptysis as an only sign of thoracic aortic dissection is extremely rare though in this case patient complained of minimal hemoptysis [7].

Handover in the emergency department is critical, playing a dynamic role in patient care; any lack of information can lead to compromise in quality of care provided [8]. High clinical suspicion of COVID-19 based on suggestive history and findings along with painless presentation contributed to the difficulty in diagnosing AAD in the first place, and missing information during handover resulted in further delayed involvement of cardiothoracic surgery. Anchoring to the information received is important, but re-evaluating and going through details closely is also vital to avoid any anchoring bias that could have happened in this case, but systematic approach and multidisciplinary practice led to diagnosis of AAD.

It is plausible that current literature highlights the effectiveness and necessity to divide the emergency department into clean and nonclean pathways during this evolving pandemic; the patient should be triaged according to the presence of respiratory symptoms, including cough, fever, and chest x-ray findings as well as arterial blood gas, before the patient is sent to

the emergency physician [9]. In this manner, if we consider the abovementioned case, it was triaged efficiently but deviated the emergency physicians from one of the life-threatening disease diagnoses.

## CONCLUSION

The COVID-19 pandemic has changed medical practices worldwide and has put severe stress on the healthcare. In this phase of adaptation, life-threatening diseases need special attention and care. Since aortic dissection is one of the life-threatening diseases with multiple variants, special attention must be given to atypical presentation, evolving triage criteria, and overlapping COVID-19 features which can further complicate and delay early identification and management. Therefore, further research and close observation are needed to identify and investigate related factors causing increased morbidity and mortality in the COVID-19 pandemic. We suggest objective handover method, including checklist and allocated time slot in between changing shifts to optimize the quality of patient care.

## Patient's perspective

According to the conversation with the patient, he was initially worried and anxious since he was facing two risks at the same time, COVID-19 and aortic dissection, both with serious outcomes. He said that he was afraid of getting operated as well in the beginning, feeling that he was not ready. In the discussion with emergency physicians, he was given

detailed information and possible treatment options. With each negative nasopharyngeal and throat swab, he felt at ease, but at the same time, he felt like the clock is ticking for aortic dissection. He understood surgical intervention is a definitive treatment with its possible risks gradually with discussions. COVID-19 is a major source of stress and anxiety during this whole time for him. But now, he is satisfied with the treatment and management protocol.

## COMPETING INTEREST

There are no competing interests to be declared in this case report.

## FUNDING SOURCES

There are no funding sources for this case report.

## Authors' contributions

Tahir Shahzad – participated in the conceptualization, literature search, draft formatting, manuscript writing, data search, proofreading of the manuscript, critical revision of content, and final approval

Mulham Mohamed – participated in data search, critical revision of the content, and final approval

Zain Ali – participated in literature search, manuscript writing, formatting, proofreading, and final approval

Tim Richard – participated in design, critical revision of the content, and final approval.

All authors read and approved the final manuscript.

## REFERENCES

- Hagan PG, Nienaber CA, Isselbacher EM, et al. The International Registry of Acute Aortic Dissection (IRAD): New insights into an old disease. – *JAMA*. 2000;283(7):897–903. doi:10.1001/jama.283.7.897.
- Tsai TT, Nienaber CA, Eagle KA. Acute aortic syndromes. *Circulation* 2005;112:3802–13.
- WHO Coronavirus Disease (COVID-19) Dashboard. (n.d.). [cited 18 Aug 2020], Available from: <https://covid19.who.int>.
- Kadamba AK, Verma A, Sheikh WR, Haldar M, Snehya A, Jaiswal S. Painless acute aortic dissection presenting to the emergency department. *J Case Reports*. 2019;9(2):100–2. doi:10.17659/01.2019.002.
- Pape LA, Awais M, Woznicki EM, et al. Presentation, diagnosis, and outcomes of acute aortic dissection: 17-year trends from the international registry of acute aortic dissection. *J Am Coll Cardiol*. 2015;66(4):350–358. doi: 10.1016/j.jacc.2015.05.029.
- El-Hamamsy I, Brinster DR, DeRose JJ, et al. The COVID-19 pandemic and acute aortic dissections in New York: A matter of public health. *J Am Coll Cardiol*. 2020;76(2):227–229.
- Chen MH, Rajmane R. A rare life-threatening cause of hemoptysis: Aortic aneurysm dissection. *Chest*. 2013;144(4):337A.
- Reimer AP, Alfes CM, Rowe AS, Rodriguez-Fox BM. Emergency Patient Handoffs: Identifying Essential Elements and Developing an Evidence-Based Training Tool. *J Contin Educ Nurs*. 2018; 49(1): 34–41. Available online: <https://www.healio.com/nursing/journals/jcen/2018-1-49-1/%>

[7Be58bcf3c-ba0d-4baf-bada-db4595dde8e0%7D/emergency-patient-handoffs-identifying-essential-elements-and-developing-an-evidence-based-training-tool](#)

9. Coen D, Paolillo C, Cavazza M, et al. Changing Emergency Department and hospital organization in response to a changing epidemic. *Emerg Care J.* 2020;16(1). doi: 10.4081/ecj.2020.8969.