



Case illustrated

Myonecrosis secondary to COVID-19-related deep vein thrombosis



Angelo Dante de Carvalho Corrêa^{a,*}, Diogo Goulart Corrêa^b, Clarissa Canella^{b,c},
Rafael Ferracini Cabral^{a,b}, Elizabeth Figueiredo Salles^a, Flavia Martins Costa^{a,b}

^a Department of Diagnostic Radiology, Clementino Fraga Filho University Hospital, Federal University of Rio de Janeiro, Rua Professor Rodolpho Paulo Rocco, 255, Cidade Universitária, Rio de Janeiro, RJ, 21941-901, Brazil

^b Clínica de Diagnóstico por Imagem (CDPI) / DASA, Avenida das Américas, 4666, 302A, Barra da Tijuca, Rio de Janeiro, RJ, 22640-902, Brazil

^c Department of Radiology, Fluminense Federal University, Rua Marquês do Paraná, 303, Centro, Niterói, RJ, 24033-900, Brazil

ARTICLE INFO

Article history:

Received 14 May 2021

Received in revised form 18 May 2021

Accepted 18 May 2021

A 46-year-old previously healthy woman presented to the emergency department with flu-like symptoms, rapidly evolving to respiratory failure requiring mechanical ventilation. The Severe Acute Respiratory Syndrome coronavirus-2 (SARS-CoV-2) polymerase chain reaction testing from a nasopharyngeal swab was positive, chest computed tomography showed typical findings of coronavirus disease-2019 (COVID-19), affecting 75 % of the lung parenchyma, and the serum D-dimer was 1008 ng/mL. After one week, the patient progressively improved the respiratory condition and was extubated. A few days later, she developed severe acute pain, functional limitation and swelling of the left leg. The serum D-dimer raised to 5882 ng/mL. Creatine phosphokinase (CPK) was 431 IU/L.

Color Doppler ultrasound and magnetic resonance imaging (MRI) showed an acute thrombus in the posterior tibial and soleal veins. The MRI also demonstrated edema, with peripheral gadolinium-enhancement in the fibular muscles, associated with fascia bulging, suggesting myonecrosis. A follow-up MRI, performed one month later, confirmed the diagnosis, showing

reduced muscle volume and incipient distal atrophy of the lateral leg compartment (Fig. 1), confirming the diagnosis of myonecrosis. Because of the fascia bulging in the baseline MRI, the diagnosis of segmental compartment syndrome was considered. However, due to the limited area of involvement, conservative treatment with anticoagulation was chosen. The patient evolved well, with almost complete recovery from functional deficit, and was discharged for outpatient follow-up.

COVID-19 is related to a considerably increased risk of thromboembolic events, both arterial and venous [1], but musculoskeletal involvement is much more infrequent [2]. Myonecrosis secondary to deep vein thrombosis is a very rare and potentially serious consequence, which may or may not be related to compartment syndrome [3]. Its early diagnosis and treatment can lead to a better clinical outcome and should be considered when suggestive signs, symptoms and imaging findings are present. To the best of our knowledge, this is the first reported case of muscle necrosis secondary to COVID-19-related deep vein thrombosis.

* Corresponding author.

E-mail address: dante.angelo@gmail.com (A.D.d.C. Corrêa).

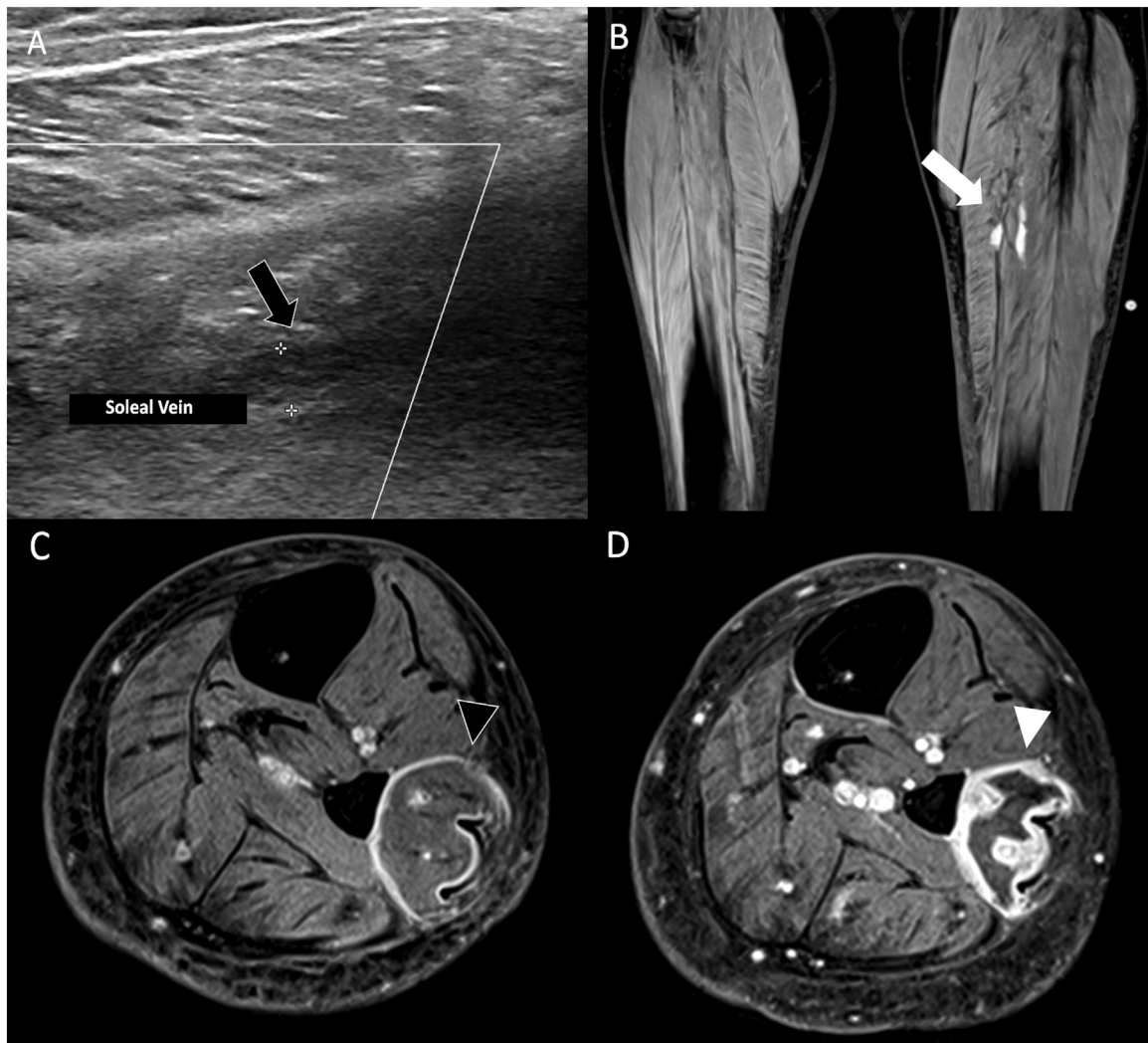


Fig. 1. Myonecrosis secondary to deep vein thrombosis. (A) Color Doppler ultrasound showing thrombosis without recanalization of the soleal vein (black arrow). (B and C) Baseline MRI demonstrating an acute thrombus with high signal on coronal T1-weighted imaging with fat saturation, in the posterior tibial and soleal veins, compatible with acute thrombosis (white arrow), as well as an area of muscular bulging, associated with peripheral contrast-enhancement in the corresponding muscle, on axial T1-weighted imaging with fat saturation, after intravenous gadolinium injection (black arrowhead). (D) Follow-up MRI, performed 1 month after the initial scan, showed a decrease in the muscle volume, loss of definition of the muscle fibers and persistence of the peripheral contrast-enhancement (white arrowhead), compatible with myonecrosis.

Conflicts of interest

None.

Funding

The authors received no financial support for the publication of this article.

Consent

Written informed consent was obtained from the patient for publication of this case report and accompanying images. A copy of the written consent is available for review by the Editor-in-Chief of this journal on request.

Ethical approval

Ethics approval obtained from the committee of the Universidade Federal do Rio de Janeiro.

Author contribution

Angelo Dante de Carvalho: Acquisition of data; Drafting the manuscript; Approval of the version of the manuscript to be published.

Diogo Goulart Corrêa - Conception and design of study; Drafting the manuscript; Approval of the version of the manuscript to be published.

Clarissa Canella - Conception and design of study; Revising the manuscript critically for important intellectual content; Approval of the version of the manuscript to be published.

Rafael Ferracini Cabral - Analysis and interpretation of data; Revising the manuscript critically for important intellectual content; Approval of the version of the manuscript to be published.

Elizabeth Figueiredo Salles - Acquisition, analysis and interpretation of data; Revising the manuscript critically for important intellectual content; Approval of the version of the manuscript to be published.

Flavia Martins Costa - Analysis and interpretation of data; Revising the manuscript critically for important

intellectual content; Approval of the version of the manuscript to be published.

References

- [1] Ortega-Paz L, Capodanno D, Montalescot G, Angiolillo DJ. Coronavirus disease 2019-associated thrombosis and coagulopathy: review of the pathophysiological characteristics and implications for antithrombotic management. *J Am Heart Assoc* 2021;10(3):1–24, doi:<http://dx.doi.org/10.1161/JAHA.120.019650>.
- [2] Ramani SL, Samet J, Franz CK, et al. Musculoskeletal involvement of COVID-19: review of imaging. *Skeletal Radiol* 2021, doi:<http://dx.doi.org/10.1007/s00256-021-03734-03737> online first.
- [3] Mortensen SJ, Zhang D, Mohamadi A, et al. Predicting factors of muscle necrosis in acute compartment syndrome of the lower extremity. *Injury* 2020;51(2):522–6, doi:<http://dx.doi.org/10.1016/j.injury.2019.11.022>.