

A case of successful radiofrequency ablation of an epicardial conduction breakthrough site probably via the septopulmonary bundle



Yasuhiro Yokoyama, MD, Takashi Yamamoto, MD, Tomoko Takahashi, MD, Hiroki Arase, MD, Kozue Ogasawara, MD, Akiyoshi Kakutani, MD

From the Department of Cardiology, Yoshinogawa Medical Center, Yoshinogawa, Japan.

Introduction

Catheter ablation (CA) of atrial fibrillation (AF) has become widely accepted and has become an effective alternative to drug therapy. Pulmonary vein isolation (PVI) is the cornerstone of the CA of AF.¹ Further, the posterior wall (PW) of the left atrium (LA) plays a role in the initiation and maintenance of AF. Therefore, a posterior wall isolation (PWI) may be helpful in patients in whom a PVI alone fails.² However, a complete PWI can be technically challenging. Gaps along the roof line are not rare. Recent reports have shown that a spared epicardial fiber can bypass a roof line despite a substantial endocardial ablation.^{3,4} One factor making the PWI challenging is the septopulmonary bundle (SPB), which runs vertically along the PW.⁵ Here, we present a case of a successful PWI in a patient with an endocardial breakthrough site of the epicardial conduction.

Case report

A 78-year-old female patient was referred to our hospital for CA of symptomatic persistent AF. Her arrhythmia had lasted for about 6 months. The ablation strategy was a PVI and box lesion set, which was created by the addition of a roof line connecting the superior pulmonary veins (PVs) and a floor line connecting the inferior PVs. The procedure was performed under conscious sedation using a CARTO3 navigation system (Biosense Webster, Diamond Bar, CA). A point-by-point antral isolation of all PVs was performed using a bidirectional 3.5 mm open-irrigated catheter (ThermoCool SmartTouch; Biosense Webster, Diamond Bar, CA) and multipolar mapping catheter (PentaRay; Biosense

Webster, Diamond Bar, CA). A circumferential PV isolation was performed with radiofrequency (RF) energy (a power of 40 W on the anterior wall, 35 W on the PW, and 30–35 W near the esophagus). The contact force of the ablation catheter tip and vector of the force were depicted on the CARTO map in a real-time manner. During the RF energy application, the ablation index was monitored continuously by gradual coloring of the tag from white to pink and then to red, as shown by the VISITAG module (Biosense Webster, Diamond Bar, CA). We set the ideal contact force at 10g during the application, and the ablation index was set at 450 (anterior) or 400 (posterior and near the esophagus). The PVI procedure was easily performed. We confirmed the absence of the local electrograms in the PVs and exit block during pacing in the PVs. After the PVI, a roof line was added. We confirmed the completion of the block line by the electrogram sequence on the PW during pacing from the anterior LA. Further, we added a floor line and created a box isolation. The local electrical potentials on the PW were absent after the box isolation (Figure 1A). However, pacing within the box at 6.0 V / 2.0 ms partially captured the atrium, and an output of 9.9 V / 2.0 ms constantly captured it. When the pacing was decreasing from 9.9 V / 2.0 ms to 6.0 V / 2.0 ms again, it transitioned to noncapture (Figure 1B). At that point we determined that the PWI was incomplete. LA mapping was performed by a multipolar catheter during constant pacing within the box and an activation map was obtained. The local activation time map with conduction velocity vectors showed what seemed to be a focal pattern on the LA wall (Figure 2). RF applications were delivered at the earliest site, then exit block during high-output pacing was obtained. That demonstrated bidirectional block and that the PWI was completed.

KEYWORDS Atrial fibrillation; Catheter ablation; Epicardial conduction; Line ablation; Septopulmonary bundle
(Heart Rhythm Case Reports 2021;7:825–828)

Conflict of interest: All authors declare that there is no conflict of interest.
Funding: This research did not receive any specific grant from funding agencies in the public, commercial, or not-for-profit sectors. **Address reprint requests and correspondence:** Dr Yasuhiro Yokoyama, Department of Cardiovascular Medicine, Yoshinogawa Medical Center, 120 Chiejima aza Nishichiejima Kamojima-cho, Yoshinogawa, 776-8511, Japan. E-mail address: yshr.yokoyama@gmail.com.

Discussion

The posterior LA plays a critical role in the initiation and maintenance of AF. Further, a PWI may be helpful in patients in whom a PVI alone fails and in those with persistent AF.² However, it can be technically challenging to complete the PWI. Gaps along the roof line are not rare. Those incomplete

KEY TEACHING POINTS

- Electrical isolation of the posterior left atrial wall from the endocardial side is sometimes challenging owing to epicardial conduction.
- The left atrium is a thin structure; however, there are epicardial fiber connections.
- The septopulmonary bundle (SPB) runs vertically along the posterior wall of the left atrium. The endocardial breakthrough site of the SPB may be a potential therapeutic option to overcome the challenges of achieving a posterior wall isolation.

isolation cases require additional ablation within the line to complete the isolation.⁶ Recent reports have shown that spared epicardial fibers can bypass a roof line despite substantial endocardial ablation.^{3,4} One factor gaining attention for making the PWI challenging is the epicardial fibers such as the SPB that travel vertically along the PW of the LA.⁵ Knol and colleagues⁷ have systematically investigated the epicardial interatrial conduction during cardiac surgery and its morphologic structures on cadaveric hearts. The detailed anatomy of the Bachmann bundle, the posterosuperior bundle, and the SPB has been described. The SPB originates from deep in the interatrial groove, from under the Bachmann bundle, and the posterosuperior bundle passes the right superior pulmonary vein anteriorly, then to the roof of the LA. Further, it continues in a longitudinal

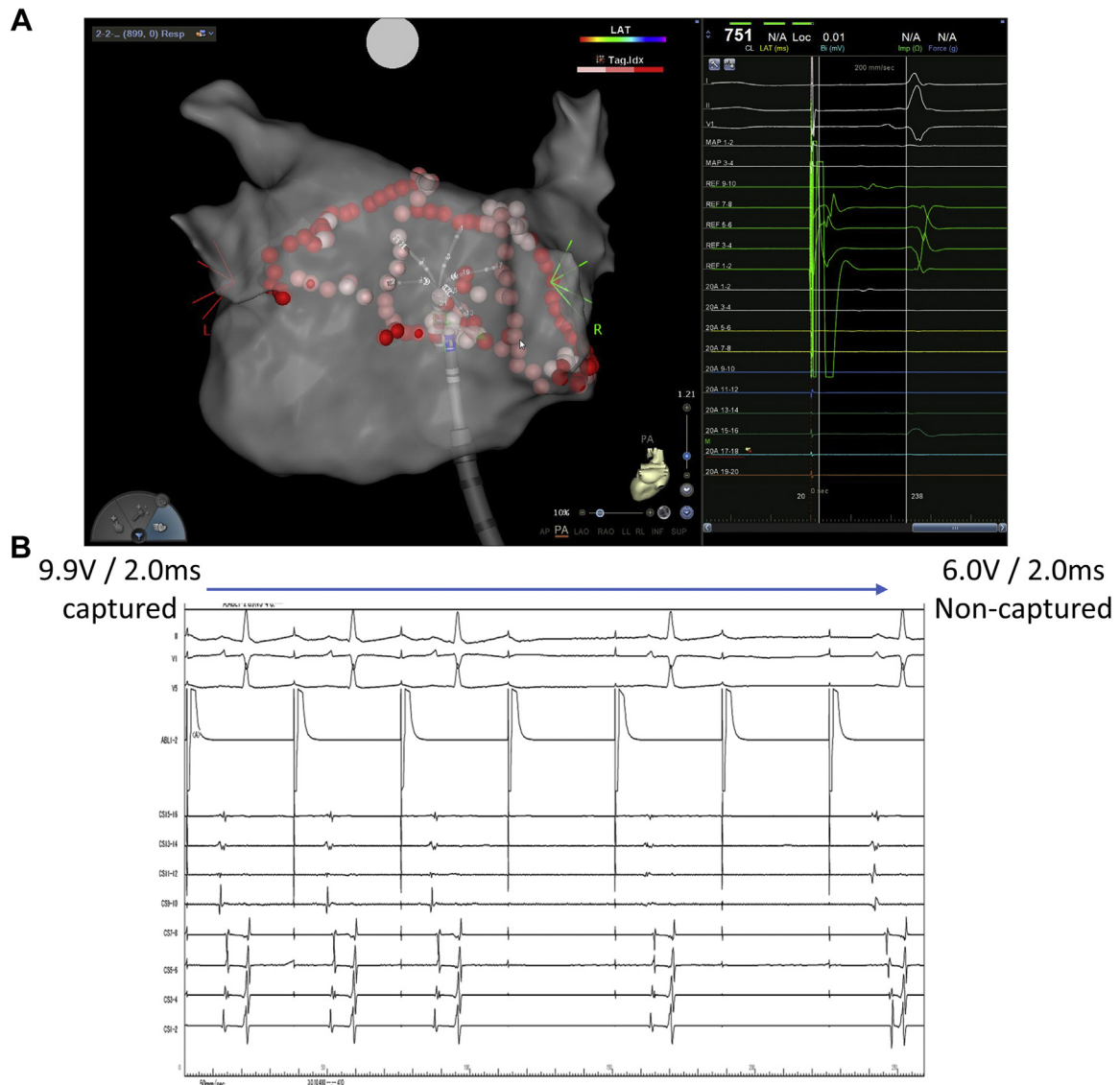


Figure 1 **A:** After a box isolation, the local electrical potentials on the posterior wall disappeared during coronary sinus distal pacing. **B:** When the pacing on the left atrial posterior wall was decreased from 9.9 V / 2.0 ms to 6.0 V / 2.0 ms, the constant atrial capture transitioned to noncapture.

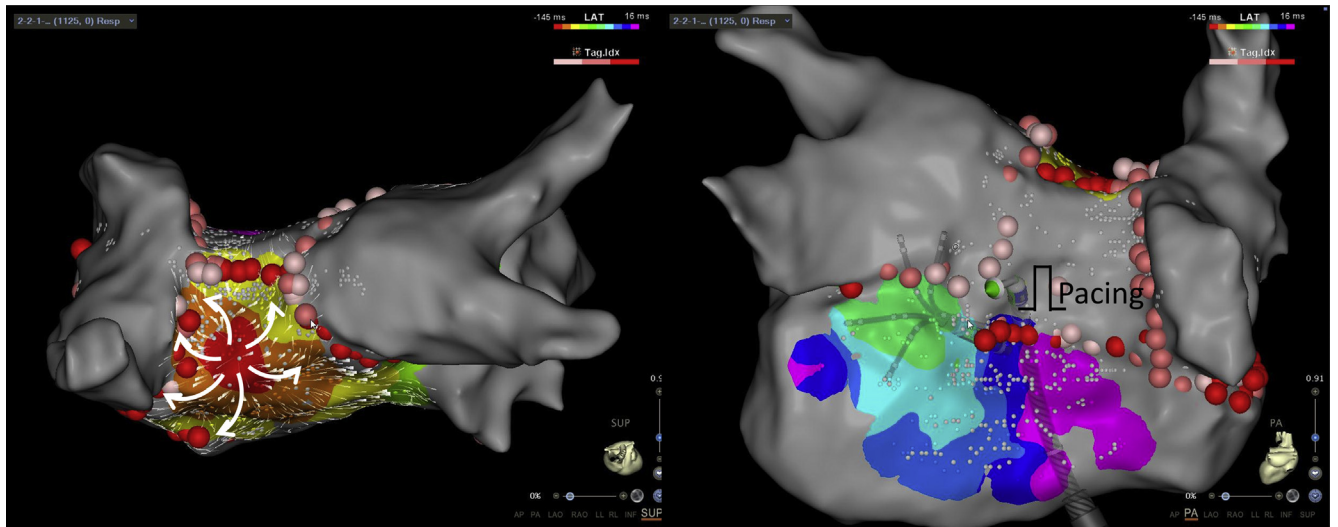


Figure 2 The activation map was performed with the PentaRay catheter (Biosense Webster, Diamond Bar, CA) during high-output pacing (9.9 V and 2.0 ms) with the ablation catheter within the box. The local activation time (LAT) map with conduction velocity vectors exhibited a focal endocardial breakthrough pattern. The earliest site was far from either line.

direction, bending posterior and passing in between the inferior PVs to the PW. The bundle then diverges to the right and left, intermingling with the circumferential fibers coming from the lateral wall.⁷ Further, the bundle of fibers are arranged deeper than the SPB and form the subendocardium, which is described as the septoatrial bundle. This bundle arises from the anterior interatrial raphe, ascends obliquely, and combines with the longitudinal fibers from the anterior vestibule to pass between the left and right PVs on the PW.⁸ This bilayer LA architecture has been consistently reported.^{4,9}

In this case, an additional line ablation resulted in the elimination of the local electrical potentials and bidirectional

block with normal output pacing on the PW. However, high output pacing within the box led to atrial capture. It was determined that only limited unidirectional conduction was present, and the block line was incomplete. The earliest site during the pacing within the box was far from either line. These findings demonstrated that conduction may continue to occur on the epicardium rather than subendocardium, such as with the septoatrial bundle, and that the earliest site was adjacent to the breakthrough site. A past report revealed a focal breakthrough pattern in the middle of the box lesion, which was via the SPB.⁵ Our case was considered to involve a focal breakthrough pattern on the anterior LA wall via the SPB (Figure 3). Detailed mapping during pacing within the box allowed us to locate the endocardial breakthrough site via the SPB. This method may be a potential therapeutic option for overcoming a challenging PWI.

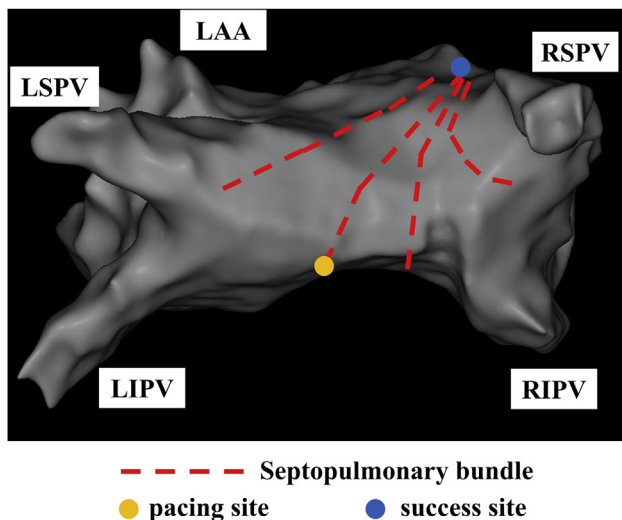


Figure 3 An assumed image from this case is shown. It shows the positional relationship between the septopulmonary bundle and successful site, as referred to in references 4, 5, and 7. LIPV = left inferior pulmonary vein; LSPV = left superior pulmonary vein; RIPV = right inferior pulmonary vein; RSPV = right superior pulmonary vein.

Conclusion

This case suggested a curable ablation procedure with the elimination of the endocardial breakthrough site of the epicardial conduction, probably via the SPB, to complete the PWI.

Acknowledgments

We are grateful to Mr John Martin for his help in the preparation of the manuscript and thank Yuki Akagawa and Youichi Oguri of the Clinical Engineering department for their assistance in the electrophysiological study.

References

1. Calkins H, Hindricks G, Cappato R, et al. 2017 HRS/EHRA/ECAS/APHS/SOL-AECE expert consensus statement on catheter and surgical ablation of atrial fibrillation. *Europace* 2018;20:e1–e160.
2. Tahir KS, Mounsey JP, Hummel JP. Posterior wall isolation in atrial fibrillation ablation. *J Innov Card Rhythm Manag* 2018;9:3186–3194.

3. Piorowski C, Kronborg M, Hourdain J, et al. Endo-/epicardial catheter ablation of atrial fibrillation: feasibility, outcome, and insights into arrhythmia mechanisms. *Circ Arrhythm Electrophysiol* 2018;11:e005748.
4. Garcia F, Enriquez A, Arroyo A, Supple G, Marchlinski F, Saenz L. Roof-dependent atrial flutter with an epicardial component: role of the septopulmonary bundle. *J Cardiovasc Electrophysiol* 2019;30:1159–1163.
5. Tung R. Percutaneous epicardial ablation of atrial fibrillation. *Card Electrophysiol Clin* 2020;12:371–381.
6. Thomas SP, Lim TW, McCall R, Seow SC, Ross DL. Electrical isolation of the posterior left atrial wall and pulmonary veins for atrial fibrillation: feasibility of and rationale for a single-ring approach. *Heart Rhythm* 2007;4:722–730.
7. Knol WG, Teuwen CP, Kleinrensink GJ, Bogers A, de Groot NMS, Taverne Y. The Bachmann bundle and interatrial conduction: comparing atrial morphology to electrical activity. *Heart Rhythm* 2019;16:606–614.
8. Ho SY, Sánchez-Quintana D. The importance of atrial structure and fibers. *Clin Anat* 2009;22:52–63.
9. Cabrera JA, Ho SY, Climent V, Sánchez-Quintana D. The architecture of the left lateral atrial wall: a particular anatomic region with implications for ablation of atrial fibrillation. *Eur Heart J* 2008;29:356–362.