

Case Report

Pulmonary sequestration: A rare case in a patient with acute chest pain and palpitation mimicking the acute coronary syndrome

Rahim Mahmudlou, Nariman Sepehrvand¹, Sanaz Hatami¹

Department of Surgery, ¹Students' Research Committee, Urmia University of Medical Sciences, Urmia, Iran

ABSTRACT

Pulmonary sequestration (PS), a non-functioning lung tissue, which lacks the normal communication with the tracheobronchial tree and receives the blood supply from the systemic circulation, is a rare congenital malformation that comprises 0.5-6% of all congenital pulmonary malformations. The presentation of PS with chest pain is very rare. In this article, we are aimed to report the case of a patient with chief complaints of retrosternal chest pain and palpitation, which was suspected to be of cardiac origin. Primary evaluations including exercise tolerance test, 48-hour holter monitoring, coronary angiography ruled out any cardiac problem. Further evaluations with Thoracic CT scan revealed a cystic mass in the retrocardiac region of the lung. Thoracotomy surgery was done and the patient was finally diagnosed to be extralobar pulmonary sequestration.

KEY WORDS: Chest pain, extralobar, pulmonary sequestration, tachycardia

Address for correspondence: Nariman Sepehrvand, M.D, Research Fellow, Students' Research Committee, Urmia University of Medical Sciences, Resalat Avenue, Djahad Square, Urmia, Iran. E-mail: nariman256@gmail.com

INTRODUCTION

Pulmonary sequestration is a rare anomaly of the lung, which in fact is a non-functioning lung tissue that lacks any communication with tracheobronchial tree and receives all or most of its blood supply from the aberrant systemic vessels.^[1] It classifies into two major groups: Intralobar (ILS) versus extralobar (ELS) pulmonary sequestrations, which in the former the sequestration tissue shares the visceral pleura of the normal lung tissue but in the latter separated from normal lung tissue by its own visceral pleura.^[2] ELS sequestrations are usually asymptomatic and accidentally discovered. Symptomatic ELS pulmonary sequestration in adults is thought to be extremely rare.^[3] Although, chest pain is reported in almost 3-11% of PS patients, but the presentation of chest pain and palpitation mimicking the acute coronary syndrome

in pulmonary sequestration is a rare phenomenon. In this article, we are reporting a case admitted to the emergency room because of chest pain, palpitation, and tachycardia, which was finally diagnosed to be ELS.

CASE REPORT

A 32-years-old non-smoker Caucasian woman from the rural areas of west Azerbaijan province of Iran was admitted with the chief complaint of chest pain and palpitation in the emergency department. The pain was retrosternal with radiation to the left shoulder. The patient had the history of frequent coronary care unit (CCU) admission due to chest pain, but previous evaluations have not revealed any cardiac problem.

Two years ago, she was hospitalized because of chest pain with the primary diagnosis of acute coronary syndrome but chest x-ray revealed a consolidation in left lower lobe in retrocardiac position, which was associated with considerable pleural effusion in subsequent x-rays. In the last radiography, the whole left pleural cavity was filled by pleural effusion. Due to high body temperature, the diagnosis of pneumonia was established and the insertion of chest tube in association with antibiotic therapy resulted in favorable outcome and the patient was

| Access this article online | |
|--|---|
| Quick Response Code:  | Website: www.lungindia.com |
| | DOI: 10.4103/0970-2113.148459 |

discharged. During these two years, the patient complained occasionally from chest pain and even admitted in CCU. In one such admission, the patient experienced a sudden sense of palpitation, in which the electrocardiographic study revealed a ventricular tachycardia rhythm [Figure 1].

In the last admission, she had some ECG (electrocardiography) findings including ST depression and inverted T-waves in V₁₋₄ precordial leads. The exercise tolerance test had no significant findings. Echocardiography was normal. Cardiac troponin-I (CTnI) was in negative range (0.01). The cardiac etiologies were ruled out by above-mentioned investigations.

Pulmonary CT angiography had not been done in order to evaluate any potential pulmonary emboli (PTE), but the d-dimer study was negative (0.1), which ruled out the PTE. The patient underwent bronchopulmonary computed tomography angiography (CTA), in which no abnormality has been visualized within the vascular tree, and only a large hypodense mass with the characteristics of a cystic lesion with the diameter of 8 cm was observed in retrocardiac region.

High Resolution CT of the lungs with IV contrast illustrated a hypodense cystic lesion with internal septation and the highest diameter of 8 cm in retrocardiac region of left lower lobe with some small air foci in its margins [Figure 2]. No pleural effusion or lymphadenopathy was seen.

Complete blood count was as following: WBC = 5380, Hb = 8.9, Plt = 280000. Blood cultures (×2) were also negative. Serologic test (ELISA) for anti-hydatidosis (echinococcus) was negative. The thyroid function tests for evaluating the cause of palpitation and tachycardia were done as well, and the results were as following: TSH = 3.6 mIU/L, T4 = 7.2 mg/dl, T3RIA = 1.3 ng/dl (euthyroid).

The spirometry revealed normal lung volumes (VC = 3.49 lit, FEV1 = 2.97 lit, FVC = 3.46 lit).

The patient was candidate for thoracotomy. Preoperatively she was treated with ceftriaxone 1gr bid and clindamycin 600 mg three times a day (TDS). Surgery was conducted under general anesthesia with double lumen endotracheal intubation. In right lateral decubitus position, posterolateral incision was done in the left hemithorax. In the lower part of the left lung, there was a pulmonary sequestration, which was supplied from an aberrant branch of the aortic artery, and had a separate venous drain [Figure 3]. In order to ligate the aberrant artery from its origin, the surgeon had to lift the heart to the right side, because instead of originating from the anterior or left lateral parts of aorta, the aberrant artery derived from the right lateral part of it and passed a long way behind the pericardium to reach the left lower lobe. The vascular pedicle was ligated and the lesion was successfully removed. The pleural cavity was drained with a 28 F chest tube, which was removed on 2nd postoperative day.

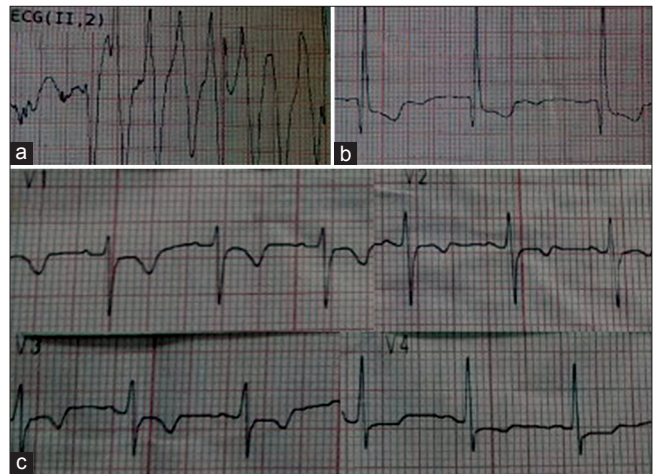


Figure 1: (a) Ventricular tachycardia in one of patient's previous admissions; (b) Post- VT at the same admission; (c) ST depressions and inverted T-waves in ECG of patient's last admission

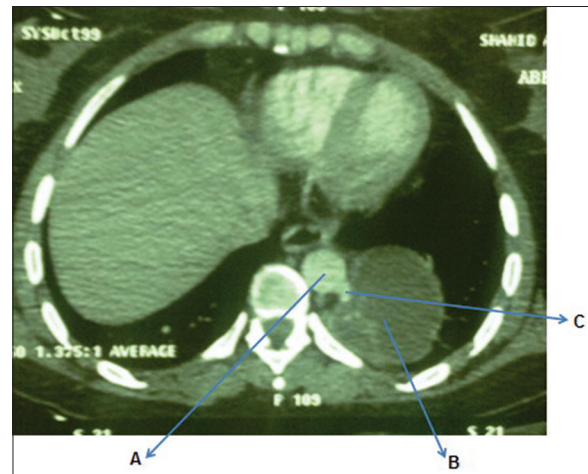


Figure 2: Thoracic computed tomographic scan of the patient: (A) descending aorta, (B) pulmonary sequestered lobe, (C) aberrant artery originated from aorta providing blood supply for sequestered lobe

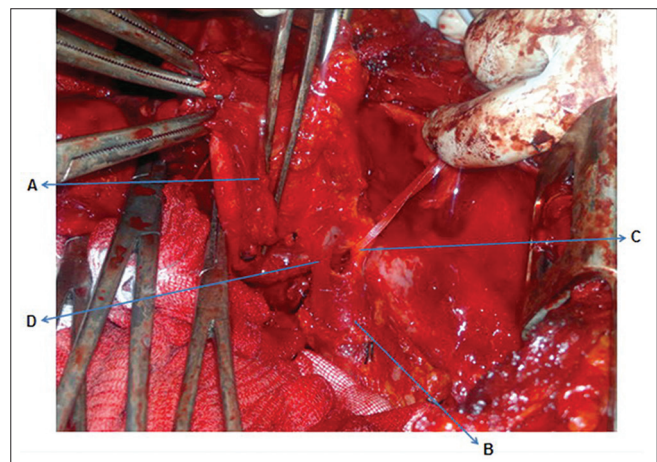


Figure 3: Intraoperative view, (A) pulmonary sequestration, (B) descending aorta, (C) aberrant artery originated from aorta, (D) venous drainage of the sequestered lobe

The postoperative period was eventless and the patient was discharged in the postoperative day eight. A six-month follow-up revealed no recurrence of the chest pain or any other complaint.

DISCUSSION

Lung malformations have an incidence rate of almost 2.2-6.6% and pulmonary sequestration comprises 1.5% of all congenital pulmonary malformations.^[4] It seems that it is a region of lung which is inadequately supplied with blood and so perfused by aberrant vessels.^[5]

According to Huang *et al.*, among 115 cases of pulmonary sequestration within the last 25 years in English literature, only 4 of them were presented with pain (located in shoulder, chest, or upper abdominal region).^[6] The association of chest pain and palpitation is rare. The retrospective review of the patient's records in Heart hospital revealed that the above-mentioned ST depressions and inverted T-waves in precordial leads were initiated after the patient experienced ventricular tachycardia in one of her admissions. The cardiac studies have not determined why the ventricular tachyarrhythmia has occurred, but the surgeon believes that it could be due to the origination of aberrant artery from an initial part of aortic artery adjacent to the ventricular wall or because of irritation of pericardium by the aberrant artery while passing the posterior surface of pericardium.

Cardiovascular complications are among the severe complications of long-term undiagnosed pulmonary sequestrations, however, in our case, the echocardiographic study, angiographic study, and exercise tolerance test (ETT) were not advocating any cardiovascular problem.

ELs are often more associated with other congenital anomalies (50%) compared to ILSs (14%).^[5] However, in our case, the ELS was not associated with any other anomaly. Gezer *et al.*, reported the rate of concurrent pulmonary and extrapulmonary malformations to be 12% of all cases.^[7] According to Pinto Filho *et al.*, and Huang *et al.*, adolescents and adults with ELS seem not to be associated with other malformations.^[4,6] This hypothesis may justify why our ELS case was not associated with other congenital anomaly as expected in the literature.

According to the study of Wei *et al.*, on 2625 pulmonary sequestration cases in China, cystic lesions were reported in 28.57% of cases and the lesion was located in the left lower lobe in 71.53% of cases. 36% were preoperatively misdiagnosed with pulmonary cysts.^[2] Only 6 of 66 ELS patients submitted to surgery in the study of Savic *et al.*, had a correct preoperative diagnosis of PS.^[5] 18% of the ELS cases were solitary cysts.

The preoperative diagnosis of our case was a pulmonary cyst as well, so it is suggested to consider this rare diagnosis in evaluation of patients with pre-surgery diagnosis of pulmonary cyst.

According to the literature, ILS sequestrations diagnosed at an earlier age compared to ELS sequestrations since they were easily acquired pulmonary infections due to having connections to tracheobronchial tree.^[2] Our case was diagnosed in an older age compared to the most of PS cases.

The answer to the question that why PS remained asymptomatic until this age of patient, may have been derived from the evidence provided by Savic *et al.*, which suggests that an extralobar sequestration increases in size up to the age of 35, after which it begins to shrink.^[5] So perhaps the increase in size of the ELS was resulted in inflammation and subsequent manifestations.

Although, the use of chest x-rays is the primary step in evaluating thoracic problems, the findings of chest x-ray and CT scans are to some extent non-specific, illustrating cystic or tumor-like lesions in the thorax. Most useful diagnostic methods for PS are conventional angiography, CTA and magnetic resonance angiography (MRA); however, considering the non-invasive nature of CTA and MRA, they are more preferable compared to conventional angiography.^[2]

In order to minimize the risk of potential complications such as obstruction, infection, etc., most of the surgeons recommended an early surgery to accelerate the return of normal pulmonary function.

A high index of suspicion is the most important element in the diagnosis of pulmonary sequestration. In our case, the patient was presented with retrosternal non-pleuritic chest pain associated with tachyarrhythmia and was admitted in a cardiac care unit, however, further evaluations and a high index of suspicion led to the final diagnosis of pulmonary sequestration.

REFERENCES

1. Lin CH, Chuang CY, Hsia JY, Lee MC, Shai SE, Yang SS, *et al.* Pulmonary sequestration-differences in diagnosis and treatment in a single institution. *J Chin Med Assoc* 2013;76:385-9.
2. Wei Y, Li F. Pulmonary sequestration: A retrospective analysis of 2625 cases in China. *Eur J Cardiothorac Surg* 2011;40:e39-42.
3. Chun EJ, Goo JM, Lee HJ, Lee CH, Im JG. Extralobar pulmonary sequestration with hemorrhagic infarction in an adult. *J Thorac Imaging* 2007;22:166-8.
4. Pinto Filho DR, Avino AJ, Brandao SL. Extralobar pulmonary sequestration with hemothorax secondary to pulmonary infarction. *J Bras Pneumol* 2009;35:99-102.
5. Savic B, Birtel FJ, Tholen W, Funke HD, Knoche R. Lung sequestration: Report of seven cases and review of 540 published cases. *Thorax* 1979;34:96-101.
6. Huang EY, Monforte HL, Shaul DB. Extralobar pulmonary sequestration presenting with torsion. *Pediatr Surg Int* 2004;20:218-20.
7. Gezer S, Tastepe I, Sirmali M, Findik G, Turut H, Kaya S, *et al.* Pulmonary sequestration: A single-institutional series composed of 27 cases. *J Thorac Cardiovasc Surg* 2007;133:955-9.

How to cite this article: Mahmodlou R, Sepehrvand N, Hatami S. Pulmonary sequestration: A rare case in a patient with acute chest pain and palpitation mimicking the acute coronary syndrome. *Lung India* 2015;32:76-8.

Source of Support: Nil, **Conflict of Interest:** None declared.