



# COVID-19 and lung ultrasound: reasons why paediatricians can support adult COVID-19 units during critical epidemiologic periods

Cristina De Rose<sup>1</sup> · Luca Pierantoni<sup>2</sup> · Danilo Buonsenso<sup>1,3,4</sup> 

Received: 14 April 2021 / Accepted: 29 April 2021 / Published online: 28 May 2021  
© Società Italiana di Ultrasonologia in Medicina e Biologia (SIUMB) 2021

Since the beginning of the SARS-CoV-2 spread outside China, several hospitals have changed their organisation to increase critical care capacity and isolation areas to COVID-19 patients as well as to generate new flows to guarantee safety and care to non-COVID-19 patients. In addition, the paediatric practice has changed completely.

SARS-CoV-2 rarely involves children, and most of the time, the paediatric COVID-19 disease is mild [1]. Moreover, parents have stopped routinely bringing their children to the hospital either because of the fear that their children might contract the infection or because of a lockdown-related drop of seasonal infectious diseases [2]. As a result, the workload of paediatricians has significantly reduced in the past few months [3], and therefore, their inclusion in COVID units should be considered by institutions.

Although not directly involved in adult care, paediatricians may play a significant role in managing COVID-19 patients for several reasons. From a clinical point of view, several common clinical scenarios can be included in COVID-19 adults that overlap with common paediatric conditions to which paediatricians, especially some categories of them, are already accustomed to their diagnosis and management (Table 1) [4, 5].

In the last few years, in several paediatric settings, lung ultrasound (LUS) has become the first-line imaging method in children evaluated for respiratory disease, allowing the

real-time diagnosis and monitoring of lung involvement [6–13]. In recent years, several studies have shown that LUS is a useful and accurate tool for detecting pneumonia in children and it may be better than chest radiography in the diagnosis of community-acquired pneumonia [6–9, 13]. Other studies have shown that LUS can be used to predict more severe pneumonia and monitor antibiotic response, and recently, different LUS patterns have been used to differentiate viral from bacterial pneumonia by defining their etiology [6, 9, 13]. Many studies have described and validated LUS scores (based mainly on vertical artefacts and sub-pleural consolidations) in neonatal respiratory disorders [10] and bronchiolitis. [11, 12].

Over the years, the development of LUS studies on the paediatric population and the use of LUS in paediatric clinical practice have become fundamental in references to studies performed on adults [14, 15], hence the translation of knowledge acquired from these studies in the clinical paediatric practice. However, true collaboration between paediatric and adult specialists is also fundamental, especially in the interpretation of some ultrasound findings, such as in the cases of vertical artefacts and ultrasound interstitial syndrome [7, 14, 15].

Since the outbreak of the pandemic, this sharing/collaboration of experiences and studies has assumed a greater force that takes shape every day in the fight against COVID-19. In particular, it is not a coincidence that of all medical professionals, a paediatrician not only suggested that the medical community use ultrasound more frequently in suspected COVID-19 patients but also described the first case of COVID-19 (an adult patient), diagnosed and managed with thoracic ultrasound [16–18].

Since then, LUS has played a key role in the management of patients with COVID-19 pneumonia. More importantly, the ultrasound patterns of viral pneumonia and bronchiolitis in children are similar to those seen in COVID-19 pneumonia patients (e.g. pleural line irregularities and vertical artefacts (B-lines) with patchy distribution, sub-pleural

✉ Danilo Buonsenso  
danilobuonsenso@gmail.com

<sup>1</sup> Department of Woman and Child Health and Public Health, Fondazione Policlinico Universitario A. Gemelli IRCCS, Rome, Italy

<sup>2</sup> Pediatric Emergency Unit, S. Orsola University Hospital, Bologna, Italy

<sup>3</sup> Global Health Research Center, Università Cattolica del Sacro Cuore, Roma, Italia

<sup>4</sup> Istituto Di Microbiologia, Università Cattolica del Sacro Cuore, Roma, Italia

**Table 1** List of common clinical scenarios in COVID-19 adults that overlap with common pediatric conditions

COVID-19 patients	Pediatric practice
<b>Brain and nervous system</b> Encephalitis–Seizures–Loss of Consciousness	Viral encephalitis Epileptiform syndromes Brain tumors
<b>Heart and cardiovascular system</b> (possibly direct attack by virus–lack of oxygen caused by acute respiratory failure–blood vessel constriction from infection or caused by systemic inflammation) Acute Cardiac Injury Arrhythmias	Myocarditis/Pericarditis (by infectious, autoimmune, toxic causes) Congenital Heart disease  Supraventricular tachycardia–Wolff-Parkinson-White syndrome (WPW syndrome)–Long Q-T Syndrome (LQTS)
Inflammation in the blood vessels	Kawasaki disease Infectious and autoimmune vasculitis
Blood Clots Disseminated Intravascular Coagulation (DIC)–Deep vein thrombosis (DVT)–Pulmonary embolism- Arteriosus thrombosis	DIC caused by septic shock Teens with risks factors as smoking, oral contraceptive, obesity Genetic conditions which caused thrombophilia (Factor V Leiden, Prothrombin gene mutation, or deficiencies of protein C, protein S, or antithrombin) Chronic inflammation or rheumatologic and autoimmune disorders (antiphospholipid antibody syndrome) Trauma
<b>Lungs and respiratory system</b> Pneumonia–Acute Respiratory Distress Syndrome Acute Respiratory Failure	Viral respiratory disorders Atypical Bacterial Pneumonia Bacterial Pleuropneumonia Bronchiolitis Asthma Pulmonary Hypertension–Pulmonary edema Respiratory disease in Neuromuscular Disorders
Respiratory support	High-flow nasal oxygen–CPAP–Endotracheal intubation performed by pediatricians of pediatric ICU and emergency department
Lung ultrasound	Used in common clinical practice by pediatricians for diagnosis, follow-up of acute and chronic respiratory diseases and their complications
<b>Gastrointestinal system (GUT)</b> (possibly from direct attack by virus on intestinal tissues or exacerbations of underlying GUT conditions) Diarrhea Gastroesophageal ulcers Colitis	Diarrhea (infectious, toxic, autoimmune causes) Gastroesophageal reflux disease (GERD) Exacerbations of Inflammatory bowel disease (IBD)
Nutritional management–Parenteral and enteral nutrition in patients with endotracheal intubation	Parenteral and enteral nutrition in children with neuromuscular and cognitive disabilities
<b>Liver</b> (possibly from a direct attack by virus or underlying predisposing conditions or experimental hepatotoxic drugs) Acute Liver Injury/ Hepatitis	Viral and bacterial infections–Hepatitis from toxic substances and drugs–Metabolic diseases–Autoimmune diseases–Hematological and vascular diseases
<b>Kidneys</b> (possibly from a direct attack by virus or underlying predisposing conditions or ventilator use or experimental drug or septic shock or rhabdomyolysis) Acute Kidney Injury	Pre-renal injury from blood loss, surgery or shock Post-renal from a blockage in the urinary tract Intoxications or medications Hemolytic uremic syndrome Glomerulonephritis Advanced stage of chronic kidney disease: Alport syndrome, nephrotic syndrome, polycystic kidney disease
<b>Systemic inflammation</b> (caused by cytokine storm) Macrophage Activation Syndrome-Like Disease Pediatric multisystem inflammatory syndrome (PMIS)	Primary haemophagocytic lymphohistocytosis (HLH) Secondary haemophagocytic lymphohistocytosis (malignant and non-malignant diseases as viral infections, rheumatologic and autoimmune disease)
<b>Use of biological drugs</b> Anti Interleukin-6 drugs	Commonly used in pediatric clinical practice in rheumatological, autoimmune and neoplastic diseases

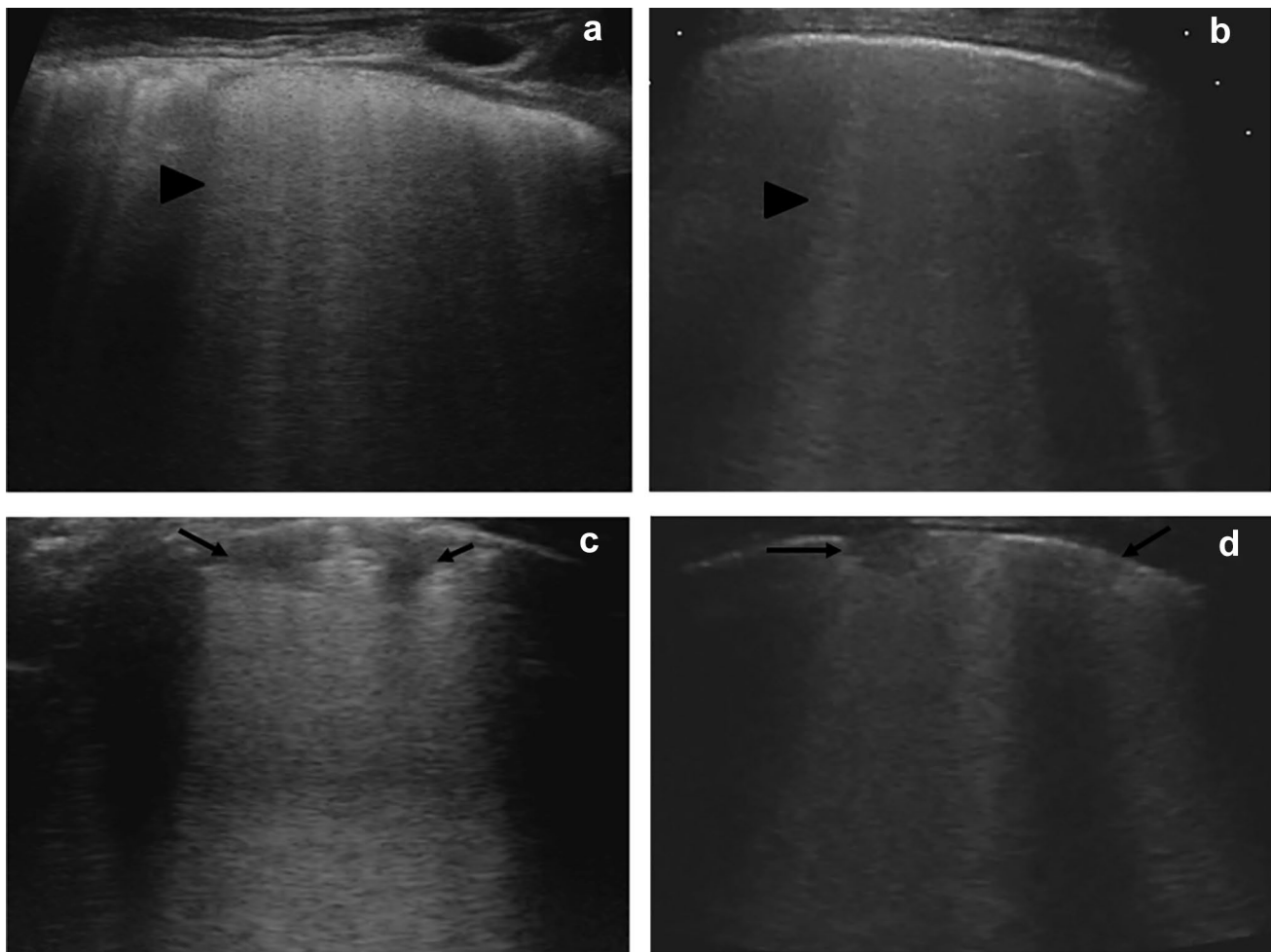
Pediatricians routinely take care of patients with viral conditions and acute respiratory distress (e.g. bronchiolitis, asthma) and that's why are confident in diagnosis and treatment. The usual management of these situations provides expertise in blood-gas analysis evaluation and in the use of devices for respiratory support, such as high-flow nasal cannula and continuous positive airway pressure (CPAP). In addition, recent evidence is pointing out that adult COVID-19 resembles systemic inflammatory syndromes [4] and pediatricians are not new to such conditions. For instance, Kawasaki disease is one of the most common systemic conditions in children and, not rarely, biological agents are required to treat it, not to mention the new identity of pediatric inflammatory multisystem syndrome temporally associated with COVID-19 (PIMS-TS) [5]. Similarly, macrophage activation syndromes, as well as other rheumatologic conditions, do occur in secondary and tertiary level settings increasingly requiring pediatricians to be trained in managing biological agents.

consolidations, and white lung areas), making it easier for paediatricians to detect pathological LUS patterns in adults with COVID-19 (Fig. 1). In general, the basic LUS semiotics of COVID-19 pneumonia does not differ between adults and children [19–21].

To allow the comparison of the severity of COVID-19 pneumonia in different patients, limiting the subjectivity and operator dependence of the exam as well as standardising the ultrasound semiotics of COVID-19 pneumonia and the LUS score of severity of COVID-19 pneumonia have been proposed; moreover, a paediatrician (DB) actively participated in the drafting of this research [19, 20] Although paediatricians could face several obstacles while dealing with adult

patients, their tendency to manage complex patients with multi-systemic diseases and poly-pharmacological therapies gives them an important source of strength to contribute to the management of adult COVID-19 patients. All these strengths could also help to reduce the anxiety, stress, and uncertainty of doctors who find themselves working in relatively unfamiliar fields.

On the other hand, a major barrier could be represented by medico-legal concerns as common comorbidities and complications of adult patients are far from those in daily paediatric practice. A safe and effective strategy for COVID wards could be, once again, a multidisciplinary team. Close collaboration between paediatricians and



**Fig. 1** Lung ultrasound findings in children with viral lower respiratory tract infection (**a**, **c**) and in a woman with COVID-19 pneumonia (**a**, **d**), performed by the same paediatrician. **a** Lung ultrasound images of a 4-year-old boy with viral pneumonia—caused by coronavirus (non-COVID-19), bocavirus, and metapneumovirus coinfection—requiring respiratory assistance with high-flow nasal oxygen at the paediatric department; the lung ultrasound shows areas of white lung with multiple, coalescent vertical artefacts (B-lines, black arrowhead). A similar lung ultrasound pattern (multiple vertical artefacts, B-lines, black arrowhead) was found in a 42-year-old woman with

COVID-19 pneumonia and moderate respiratory distress (**b**). **c** Lung ultrasound images of a 2-year-old boy with H1N1 influenza pneumonia requiring respiratory assistance with high-flow nasal oxygen at the paediatric department, showing sub-pleural consolidations (hypoechoic areas, black arrow); below, areas of white lung are evident. A similar lung ultrasound pattern (sub-pleural consolidations, black arrow, with areas of white lung) was found in a 31-year-old pregnant woman with COVID-19 pneumonia and acute respiratory failure requiring admission to the intensive care unit (**d**)

internists (even mixing more and less experienced doctors) could help to reintroduce the former to adult patients and to ensure mutual clinical support.

Given their skills in paediatric infectious diseases and LUS, paediatricians DB and LP as well as many of their colleagues have been included in the management of adults with COVID-19 in institutions in Italy. In Bologna, two internists, two paediatricians (including LP), one endocrinologist, and a group of mixed paediatric and internist residents managed a COVID ward for five weeks, from March 16, 2020, to April 17, 2020. It was a 30-bed ward with two negative-pressure rooms for patients on CPAP. In those five weeks, a total of 145 patients were managed on oxygen therapy and CPAP. Three other paediatricians have been integrated in three other COVID equips. Many specialists were involved in the COVID wards, but only the paediatricians actively supported the internists in the management of patients. The success of this collaboration was derived from a common way of thinking in dealing with patients and multi-systemic diseases. Even if a paediatrician is not confident with adults' common pathologies, their tendency to look at the patient as a whole helped to recognise worsening signs early and to facilitate discussions about the patients. These equal views also helped to reduce stress in a highly stressful situation, which could have been worse in a context where internists would have to carry the whole task by themselves while other specialists would feel too frustrated to manage risky and unfamiliar situations.

In Rome, a paediatrician (DB) became responsible for the LUS evaluation of pregnant women with respiratory conditions so as to reduce the routine use of chest X-rays and computed tomography (CT) scans in this specific group, reserving these tools to selected cases [22, 23]. In particular, since March 2020, 62 pregnant women who tested positive for COVID-19 have been evaluated via chest ultrasound. No COVID-19-positive pregnant woman has undergone a chest CT scan so far, and LUS has become the first-level tool to diagnose pneumonia.

The past, current, and projected scales of distress among healthcare professionals, while understandable, have been and are of grave concern [9]. The short- and long-term negative effects of this disease have both physical and psychological consequences that can significantly impact the quality of life of both the health worker and their family. The existing risks to the well-being of healthcare professionals are compounded under these high-pressure conditions [24].

Concomitantly, the whole world is facing a severe shortage of personal protective equipment, [3] which contributes to the high number of infections and deaths among healthcare workers worldwide. Altogether, these factors determine an increasing shortage of doctors worldwide, including the richest countries. Having adequate numbers

of health workers and establishing collaboration among different specialists will be critical to winning the battle against COVID-19.

Growing evidence highlights that COVID-19 is a systemic condition that requires doctors with multiple areas of expertise [25]: general support measures, experience in managing antivirals, antibiotics, and biological agents, respiratory support, imaging interpretation, and experience in point-of-care ultrasound. Considering the issues of staff shortage in every country, the complexity of COVID-19, the rare and mild involvement of SARS-CoV-2 in children, [1] and reduced access to paediatric health facilities, [2] paediatricians may represent an important source of ready and skilled specialists who can quickly translate the paediatric practice in COVID-19 care.

**Acknowledgements** We are extremely grateful to the Italian Academy of Thoracic Ultrasound (Accademia Italiana Di Ecografia Toracica – ADET). All clinicians and researchers of the Academy (and dr. Gino Soldati in particular) are teaching for decades Italian doctors on the use of lung ultrasound, and in particular thought and inspired the youngest generation of doctors from different specialties across the country. Thanks to their teachings, we have been able to help children and adults with COVID-19 and other respiratory infections, playing our active role in this pandemic. We hope that this commentary will inspire other young colleagues and show the importance of this clinical tool.

**Funding** Nothing to declare.

## Declarations

**Conflicts of interest** None of the participants has any conflict of interest to declare.

## References

1. Viner RM, Mytton OT, Bonell C et al (2021) Susceptibility to SARS-CoV-2 infection among children and adolescents compared with adults: a systematic review and meta-analysis. *JAMA Pediatr* 175(2):143–156
2. Roland D, Harwood R, Bishop N, Hargreaves D, Patel S, Sinha I (2020) Children's emergency presentations during the COVID-19 pandemic. *Lancet Child Adolesc Health* 4(8):e32–e33
3. Bressan S, Buonsenso D, Farrugia R et al (2020) Preparedness and response to pediatric COVID-19 in European emergency departments: a survey of the REPEM and PERUKI networks. *Ann Emerg Med* 76(6):788–800
4. Mehta P, McAuley DF, Brown M et al (2020) HLH Across Speciality Collaboration, UK COVID-19: consider cytokine storm syndromes and immunosuppression. *Lancet* 395(10229):1033–1034
5. Harwood R, Allin B, Jones CE et al (2020) PIMS-TS National Consensus Management Study Group. A national consensus management pathway for paediatric inflammatory multisystem syndrome temporally associated with COVID-19 (PIMS-TS): results of a national Delphi process. *Lancet Child Adolesc Health*. [https://doi.org/10.1016/S2352-4642\(20\)30304-7](https://doi.org/10.1016/S2352-4642(20)30304-7)
6. Musolino AM, Tomà P, Supino MC et al (2020) Lung ultrasound features of children with complicated and non-complicated

- community acquired pneumonia: a prospective study. *Pediatr Pulmonol* 54:1479–1486
7. Buonsenso D, Soldati G, Curatola A et al (2020) Lung ultrasound pattern in healthy infants during the first 6 months of life. *J Ultrasound Med* 39(12):2379–2388
  8. Buonsenso D, De Rose C, Morello R, Lazzareschi I, Valentini P (2020) Aspiration pneumonia in children with neurological disorders: a new indication for lung ultrasound? A case series. *J Ultrasound*. <https://doi.org/10.1007/s40477-020-00520-4>
  9. Berce V, Tomazin M, Gorenjak M, Berce T, Lovrenčić B (2019) The usefulness of lung ultrasound for the aetiological diagnosis of community-acquired pneumonia in children. *Sci Rep* 9(1):17957
  10. Liu J, Lovrenski J, Ye Hlaing A, Kurepa D (2019) Neonatal lung diseases: lung ultrasound or chest X-ray. *J Matern Fetal Neonatal Med* 20:1–6
  11. Supino MC, Buonsenso D, Scateni S et al (2019) Point-of-care lung ultrasound in infants with bronchiolitis in the pediatric emergency department: a prospective study. *Eur J Pediatr* 178:623–632
  12. Buonsenso D, Supino MC, Giglioni E et al (2018) Point of care diaphragm ultrasound in infants with bronchiolitis: a prospective study. *Pediatr Pulmonol* 53(6):778–786
  13. Buonsenso D, Brancato F, Valentini P, Curatola A, Supino M, Musolino AM (2020) The use of lung ultrasound to monitor the antibiotic response of community-acquired pneumonia in children: a preliminary hypothesis. *J Ultrasound Med* 39(4):817–826
  14. Soldati G, Demi M, Demi L (2019) Ultrasound patterns of pulmonary edema. *Ann Transl Med* 7(Suppl 1):S16
  15. Soldati G, Demi M, Inchingolo R, Smargiassi A, Demi L (2016) On the physical basis of pulmonary sonographic interstitial syndrome. *J Ultrasound Med* 35:2075–2086
  16. Buonsenso D, Piano A, Raffaelli F, Bonadia N, de Gaetano DK, Franceschi F (2020) Point-of-care lung ultrasound findings in novel coronavirus disease-19 pneumoniae: a case report and potential applications during COVID-19 outbreak. *Eur Rev Med Pharmacol Sci* 24(5):2776–2780
  17. Buonsenso D, Pata D, Chiaretti A (2020) COVID-19 outbreak: less stethoscope, more ultrasound. *Lancet Respir Med*. [https://doi.org/10.1016/S2213-2600\(20\)30120-X](https://doi.org/10.1016/S2213-2600(20)30120-X)
  18. De Rose C, Inchingolo R, Smargiassi A, Zampino G, Valentini P, Buonsenso D (2020) How to perform pediatric lung ultrasound examinations in the time of COVID-19. *J Ultrasound Med* 39(10):2081–2082
  19. Soldati G, Smargiassi A, Inchingolo R et al (2020) Is there a role for lung ultrasound during the COVID-19 pandemic? *J Ultrasound Med* 39(7):1459–1462
  20. Soldati G, Smargiassi A, Inchingolo R et al (2020) Proposal for international standardization of the use of lung ultrasound for patients with COVID-19: a simple, quantitative reproducible method. *J Ultrasound Med* 39(7):1413–1419
  21. Musolino AM, Supino MC, Buonsenso D et al (2021) Lung ultrasound in the diagnosis and monitoring of 30 children with coronavirus disease 2019. *Pediatr Pulmonol*. <https://doi.org/10.1002/ppul.25255>
  22. Buonsenso D, Raffaelli F, Tamburrini E et al (2020) Clinical role of lung ultrasound for diagnosis and monitoring of COVID-19 pneumonia in pregnant women. *Ultrasound Obstet Gynecol* 56(1):106–109
  23. Moro F, Buonsenso D, van der Merwe J et al (2020) A prospective international lung ultrasound analysis study in tertiary maternity wards during the severe acute respiratory syndrome coronavirus 2 pandemic. *J Ultrasound Med*. <https://doi.org/10.1002/jum.15569>
  24. Kinman G, Teoh K, Harriss A (2020) Supporting the well-being of healthcare workers during and after COVID-19. *Occup Med* 70(5):294–296
  25. Guan W-J, Ni Z-Y, Hu Y et al (2020) Clinical characteristics of coronavirus disease 2019 in China. *N Engl J Med* 382:1708–1720

**Publisher's Note** Springer Nature remains neutral with regard to jurisdictional claims in published maps and institutional affiliations.