

Review Article

The biology of distraction osteogenesis for correction of mandibular and craniomaxillofacial defects: A review

Subodh Shankar Natu¹, Iqbal Ali¹, Sarwar Alam², Kolli Yada Giri², Anshita Agarwal³, Vrishali Ajit Kulkarni⁴

Departments of ¹Oral and Maxillofacial Surgery, ⁴Periodontics, Career Post Graduate Institute of Dental Sciences and Hospital, Lucknow, ²Department of Oral and Maxillofacial Surgery, Institute of Dental Sciences, Bareilly, Uttar Pradesh, ³Department of Oral and Maxillofacial Pathology, Vananchal Dental College and Hospital, Garhwa, Jharkhand, India

ABSTRACT

Limb lengthening by distraction osteogenesis was first described in 1905. The technique did not gain wide acceptance until Gavril Ilizarov identified the physiologic and mechanical factors governing successful regeneration of bone formation. Distraction osteogenesis is a new variation of more traditional orthognathic surgical procedure for the correction of dentofacial deformities. It is most commonly used for the correction of more severe deformities and syndromes of both the maxilla and the mandible and can also be used in children at ages previously untreatable. The basic technique includes surgical fracture of deformed bone, insertion of device, 5-7 days rest, and gradual separation of bony segments by subsequent activation at the rate of 1 mm per day, followed by an 8-12 weeks consolidation phase. This allows surgeons, the lengthening and reshaping of deformed bone.

The aim of this paper is to review the principle, technical considerations, applications and limitations of distraction osteogenesis. The application of osteodistraction offers novel solutions for surgical-orthodontic management of developmental anomalies of the craniofacial skeleton as bone may be molded into different shapes along with the soft tissue component gradually thereby resulting in less relapse.

Key Words: Biomechanics, callostasis, distraction histogenesis, distraction osteogenesis, mechanical strain, osteodistraction, vector

Received: December 2012
Accepted: May 2013

Address for correspondence:

Dr. Sarwar Alam,
19, Faculty Residence,
Institute of Dental Sciences,
Pilibhit Bypass,
Bareilly - 243 006, Uttar
Pradesh, India.
E-mail: sarwaralam@
rediffmail.com

INTRODUCTION

Despite the fact that conventional orthognathic surgery and craniofacial reconstruction have experienced widespread success but in recent years the practice of surgery has been altered by an increased understanding and manipulation of biological systems; for example, induction of the native tissue.

Distraction osteogenesis of the craniofacial skeleton serves as an example of this most recent paradigm

shift. It is a process of new bone formation between the surfaces of bone segments gradually separated by incremental traction.^[1-3] Distraction osteogenesis is a technique of applying controlled traction across the site of surgically produced bone disruption while it is healing. The mechanical forces are directed predominantly away from the site, and the technique takes advantage of the regenerative capacity of bone by creating and maintaining an active area of bone formation in the surgically created gap. The bone is lengthened along with its envelop.

There have been reports of this principle of distraction being used as early as in 1905, by Codvilla. In 1937 Kazanjian used "Over the Face" appliance activated by elastic bands. Later, Stader in 1942 used mandibular external fixator. However, it was Ilizarov in 1950s, who established the scientific basis of this concept and showed that with this

Access this article online



Website: <http://drj.mui.ac.ir>

procedure lengthening of long bones without using a graft material was possible. Guerrero *et al.*,^[4]1990 used intraoral distractor attached superiorly to teeth by orthodontic bands and inferiorly to bone by bendable forked arms. Molina and Ortiz-Monasterio were the first to use bidirectional osteodistraction in the mandible. Constantino *et al.*,^[5] did first application of transport distraction osteogenesis for reconstructing segmental mandibular defects. Mandibular distraction in humans using an extraoral distractor in patients with hemifacial microsomias was first reported in 1992^[6]. Cohen *et al.*,^[7] were among the first to apply distraction osteogenesis to the midface in a patient with unilateral craniofacial microsomia.

LAW OF TENSION-STRESS EFFECT

Gradual traction of the tissues creates stress that activates tissue growth and regeneration. The shape and mass of the bone are influenced by the mechanical load and blood supply.^[1,2]

CLASSIFICATION OF DISTRACTION OSTEOGENESIS

Depending upon the place of tensional stress induction technique into Physcal Distraction and Callotasis. Physcal distraction is further classified into Distraction Epiphysiolysis and Chondrodiatasis.^[8]

On the basis of distraction device used as Extraoral, Subcutaneous and Intraoral devices. Intraoral devices were further classified as (a) Submucosal and (b) Extramucosal devices.^[8]

BIOLOGY OF DISTRACTION

Bone formation in general may be through cartilaginous intermediate (endochondral ossification) or from recruitment and differentiation of primitive mesenchymal cells (membranous ossification) seen in distraction osteogenesis [Table 1].

As distraction healing is a highly dynamic cellular process, tensile strains are the leading stimuli for bone regeneration. Mechanical signals play an integral role in bone hemostasis. It is generally suggested that distraction forces leading to cellular deformation are signalled to the cellular genome through mechanotransduction. Nuclear proto-oncogene c-fos and c-jun are found to be unregulated at early stages of distraction and are related to the mechanotransduction and embryonic bone development.^[9]

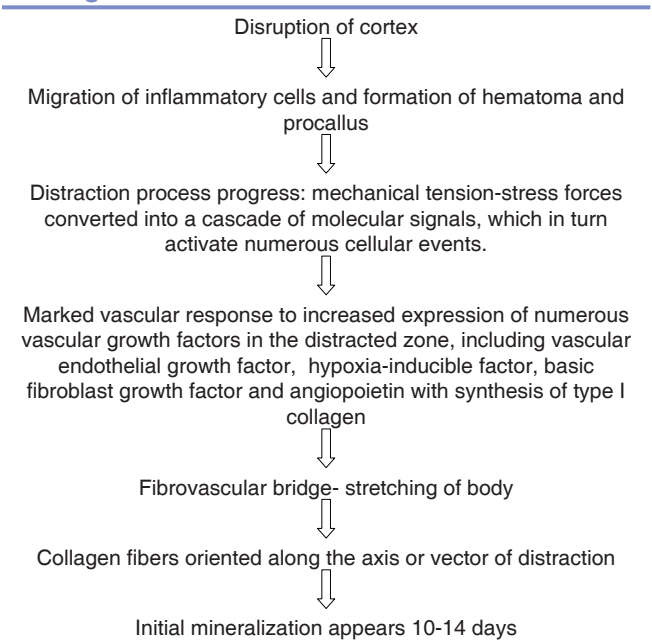
Mechanotransduction

Mechanotransduction is an essential cellular mechanism for bone adaptation to mechanical loading. Bone cells can sense physical force signals, transform these physical stimuli into biochemical signals, integrate these signals into cellular responses of osteoblasts and osteoclasts, and then finally lead to appropriate changes in the architecture of bone.^[10] Mechanotransduction can be categorized in an idealized manner into: (1) Mechanocoupling, (2) biochemical coupling, (3) signal transmission and (4) the effector cell response.^[11]

Mechanocoupling

It is the transduction of mechanical force applied to the tissue into a local mechanical signal perceived by a bone cell. Duncan and Turner^[12] concluded that there are four types of mechanoresponsive structures in cells to sense a load, including integrins, the cytoskeleton, G-proteins and ion channels. Gi-proteins were confirmed to co-localize with stretch-activated calcium channel. Fluid flow can activate stretch-activated calcium channel and/or L-type voltage-activated calcium channel, and further influence the transforming growth factor (TGF)- β expression in human osteoblast-like cells. Recently, Annexin V, a calcium-binding protein, has been identified to be involved in the fluid flow activation of calcium

Table 1: Biology Of Distraction: Molecular events and mechanism of bone formation in distraction osteogenesis in humans



channels. Furthermore, TREK-1, a mechanosensitive member of two-pore domain potassium channel family (2PK+), has been recently found in human osteoblasts and it may play a substantial role in mechanotransduction.^[13]

Biochemical coupling

It is the transduction of a local mechanical signal into biochemical signal cascades altering gene expression or protein activation. Most studies demonstrate that mechanical stress stimulates osteoblasts to release prostaglandin E₂ (PGE₂)^[14] and adenosine triphosphate^[15] and to secrete nitric oxide.^[16] In the downstream effect of PGE₂, anabolic TGF- β messenger RNA (mRNA) and protein levels were both elevated following fluid flow shear stress in human osteoblast-like cells.^[10] Blocking the nitric oxide synthase pathway completely inhibited the fluid flow-induced increases in extracellular signal regulated kinase (ERK) phosphorylation as well as the increase in proliferation and differentiation in human osteoblasts.^[15,17]

Signal transmission

Is transmission of signals from the sensor cells to effector cells, which actually form or remove bone. ERK is considered to be a potential mediator that acts as a signaling convergence point and its activation is a prominent load-induced response of osteoblasts. Mechanical stress regulates Runx2 activation through Ras/Raf-dependent ERK1/2 activation.^[18] Ras-Raf-mitogen-activated protein kinase-ERK cascade can be activated by nitric oxide in response to the stimulation of fluid flow or direct cellular deformation. More intriguingly, mechanical stimulation up-regulated the production of insulin-like growth factor (IGF)-I.^[19] IGF-I significantly prevented tumor necrosis factor- α -induced apoptosis when osteoblasts were subjected to mechanical loading. The downstream signaling in response to IGF-I, including ERK and phosphoinositide 3-kinase (PI3-K)-protein kinase B (Akt) activation, was also enhanced in osteoblasts.^[20] These flow-enhanced IGF-I-activated Akt and ERK phosphorylations can be blocked by PKCzeta inhibitor, indicating that fluid flow may regulate IGF-I signaling in a PKC-zeta-dependent manner in osteoblasts. Moreover, physiological loading was shown to induce the activation of the estrogen receptor.^[19] Osteoblasts lacking estrogen receptor α and estrogen receptor β are unresponsive to mechanical stimulation and that both estrogen receptor α as well as estrogen receptor β rescue ERK activation in response to

stretching.^[21] These findings reveal a novel function of the membrane-associated estrogen receptors that are essential for the transduction of mechanical forces into intracellular survival signaling in osteoblast.

Effector cell response

In osteoblasts, physiological levels of strain were shown to result in an altered expression of bone-specific proteins, such as alkaline phosphatase, collagen I, osteopontin, osteocalcin, Runx2 and osterix. Aside from early response gene c-fos, early growth response factor 1, heme oxygenase 1 and basic fibroblast growth factor can also be induced by mechanical strain. These activities lead to the onset of mineralization, proliferation and differentiation.^[10]

Low magnitude of tensile strain (2%-8% equibiaxial) in the tissues have an anti-inflammatory effects and inhibit proinflammatory gene expression such as interleukin-1 β and COX-2 causing bone formation, whereas tensile strain of high magnitude (15% equibiaxial) induce proinflammatory gene expression rapidly upregulating COX-2 mRNA expression and PGE₂ synthesis resulting in bone resorption.^[22] Application of tension favors the transdifferentiation of chondroblasts and fibroblasts into osteoblasts. Thus, tension causes chondroblast to express type I instead of type II collagen.^[6] Supporting the theory that tension favors intramembranous but not endochondral ossification.

Danis^[23] hypothesized that distraction osteogenesis of long bone relies on two local factors: (a) Mechanical stretching multiplies the fibroblastic population of undifferentiated mesenchymal cells; (b) hypoxia, by vessel elongation and cellular compaction, induces osteogenic stress protein metabolism. Progressive return to aerobic conditions by neoangiogenesis assures the permanency of the new osseous structures.

After performing the osteotomy, there is disruption of cortex followed by migration of inflammatory cells and formation of hematoma and procallus. As distraction process progress, there is marked vascular response including increased angiogenic mediator expression and blood vessel formation.^[24,25] There is synthesis of type I collagen and fibrovascular bridge which acts as a body for stretching. Collagen fibers oriented along the axis or vector of distraction forces. This is followed by initial mineralization which appears 10-14 days of distraction.

Distraction forces applied to bone also create tension in the surrounding soft tissues, initiating a sequence

of adaptive changes in different tissues, including: Skin, blood vessels, nerves, muscle, ligament, tendon, and cartilage.

Long-term success of distraction osteogenesis depends on the ability of the surrounding soft tissues to tolerate distraction forces and to adapt to the resulting increase in skeletal length and volume.

Castano *et al.*,^[26] in their study on Proliferation of Masseter Myocytes After Distraction Osteogenesis of the Porcine Mandible found that Muscle overlying the distracted mandible showed six-fold more proliferating cell nuclear antigen (PCNA) positive myocytes than the contralateral control side. The results of this study suggest that distraction of the porcine mandible induces myocyte proliferation in the masseter muscle. A proliferative response may contribute to improved long-term stability of mandibular expansion by distraction osteogenesis.

REGULATORY FACTORS FOR DISTRACTION-TYPE BONE HEALING

Physical and biological parameters affecting the success of distraction osteogenesis include the macro- and microscopic bone anatomy, the direction and amount of the applied distraction forces, and the regenerative

capacity of the tissues involved. Force transduction via adjacent structures (joints, ligaments, muscles, and soft tissue) influences the regeneration of the tissue between the bone fragments by modulating the stress produced within the callus, which is plastic and malleable. Controlled elongation of the callus results in increase in length of bone without significant disruption of healing process followed by adequate period of immobilization resulting in calcified new bone with normal architecture.

Various factors which regulate bone formation like: Bone morphogenetic protein (BMP) (2, 4, 5, 6, and 7) expressed from beginning of distraction until 2 weeks, IGF I and II, Fibroblast growth factor, TGF β -1. Rh-BMP-2 has been shown to accelerate bone formation in mandibular and tibial distraction models.^[27]

RECENT EXPERIMENTAL WORK IMPLICATIONS TO PROMOTE REGENERATION, FORMATION AND MATURATION IN DISTRACTION OSTEOGENESIS^[28]

[Table 2]^[29-33]

Cho *et al.*^[34] studied the Effect of Chitosan Bead Encapsulating Calcium Sulfate as an Injectable

Table 2: Recent experimental work implications to promote regeneration, formation and maturation in distraction osteogenesis

Cell therapy: Transplantation of osteoblast like cells to the distracted callus	Enhances angiogenesis and mineralization
Grafting with demineralized bone matrix	Bone healing at a faster rate than normal
Application of resorbable calcium sulfate	Increases rate of osteogenesis and consolidation
Application of bisphosphonate	Improves BMD, BMC and mechanical properties of bone undergoing distraction osteogenesis
Application of hormones: Recombinant growth hormone; 2 β -(3-hydroxy-ypropoxy)-1 α , 25 dihydroxyvitamin D3 (ED-71)	Stimulating effect on regenerate bone healing without changing the callus microstructure
Growth factors: Fibroblast Growth Factor; Insulin-like Growth Factor; VEGF	Stimulates bone formation, stimulates proliferation of Osteoblasts and Chondrocytes
Low intensity pulsed ultrasound	Regenerates bone formation in distraction osteogenesis
Electrical stimulation; Direct current, Capacitively coupled electromagnetic field	Regenerates bone formation in distraction osteogenesis
Osteonectin ^[29]	A glycoprotein that binds to calcium, hydroxyapatite, and collagen, suggesting that it is a nucleator for matrix mineralization.
Alkaline phosphatase ^[29,30]	A cell-linked polypeptide secreted from osteoblasts. It is thought to promote crystal formation in matrix vesicles by removing nucleation inhibitors.
Thrombospondin ^[30]	A trimeric glycoprotein secreted by connective tissue cells. It binds calcium, hydroxyapatite, and osteonectin. Organize extracellular matrix components or act as a growth factor
Bone morphogenic proteins (BMP) ^[31,32]	A family of cytokines that stimulates proliferation of both chondrocytes and osteoblasts and causes increased matrix production in each cell type.
Platelet-derived growth factor (PDGF) ^[31,32]	A growth factor, it stimulates proliferation of chondrocytes and osteoblasts.
Transforming growth factor- β (TGF- β) ^[31-33]	A growth factor, it causes differentiation of Mesenchymal Stem Cell's to chondrocytes, and may also induce chondrocyte and osteoblast proliferation
Estrogen ^[31]	A hormone, it has a complex effect on bone, with the final outcome being decreased bone resorption by osteoclasts.

Bone Substitute on Consolidation in the Mandibular Distraction Osteogenesis of a Dog Model concluded that it facilitate early bony consolidation in distraction osteogenesis. Chitosan is a polysaccharide which enhance bone formation and aid in the differentiation of osteoprogenitor cells.^[35,36] Calcium sulfate is widely recognized as the most cost effective bone graft substitute and is available in a variety of sizes and volumes.^[36,37] It is resorbed and replaced with bone during the healing process.^[38]

BMPs are potent inducers of osteogenesis both during embryological bone formation and in fracture repair. Among the members of the large BMP family, BMP-2, -4, and -7 have been shown to be especially important for osteogenesis. After a fracture, expression of BMP-2, -4, and -7 is quickly induced in cells close to the periosteum and appears to be limited mostly to immature cells and its expression increases after distraction is started.^[39]

Si *et al.*,^[40] used in situ hybridization to show the expression of BMP-2 mRNA in undifferentiated mesenchymal cells after mandibular fractures in rabbits. They found that the BMP-2 signal was greatest at the stage of intramembranous formation of bone and early chondrogenesis, suggesting that BMP-2 mediates the differentiation of mesenchymal cells into osteoblasts and chondroblasts. Marukawa *et al.*,^[41] examined the expression of BMP-2 and PCNA during distraction osteogenesis in the mandible in rabbits. Immunohistochemical analysis showed that BMP-2 and PCNA both appeared initially at the edge of the osteogenesis, but tended to disappear after 14 days. They suggested that suggest that BMP-2 plays an important part in the induction of bone formation during distraction osteogenesis.

Sato *et al.*,^[42] showed the expression of endogenous BMP-2 was strongly enhanced by mechanical tension-stress during the distraction process and that intramembranous ossification was mediated by elevation of endogenous BMP-2 and BMP-4.

Sailhan *et al.*,^[27] in their study Rh-BMP-2 in distraction osteogenesis: Dose effect and premature consolidation found a positive dose effect of rh-BMP-2, while rh-BMP-7 was not able to enhance consolidation whether it was applied at day 0 (osteotomy) or at the end of the distraction phase with doses ranging from 20 to 500 µg/kg. Conversely, rh-BMP-2 was effective in enhancing consolidation when applied (as solid or liquid phase) at day 0 and

at the end of distraction. Possible explanation given by them to this fact is that endogenous BMP-7 is far less expressed than endogenous BMP-2 during the distraction phase.

HISTOLOGY OF DISTRACTION OSTEOGENESIS

Panikarovski *et al.*,^[43] performed the first significant histologic evaluation and following zonal structure of the distraction was demonstrated two zones of mineralization with longitudinally oriented primary osteons, divided by a fibrous interzone with collagen bundles directed parallel to the vector of distraction.

Animal studies by Karp *et al.*,^[44] reported current concept of five histomorphologic zones with four transitional areas between the zones. The five zones are: The central zone, the two paracentral zones, and the two proximal/distal zones.

The four transitional areas are the two areas of vasculogenesis and the two areas of mineralization fronts.

The central zone is the most cellular and most blastema-like. The transitional area of mineralization front shows nascent trabeculae in perfect alignment with the line of tensile force.

Karp *et al.*,^[44] observed longer and thicker bone trabeculae toward the center of the distraction gap at 14 days after the end of distraction and a continuity of bone bridges between the ends of the two original bones at 1 month. At 2 months after distraction, the initial gap was filled with mineralized bone and showed remodeling areas, mainly in dense cortical zones.

DISTRACTION PROTOCOL

Adequate exposure of the site is performed; distractor is fixed in desired position and vector by one or two screw on either side of marked osteotomy line on the bone. Distractor is then removed and the osteotomy completed through and through. Distractor is then repositioned back on to the predetermined place. Osteotomy is checked by activating the distractor for unhindered separation of bone. Distractor is deactivated leaving a small gap between osteotomized segments and closure of flap is then performed. Distractor is finally activated for few turns depending upon size of the bone.

Osteotomy

Osteotomy is the surgical separation of a bone into segments. Osteotomy of bone results in a loss of continuity and the mechanical integrity of the bone. This process stimulates the healing process, which triggers the grouping of osteoprogenitor cells, continues production of bone cells and creates an environment that is suitable for bone conduction. The formation of new bone starts at the fracture ends.

The Incision to access the bone must be conservative in length, with minimal dissection of the periosteum to ensure good blood supply close to the osteotomy site. Osteotomy must be performed with copious irrigation to prevent heating. After distractor is fixed, osteotomy is completed and distractor is activated 2 mm. Bell *et al.*,^[45] demonstrated that marginal alveolar bone at interdental osteotomy sites had to be maintained in order to maximize bone formation within the regenerate tissue. In rabbit tibias, Richards *et al.*,^[46] reported a greater bone regeneration when the distraction followed an osteotomy of 30° compared with one vertical to the bone. It has been speculated that an increase in shear forces may provide greater stimulation of osteoblasts and ossification centers.

Latency period

The duration of latency is controversial for facial bone distraction osteogenesis. An experimental study by Glowacki *et al.*,^[47] in 2004 using 20 minipigs, demonstrated that the bone showed the same degree of stability with a 0 or 4 day latency period. Other animals studies supporting this idea, showed equal bone strength and callus formation between a latency duration of 0 and 7 days in the sheep model.^[48] Troulis *et al.*,^[49] stated that the same radiological density was noted in the pig model with latency periods of 0 and 4 days. A shorter latency period was suggested to be sufficient for the early stage of healing process because the craniofacial bones have a rich vascular supply.^[50] In a review of published studies of craniofacial distraction osteogenesis in 3278 patients, there were no difference between the application and non application of the latency period.^[51] Mandibular distraction was reported to have a latency period of 0-2 weeks^[52]. Based on the above inconsistencies, the suggested optimal duration is between 5 and 7 days.^[53]

During this period histologically initial clot formed is converted at 3 days into granulation tissue which becomes increasingly fibrous due to the presence of collagen and increasingly vascular through the

appearance of new capillaries.^[6] There is initiation of recruitment of mesenchymal stem cells from the bone medulla and adjacent periosteum.^[54]

Distraction phase

This phase usually lasts 1-2 weeks, and the traction modifies the normal development of the regeneration process. A dynamic microenvironment is created with formation of tissue parallel to the distraction vector, Increase and prolongation of angiogenesis, Increased proliferation of spindle shaped fibroblast-like cells, which present a phenotypic variation.^[6]

This type of spindle-shaped cell is situated peripherally and throughout the vessels, producing more type I collagen parallel to the distraction vector.

Cope *et al.*,^[55] in his study on beagle mandibular elongation model reported that after distraction there is atrophy of epithelium with disappearance of papilla and loss of intercellular connection in granular and spinous layers with increased formation of dilated capillaries in lamina propria, mild inflammatory infiltrate and distribution of collagen fibres parallel to distraction vector. At 2 weeks of consolidation, he found mucosa to begin having normal appearance, conjunctive papilla begin to appear with increased epithelial thickness, and cells recovered normal architecture. Epithelium completely gained normalcy at 8 weeks.^[55]

Rate of distraction

Tension-stress law, as proposed by Ilizarov,^[3,56] postulated distraction rate of 1mm per day as the optimum rate for bone regeneration during distraction osteogenesis. Daily distraction aligns collagen fibres into parallel bundles that channel growing vessels and perivascular cells into longitudinal compartments.^[6] While intermittent distraction results in microtrauma in the distraction zone due to relative large movement and higher distraction force. Vessels are disrupted and micro-haematomas are formed. The healing process is interrupted and has to restart after each activation of the distractor leading to delayed healing.^[57,58]

Increasing rate (2 mm/day)-nonunion, fibrous union, or bone weakening. Increasing distraction rate is associated not only with poor bone formation but also with severe soft-tissue contractures and nerve problems.^[59] Decreasing rate (0.5 mm/day) leads to premature consolidation.^[1,2]

Fratzl *et al.*,^[60] have shown that low strains lead to a straightening of collagen fibres, whereas higher strains

induce a molecular gliding within the fibrils, resulting ultimately in the disruption of the fibrillar organization. Furthermore, Landry *et al.*,^[61] have suggested that osteoblasts are removed from the injury site via apoptosis. Recent investigations into distraction osteogenesis have revealed that incremental traction of osteotomized mandibles results in an enhanced rate of apoptosis. As a result of hyperphysiological strain application, some osteoblastic cells in the newly formed tissue at osteotomy sites undergo apoptosis. In contrast, mandibles exposed to lowmagnitudes of strain display only minimal, if any, evidence of programmed cell death.^[62]

Rhythm of distraction

Illizarov suggested rhythm of distraction in increments of 0.5 mm 2 times a day or 0.25 mm 4 times a day. Excessive expansion pressure may cause ischemia, leading to possible tearing of the soft tissue, nerve, muscle, and periodontal problems.

Stabilization/consolidation period

Consolidation is a period after the end of the distraction when the fragments are stabilized in their final position. To enable this distractor is not activated anymore and then used as a rigid fixation device. This period varies from 8 to 12 weeks. During this period mineralization of callus occurs in osseous gap.

VARIABLES THAT MODIFY DISTRACTION PROTOCOL

There are number of variables which modify the protocol such as less time necessary for optimal hard and soft tissue response in younger patients.^[63] Midline expansion can be performed only after the age of 12 years.^[51] Otherwise there appears to be no age-limit for the performance of the procedure.^[64] Deficient hard and soft tissue prolongs latency period in order to promote the initial healing. Larger the magnitude of distraction and amount of bone gained greater is the stabilization period. Geniohyoid musculature can be lengthened to a maximum of 20% resting length.^[65] Some intersegmental micromotion is necessary for ideal bone formation. Too much rigidity of the plate leads to stress shielding effect causing mechanical stress bypass, which apparently prevents the final stages of normal bone reconstitution.^[66] While too much movement leads to fibrous or cartilaginous healing.

Distance from the callus surface to the activating screw is crucial. The closer it is to the central axis

of the bone/callus the more effective the stretching. If it is not in line with the central axis then there will be a turning movement. Cross-sectional area of bone formed and its strength is equal to the cross-sectional area at the site of osteotomy of the mandible.

Several cytokines and transcription factors have been involved in recruitment, differentiation, and proliferation of bony precursors. During distraction, IGF, BMP, and TGF have been implicated.^[67] Different external agents such as radiotherapy may interrupt the complex cascade in which these factors are involved.

EFFECT OF POSITION AND SOFT TISSUE ON DISTRACTION VECTOR

Watzinger *et al.*,^[68] noted that the distraction vector is not only determined by the axis of the distractor, but also by the location of insertion of the distractor. They further suggested that forces from stretched soft tissues and muscle action may change the vector of distraction. Yet, their opinions were based on the observation of only three cases, without comparison to a control group.

Hendrickx *et al.*,^[69] took the comments of Watzinger *et al.*,^[68] a step further and analyzed the amount and direction of movement of the distal and proximal segment during mandibular distraction and attempted to explain some of the influences of the muscles of mastication on the anterior direction of movement. They concluded that there is a posteriorly directed vector that is the reaction force to the action of distraction, and that anteriorly directed forces on the proximal segment are the pull of the masseter, temporalis, and medial pterygoids along with class II elastics. The resulting vector is one of anterior rotation (anterior and inferior). This inferior rotation or deflection was an observation similar to those made in our current investigation. Their investigation was, however, limited to movements recorded in the sagittal plane and they did not investigate the direct effects of the soft tissues and distractor position on distraction vector. Moreover, their study used humans, with inherent natural variations associated with them, including differences in size, shape, proportion density, and so on.

Demann and Haug^[70] in their in vitro evaluation of the effects of soft tissue and position on vector during distraction, statistically significant differences ($P < 0.05$) for distractors without simulated soft tissues were

only noted for vertical deflection between the inferior and superior distractor groups. Statistically significant differences were noted for all measures, for all distractor positions with simulated soft tissues. Statistically significant differences were noted for all measures between similar distractor positions with and without simulated soft tissues. Distractors without simulated soft tissues were deflected lateral to the y-axis and above the x-axis. Distractors with simulated soft tissues were deflected lateral to the y-axis, but below the x-axis. For distractors with simulated soft tissues, the closer to the inferior border, the less the deflection from the x-axis. Concluded that position alone had minimal effects on distraction vector. Simulated soft tissues affected the vector of distraction. The combination of position and simulated soft tissues affected distraction vector.^[70]

RESPONSE OF MUSCLE TO DISTRACTION

Distraction osteogenesis involves two major physical manipulations; detachment and elongation of the masticatory muscle.^[71] The muscles are known to adapt well, but the rate of the distraction that is suitable for hard tissues may not be suitable for muscle adaptation.^[72] The adaptation and proliferation of muscle is demonstrated to be influenced by mechanical variables such as different rates of distraction and the length of the distracted gap.^[26] In addition it is also reported to depend on the age and maturity of the animal.^[73] The gradual distraction process causes a series of changes in the muscle as they adjust to the new position.

The effects of distraction forces on the masseter muscles are different dependant on where the device is fixed in relation to the muscles position.^[26] The masticatory muscles in dogs which were parallel to the distraction vector were reported to show transient atrophy, regeneration and hypertrophy when compared to the muscles which were oriented perpendicular to the vector.^[74] Xiao *et al.*,^[75] conducted the distraction experiment on the dog's mandible and their results supported third finding.

WEIGHT OF THE DISTRACTED MUSCLE

The distracted limb muscle has been noted to increase in weight during the distraction process but return to normal when the distraction ends.^[76] Early increase in weight might be due to muscle oedema and increased

proliferation of new muscle cells. Increase in the tissue volume and weight were also suggested to be due to an increase in endomysial and perimysial fibrosis.^[77] Distraction osteogenesis of the human mandible has been reported to induce soft tissue lengthening and increase in its volume.^[78]

LENGTH OF DISTRACTED MUSCLE

De Deyne *et al.*,^[79] conducted an investigation to look at the effects of different distraction rates on anatomical site of muscle in lengthening. They noted that slow distraction (0.7mm per day) induced an elongation of muscle component and not the tendon. The muscle portion with the contractile component, is adjusted by adding or reducing the number of sarcomeres. Studies on the limbs of dogs, showed that by increasing the number of new sarcomeres resulted in an adjustment to a new length.^[80] Sarcomeres showed an increase in number^[77] but not in length.^[81]

LACK OF DISTRACTED MUSCLE ADAPTATION

The strengths and weakness of the muscle is related to the ability of the muscle fibres to add the contractile component in adjustment to the new length. The appropriate rate will minimize muscle damage and allow sufficient adjustment of sarcomeres to new lengths. Studies of lower limbs have shown that the weakness of muscle was due to the failure of the muscle contractile component to proliferate at higher rates of distraction and this will lead to over stretching of the present contractile component.^[82]

TYPES OF DISTRACTORS

Craniofacial distraction devices can be External or Internal deriving anchorage either from bone known as bone-borne distractors or tooth known as tooth-borne distractors. It could be hybrid that is it derives anchorage from both tooth and bone. According to vector these could be uniplaner applying distraction force in one vector, biplaner applying distraction force in two vectors or multiplaner applying distraction force in multiple vectors.

INDICATIONS

This technique may be used for: Deformity correction, lengthening, widening, bone transport, and alveolar

ridge augmentation of the mandible, midface and upper face, in both congenital and acquired conditions.

ADVANTAGES

Includes

No bone transplantation with the difficult resection of the bone graft. Minimal risk of infection because vital bone is distracted. Not only the bone but also the soft tissue is distracted, so that the new bone is permanently stabilized. The results of the distraction can be reproduced. Simple surgical procedure which does not essentially differ from standard osteosynthesis techniques used in OMF surgery.

The distraction regenerate has neovascularity, which appears to be more resistant to infection than is the case with bone grafting.^[83]

DISADVANTAGES

Includes

Require a second surgical procedure for removal. Soft tissue scars may develop at the pin tracts. Difficult to apply to small bone fragments. The range of movement is limited.

COMPLICATIONS

Immediate complication includes damage to the primary or secondary dentition. While early includes infection, distractor loosening, paraesthesia, problems of compliance. Late complications are occlusal disharmony, incorrect vector, relapse, premature bony consolidation, facial nerve damage, condylar resorption, alterations in the temporomandibular joint. Injury through the distractor and fibrous union correlated to decrease in level of osteocalcin and type I collagen fibres.^[6,52,84]

CONCLUSION

Although orthognathic surgery has gained a generalized acceptance for maxillomandibular deformity correction, several limitations are associated with acute advancement of osteotomized bone segments. Large skeletal discrepancies require such extensive bone movements that the surrounding soft tissues might not adapt to their new position, resulting in relapse or compromised function and esthetics. The application of osteodistraction offers novel solutions for surgical-orthodontic management of

developmental anomalies of the craniofacial skeleton as bone may be molded into different shapes along with the soft tissue component gradually thereby resulting in less relapse.

REFERENCES

1. Ilizarov GA. The tension-stress effect on the genesis and growth of tissues: Part I, the influence of stability of fixation and soft tissue reservation. *Clin Orthop Rel Res* 1989;238:249-81.
2. Ilizarov GA. The tension-stress effect on the genesis and growth of tissues: Part II, the influence of the rate and frequency of distraction. *Clin Orthop Rel Res* 1989;239:263-85.
3. Ilizarov GA. Clinical application of the tension-stress effect for limb lengthening. *Clin Orthop Rel Res* 1990;250:8-26.
4. Guerrero C, Bell WH, Flores A, Modugno VL, Contasti G, Rodriguez AM, *et al.* Intraoral mandibular distraction osteogenesis. *Odontol Dia* 1995;11:116-32.
5. Costantino PD, Shybut G, Friedman CD, Pelzer IIIJ, Masini M, Shindo ML, Sisson GA SR. Segmental mandible regeneration by distraction osteogenesis. *Arch Otolaryngol Head Neck Surg* 1990; 116:535-545.
6. Cano J, Campo J, Moreno LA, Bascones A. Osteogenic alveolar distraction: A review of the literature. *Oral Surg Oral Med Oral Pathol Oral Radiol Endod* 2006;101:11-28.
7. Cohen SR, Rutrick RE, Burstein FD. Distraction osteogenesis of the human craniofacial skeleton: initial experience with a new distraction system. *Craniofac Surg* 1995;6: 368-74.
8. Kumar D, Rastogi N, Singh M. Modern practice in orthognathic and reconstructive surgery craniofacial distraction osteogenesis. *J Public Health Epidemiol* 2011;3:129-37.
9. Lewinson D, Rachmiel A, Rihani-Bisharat S, Kraiem Z, Schenzer P, Korem S *et al.* Stimulation of fos- and jun-related genes during distraction osteogenesis. *J Histochem Cytochem* 2003;51:1161-8
10. Zhang S, Xin-sheng C, Bing W. Mechanotransduction in osteoblast and osteocyte regulation. *J Clin Rehabil Tissue Eng Res* 2011;15:4530-5
11. Meyer U, Kleinheinz J, Joos U. Biomechanical and clinical implications of distraction osteogenesis in craniofacial surgery. *J Craniomaxillofac Surg* 2004;32:140-9.
12. Duncan R, Turner C. Mechanotransduction and the functional response of bone to mechanical strain. *Calcif Tissue Int* 1995; 57:344-358.
13. Hughes S, Magnay J, Foreman M, Publicover SJ, Dobson JP, El Haj AJ. Expression of the mechanosensitive 2PK+channel TREK-1 in human osteoblasts. *J Cell Physiol* 2006;206:738-48.
14. Chan ME, Lu XL, Huo B, Baik AD, Chiang V, Guldberg RE, *et al.* A trabecular bone explant model of osteocyte-osteoblast co-culture for bone mechanobiology. *Cell Mol Bioeng* 2009;2:405-15.
15. Liu D, Genetos DC, Shao Y, Geist DJ, Li J, Ke HZ, *et al.* Activation of extracellular signal regulated kinase (ERK1/2) by fluid shear is Ca(2+)- and ATP-dependent in MC3T3-E1 osteoblasts. *Bone* 2008;42 644-52.
16. Rangaswami H, Marathe N, Zhuang S, Chen Y, Yeh JC, Frangos JA, *et al.* Type II cGMP-dependent protein kinase

- mediates osteoblast mechanotransduction. *J Biol Chem* 2009;284:14796-808.
17. Kapur S, Baylink DJ, Lau KH. Fluid flow shear stress stimulates human osteoblast proliferation and differentiation through multiple interacting and competing signal transduction pathways. *Bone* 2003;32:241-51.
 18. Kanno T, Takahashi T, Tsujisawa T, Ariyoshi W, Nishihara T. Mechanical stress-mediated Runx 2 activation is dependent on Ras/ERK1/2 MAPK signaling in osteoblasts. *J Cell Biochem* 2007;101:1266-77.
 19. Lau KH, Kapur S, Kesavan C, Baylink DJ. Up-regulation of the Wnt, estrogen receptor, insulin-like growth factor-I, and bone morphogenetic protein pathways in C57BL/6J osteoblasts as opposed to C3H/HeJ osteoblasts in part contributes to the differential anabolic response to fluid shear. *J Biol Chem* 2006;281:9576-88.
 20. Triplett JW, O'Riley R, Tekulve K, Norvell SM, Pavalko FM. Mechanical loading by fluid shear stress enhances IGF-1 receptor signaling in osteoblasts in a PKCzeta-dependent manner. *Mol Cell Biomech* 2007;4:13-25.
 21. Aguirre JI, Plotkin LI, Gortazar AR, Millan MM, O'Brien CA, Manolagas SC, *et al.* A novel ligand-independent function of the estrogen receptor is essential for osteocyte and osteoblast mechanotransduction. *J Biol Chem* 2007;282:25501-8.
 22. Gang Li. New development and insights learned from distraction osteogenesis. *Curr Opin Orthop* 2004;15:325-30.
 23. Danis A. Mechanism of bone lengthening by the Ilizarov technique. *Bull Mem Acad R Med Belg* 2001;156:107-12.
 24. Ai-Aql ZS, Alagl AS, Graves DT, Gerstenfeld LC, Einhorn TA. Molecular mechanisms controlling bone formation during fracture healing and distraction osteogenesis. *J Dent Res* 2008;87:107-18.
 25. Byun JH, Park BW, Kim JR, Lee JH. Expression of vascular endothelial growth factor and its receptors after mandibular distraction osteogenesis. *Int J Oral Maxillofac Surg* 2007;36:338-44.
 26. Castaño FJ, Troulis MJ, Glowacki J, Kaban LB, Yates KE. Proliferation of masseter myocytes after distraction osteogenesis of the porcine mandible. *J Oral Maxillofac Surg* 2001;59:302-7.
 27. Sailhan F, Gleyzolle B, Parot R, Guerini H, Viguier E. Rho-BMP-2 in distraction osteogenesis: Dose effect and premature consolidation. *Injury* 2010;41:680-6.
 28. Choi IH, Chung CY, Cho TJ, Yoo WJ. Angiogenesis and mineralization during distraction osteogenesis. *J Korean Med Sci* 2002;17:435-47.
 29. Robey PG. The biochemistry of bone. *Endocrinol Metab Clin North Am* 1989;18:859-902.
 30. Eanes E. Dynamics of calcium phosphate precipitation. In: Bonucci E, editor. *Calcification in biological systems*. London: CRC Press, 1992. p. 2-17.
 31. Buckwalter JA, Glimcher MJ, Cooper RR, Recker R. Bone biology. *J Bone Joint Surg* 1996;77A:1256-89.
 32. Rosen V, Thies RS. Adult skeletal repair. In: *The Cellular and Molecular Basis of Bone Formation and Repair*. New York: Springer; 1995. p. 97-142.
 33. Caplan A, Boyan B. Endochondral bone formation: The lineage cascade. In: Hall B, editor. *Bone*. vol. 8. London: CRC Press; 1994. p. 1-46.
 34. Cho BC, Chung HY, Lee DG, Yang JD, Park JW, Roh KH, *et al.* The effect of chitosan bead encapsulating calcium sulfate as an injectable bone substitute on consolidation in the mandibular distraction osteogenesis of a dog model. *J Oral Maxillofac Surg* 2005;63:1753-64.
 35. Kind GM, Bines SD, Staren ED, Templeton AJ, Economou SG. Chitosan: Evaluation of a new hemostatic agent. *Curr Surg* 1990;47:37-9.
 36. Kawakami T, Antoh M, Hasegawa H, Yamagishi T, Ito M, Eda S. Experimental study on osteoconductive properties of a chitosan-bonded hydroxyapatite self-hardening paste. *Biomaterials* 1992;13:759-63.
 37. Jarcho M. Calcium phosphate ceramics as hard tissue prosthetics. *Clin Orthop Relat Res* 1981:259-78.
 38. Peltier LF. The use of plaster of Paris to fill large defects in bone. *Am J Surg* 1959;97:311-5.
 39. Rauch F, Lauzier D, Croteau S, Travers R, Glorieux FH, Hamdy R. Temporal and spatial expression of bone morphogenetic protein-2, -4, and -7 during distraction osteogenesis in rabbits. *Bone* 2000;27:453-9.
 40. Si X, Jin Y, Yang L, Tipoe GL, White FH. Expression of BMP-2 and TGF-beta 1 mRNA during healing of the rabbit mandible. *Eur J Oral Sci* 1997;105:325-30.
 41. Marukawa K, Ueki K, Alam S, Shimada M, Nakagawa K, Yamamoto E. Expression of bone morphogenetic protein-2 and proliferating cell nuclear antigen during distraction osteogenesis in the mandible in rabbits. *Br J Oral Maxillofac Surg* 2006;44:141-5.
 42. Sato M, Ochi T, Nakase T, Hirota S, Kitamura Y, Nomura S, *et al.* Mechanical tension-stress induces expression of bone morphogenetic protein (BMP)-2 and BMP-4, but not BMP-6, BMP-7, and GDF-5 mRNA, during distraction osteogenesis. *J Bone Miner Res* 1999;14:1084-95.
 43. Panikarovski VV, Grigorian AS, Kaganovich SI, Osipian EM, Antipova ZP. Characteristics of mandibular reparative osteogenesis under compression-distraction osteosynthesis: An experimental study. *Stomatologiya (Mosk)* 1982;61:21-5.
 44. Karp NS, McCarthy JG, Schreiber JS, Sissons HA, Thorne CH. Membranous bone lengthening: A serial histological study. *Ann Plast Surg* 1992;29:2-7.
 45. Bell WH, Harper RP, Gonzalez M, Cherkashin AM, Samchukov ML. Distraction osteogenesis to widen the mandible. *Br J Oral Maxillofac Surg* 1997;35:11-9.
 46. Richards M, Goulet JA, Weiss JA, Waanders NA, Schaffler MB, Goldstein SA. Bone regeneration and fracture healing. Experience with distraction osteogenesis model. *Clin Orthop Relat Res* 1998:S191-204.
 47. Glowacki J, Shusterman EM, Troulis M, Holmes R, Perrott D, Kaban LB. Distraction osteogenesis of the porcine mandible: Histomorphologic evaluation of bone. *Plast Reconstr Surg* 2004;113:566-73.
 48. Tavakoli K, Walsh WR, Bonar F, Smart R, Wulf S, Poole MD. The role of latency in mandibular osteodistraction. *J Craniomaxillofac Surg* 1998;26:209-19.
 49. Troulis MJ, Glowacki J, Perrott DH, Kaban LB. Effects of latency and rate of bone formation in a porcine mandibular distraction model. *J Oral Maxillofac Surg* 2000;58:507-13.

50. Swennen G, Schliephake H, Dempf R, Schierle H, Malevez C. Craniofacial distraction osteogenesis: A review of the literature: Part 1: Clinical studies. *Int J Oral Maxillofac Surg* 2001;30:89-103.
51. Mofid MM, Manson PN, Robertson BC, Tufaro AP, Elias JJ, Vander Kolk CA. Craniofacial distraction osteogenesis: A review of 3278 cases. *Plast Reconstr Surg* 2001;108:1103-14.
52. Aida T, Yoshioka I, Tominaga K, Fukuda J. Effects of latency period in a rabbit mandibular distraction osteogenesis. *Int J Oral Maxillofac Surg* 2003;32:54-62.
53. McCarthy JG, Stelnicki EJ, Mehrara BJ, Longaker MT. Distraction osteogenesis of the craniofacial skeleton. *Plast Reconstr Surg* 2001;107:1812-27.
54. Samchukov ML, Cope JB, Cherkashin AM. Biological basis of new bone formation under the influence of tension stress. In: Samchukov ML, Cope JB, Cherkasin AM, editors. *Craniofacial Distraction Osteogenesis*. St Louis: Mosby; 2001. p. 21-52.
55. Cope JB, Samchukov ML, Muirhead DE. The effect of gradual traction on gingival tissue. In: Samchukov ML, Cope JB, Cherkasin AM, editors. *Craniofacial Distraction Osteogenesis*. St Louis: Mosby; 2001. p. 102-109.
56. Ilizarov GA. The principles of the Ilizarov method. *Bull Hosp Jt Dis Orthop Inst* 1998;48:1-11.
57. Kessler PA, Merten HA, Neukam FW, Wiltfang J. The effects of magnitude and frequency of distraction forces on tissue regeneration in distraction osteogenesis of the mandible. *Plast Reconstr Surg* 2002;109:171-80.
58. Kessler P, Neukam FW, Wiltfang J. Effects of distraction forces and frequency of distraction on bony regeneration. *Br J Oral Maxillofac Surg* 2005;43:392-8.
59. Nogueira MP, Paley D, Bhave A, Herbert A, Nocente C, Herzenberg JE. Nerve lesions associated with limb-lengthening. *J Bone Joint Surg Am* 2003;85-A:1502-10.
60. Fratzl P, Misof K, Zizak I, Rapp G, Amenitsch H, Bernstorff S. Fibrillar structure and mechanical properties of collagen. *J Struct Biol* 1998;122:119-22.
61. Landry P, Sadasivan K, Marino A, Albright J. Apoptosis is coordinately regulated with osteoblast formation during bone healing. *Tissue Cell* 1997;29:413-9.
62. Meyer T, Meyer U, Stratmann U, Wiesmann HP, Joos U. Identification of apoptotic cell death in distraction osteogenesis. *Cell Biol Int* 1999;23:439-46.
63. Enlow DH. *Handbook of facial growth*. Philadelphia, WB Saunders, 1975.
64. Denny AD, Talisman R, Hanson PR, Recinos RE. Mandibular distraction osteogenesis in very young patients to correct airway obstruction. *Plast Reconstr Surg* 2001;108:302-11.
65. Hu J, Tang J, Wang D, Buckley MJ. Changes in the inferior alveolar nerve after mandibular lengthening with different rates of distraction. *J Oral Maxillofac Surg* 2001;59:1041-5.
66. Wanger H. Operative lengthening of the femur. *Clin Orthop Relat Res* 1978:125-42.
67. González-García R, Rodríguez-Campo FJ, Naval-Gías L, Sastre-Pérez J, Díaz-González FJ. The effect of radiation in distraction osteogenesis for reconstruction of mandibular segmental defects. *Br J Oral Maxillofac Surg* 2007;45:314-6.
68. Watzinger F, Wanschitz F, Rasse M, Millesi W, Schopper C, Kremser J, *et al.* Computer-aided surgery in distraction osteogenesis of the maxilla and mandible. *Int J Oral Maxillofac Surg* 1999;28:171-5.
69. Hendrickx K, Mommaerts MY, Jacobs W, Abeloos JV, Neyt LF, De Clercq CA. Proximal segment position after distraction with the MD-DOS device. *J Craniomaxillofac Surg* 1999;27:383-6.
70. Demann ET, Haug RH. Do position and soft tissue affect distraction vector? An *in vitro* investigation. *J Oral Maxillofac Surg* 2002;60:149-55.
71. Liu ZJ, King GJ, Herring SW. Alterations of morphology and microdensity in the condyle after mandibular osteodistraction in rat. *J Oral Maxillofac Surg* 2003;61:918-27.
72. Lindsey CA, Makarov MR, Shoemaker S, Birch JG, Buschang PH, Cherkashin AM, *et al.* The effect of limb lengthening on skeletal muscle. *Clin Orthop Relat Res* 2002:278-87.
73. Hayatsu K, De Deyne PG. Muscle adaptation during distraction osteogenesis in skeletally immature and mature rabbits. *J Orthop Res* 2001;19:897-905.
74. Fisher E, Staffenberg DA, McCarthy JG, Miller DC, Zeng J. Histopathologic and biochemical changes in the muscles affected by the distraction osteogenesis of the mandible. *Plast Reconstr Surg* 1997;99:366-71.
75. Xiao W, Shang W, Li W. A histomorphologic and enzyme histochemical study of masticatory muscles affected by distraction osteogenesis of mandible. *Hua Xi Kou Qiang Yi Zue Za Zhi* 2002;20:333-5.
76. Schumacher B, Keller J, Hvid I. Distraction effects on muscle. leg lengthening studied in rabbits. *Acta Orthop Scand* 1994;65:647-50.
77. Simpson AH, Williams PE, Kyberd P, Goldspink G, Kenwright J. The response of muscle to leg lengthening. *J Bone Joint Surg Br* 1995;77:630-6.
78. Polley JW, Figueroa AA, Liou EJ, Cohen M. Longitudinal analysis of mandibular asymmetry in hemifacial microsomia. *Plast Reconstr Surg* 1997;99:328-39.
79. De Deyne PG. Lengthening of muscle during distraction osteogenesis. *Clin Orthop Relat Res* 2002:S171-7.
80. Makarov MR, Kochutina LN, Samchukov ML, Birch JG, Welch RD. Effect of rhythm and level of distraction on muscle structure: An animal study. *Clin Orthop Relat Res* 2001:250-64.
81. Williams P, Kyberd P, Simpson H, Kenwright J, Goldspink G. The morphological basis of increased stiffness of rabbit tibialis anterior muscle following distraction of the tibia. *Basic Appl Mycology* 1998;4:431-7.
82. Williams P, Simpson H, Kenwright J, Goldspink G. Muscle fibre damage and regeneration resulting from surgical limb distraction. *Cells Tissues Organs* 2001;169:395-400.
83. Walker D. Buried bidirectional telescopic mandibular distraction. In: Samchukov M, Cope J, Cherkashin A, editors. *Craniofacial Distraction Osteogenesis*. St. Louis: Mosby;2001. p. 313-322.
84. Suhr MA, Kreusch T. Technical considerations in distraction osteogenesis. *Int J Oral Maxillofac Surg* 2004;33:89-94.

How to cite this article: Natu SS, Ali I, Alam S, Giri KY, Agarwal A, Kulkarni VA. The biology of distraction osteogenesis for correction of mandibular and craniomaxillofacial defects: A review. *Dent Res J* 2014;11:16-26.

Source of Support: Nil. **Conflict of Interest:** None declared.