

Incidental Detection of Primary Spinal Malignant Melanoma before Central Nervous System Dissemination

Yoshifumi Kawanabe, Shigeo Ueda, Nobuhiro Sasaki, and Minoru Hoshimaru

The present case illustrates the incidental detection of a primary malignant melanoma of the thoracic spinal cord before central nervous system dissemination. A 54-year-old female fell down and bruised the thoracolumbar region. The patient visited a local doctor and underwent magnetic resonance imaging (MRI) of the thoracic and lumbar spine to rule out vertebral fractures. MRI revealed no vertebral fracture, but an intradural extramedullary mass was observed at the T12 level. She was referred to our hospital in October 2008. MRI showed that the mass appeared hyperintense on T₁-weighted images and hypointense on T₂-weighted images. T₁-weighted MRI with gadolinium showed a mild homogeneous enhancement of the lesion. The patient underwent laminectomy at T11–L1, along with the complete removal of the tumor, and she exhibited no remarkable symptoms after surgery. Histopathological examination confirmed the diagnosis of malignant melanoma. Malignant melanoma was not detected elsewhere in the body. Neither radiotherapy nor chemotherapy was performed after surgery. Her neurological examination was unremarkable 5 years after the surgery and no tumor recurrence was detected. The present case suggests that patients with primary spinal malignant melanoma may survive >5 years without recurrence after complete surgical removal of the tumor alone. Complete removal of the tumor before central nervous system dissemination may be critical for treatment in such cases. Precise diagnosis via MRI may increase the detection of primary spinal malignant melanoma before central nervous system dissemination, thus facilitating prompt surgical removal, improving the prognosis of patients.

Keywords: primary spinal malignant melanoma, clinical course, diagnosis

Introduction

Currently, the World Health Organization classifies primary melanocytic lesions of the central nervous system as diffuse melanocytosis, melanocytoma, meningeal melanomatosis, and malignant melanoma. Primary malignant melanoma of central nervous system accounts for approximately 1% of all cases of melanoma.¹⁾ It has been hypothesized that primary spinal malignant melanoma arises either from leptomeningeal melanoblasts or from neuroectodermal rest cells.^{1,2)} About 60

cases of primary spinal malignant melanoma have been reported to date,^{3–6)} with the first case reported in 1906.⁷⁾ Therefore, its precise incidence, treatment, and prognosis remain unclear. The prognosis of primary spinal malignant melanoma seems to be better than that of cutaneous melanoma, which is fatal within 6 months in patients with systemic involvement.^{4,8)} The mean survival time of patients with primary spinal malignant melanoma is approximately 6 years after symptom onset.^{5,9)} These facts indicate that surgical excision and postoperative adjuvant therapy, such as radiotherapy and chemotherapy, should be used for slowing the onset of neurological deficits, even in cases with central nervous system dissemination.^{3,9)} To our knowledge, this is the first report of an incidental discovery of primary spinal malignant melanoma in a patient who was treated with only surgery and who survived >5 years without recurrence or dissemination. We present the details of this case and discuss the importance of early, precise diagnosis via magnetic resonance imaging (MRI) and prompt surgical removal.

Case Report

A 54-year-old female fell down and bruised the thoracolumbar region. The patient visited a local doctor and underwent thoracic and lumbar MRI to rule out vertebral fracture. MRI revealed no vertebral fracture, but showed a spinal mass, and she was referred to our hospital in October 2008. The neurological examination performed at admission revealed no deficits. A repeat MRI demonstrated an intradural extramedullary mass at the T12 level, which appeared hyperintense on T₁-weighted images and hypointense on T₂-weighted images (Fig. 1). T₁-weighted MRI with gadolinium contrast revealed a mild enhancement of the lesion (Fig. 1). The tumor was located laterally and it displaced the spinal cord anteriorly. The MRI images suggested spinal malignant melanoma. Pigmented meningioma and schwannoma were considered as a preoperative differential diagnosis. The results of laboratory data indicated no abnormalities. Absence of a primary origin outside the spinal cord was confirmed after dermatological, ophthalmological, and gastrointestinal examinations, as well as by whole-body computed tomography, cranial/cervical MRI, and positron emission tomography. She underwent laminectomy at T11–L1, along with the complete removal of the tumor (Fig. 2). After dural incision, a black-colored tumor with an intact capsule was noted on the surface of the spinal cord (Fig. 2A). The tumor had a plane of cleavage from the adjacent spinal cord, but there were some areas of tight adherence to the pia mater that required meticulous dissection to

Department of Neurosurgery, Otsu Municipal Hospital, Otsu, Shiga

Received: October 29, 2013; Accepted: December 29, 2013

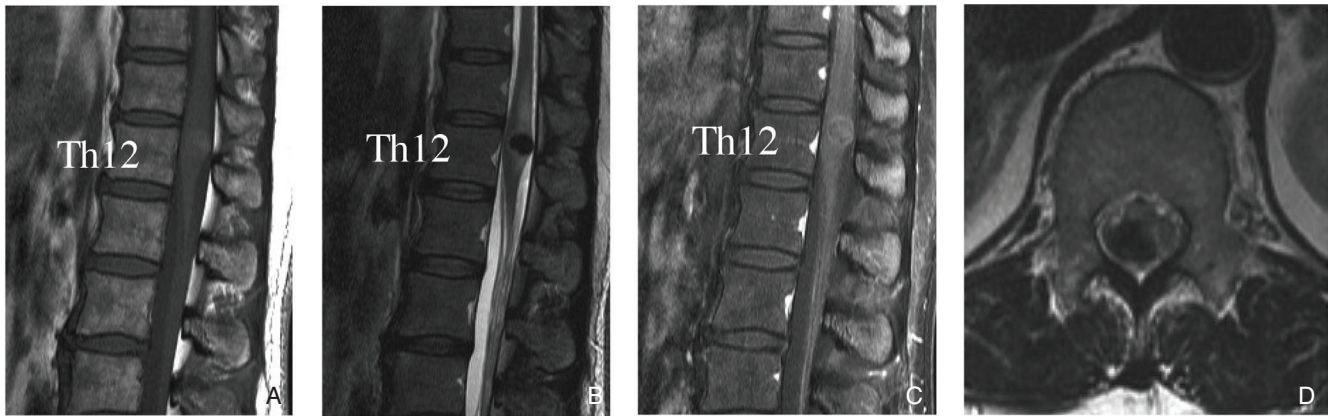


Fig. 1 A: Preoperative T₁-weighted sagittal MRI shows a hyperintense lesion at T12 level. B: Preoperative T₂-weighted sagittal MRI shows a hypointense lesion at T12 level. C: Preoperative T₁-weighted sagittal MRI with gadolinium enhancement reveals the homogenous enhancement of the lesion. D: Preoperative T₂-weighted axial MRI demonstrates an intradural extramedullary lesion that displaced the spinal cord anteriorly. MRI: magnetic resonance imaging.

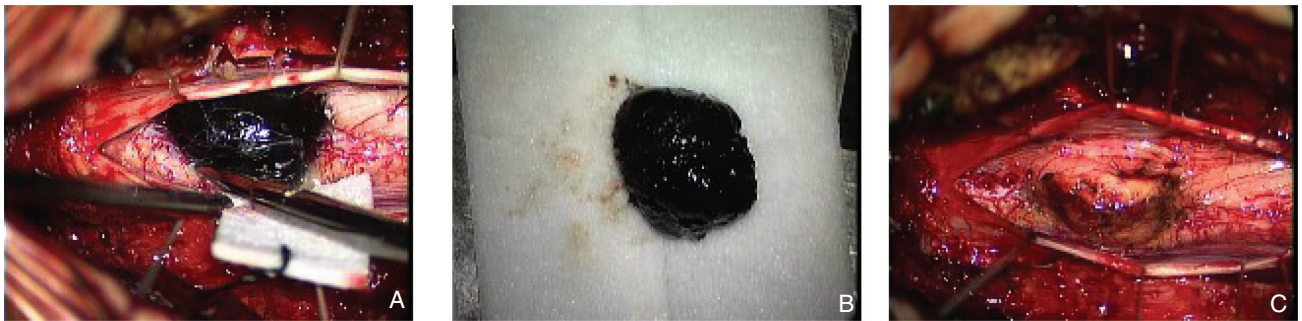

Fig. 2 A: An intraoperative photograph demonstrates an intradural extramedullary tumor. T11–L1 laminectomy is performed. After dural incision, a black-colored tumor with an intact capsule was noted on the surface of the spinal cord. The mass compresses the spinal cord. B, C: The tumor is completely extirpated.

prevent damage to the spinal cord. Microscopic examination under high-power magnification revealed no remarkable pial invasion and minimal subpial penetration and infiltration. The tumor did not involve nerve roots or the dura. There was no vascular invasion. Histological examination revealed that the tumor included a sheet-like proliferation of spindled to polygonal cells with enlarged nuclei and prominent nucleoli (Fig. 3). A moderate variation in nuclear size and shape was observed. Tumor cells had many dark pigment granules in the cytoplasm. Mitotic figures were only encountered occasionally. Immunohistochemical staining was positive for human melanoma black (HMB)-45 (Fig. 3C). Mind bomb homolog-1 (MIB-1) labeling showed an average of 6–7% in multiple fields (Fig. 3D). These histopathological data confirmed the diagnosis of primary spinal malignant melanoma. No postoperative neurological deficit was detected. A postoperative MRI confirmed the completeness of tumor removal. Because of the confirmation of complete removal of the tumor and considering the debatable efficacy of radiotherapy and chemotherapy controversial,^{2,8–12)} no adjuvant therapy was administered to the patient. Her neurological examination remained unchanged 5 years after the surgery, without recurrence or dissemination of the tumor on MRI. We aim to

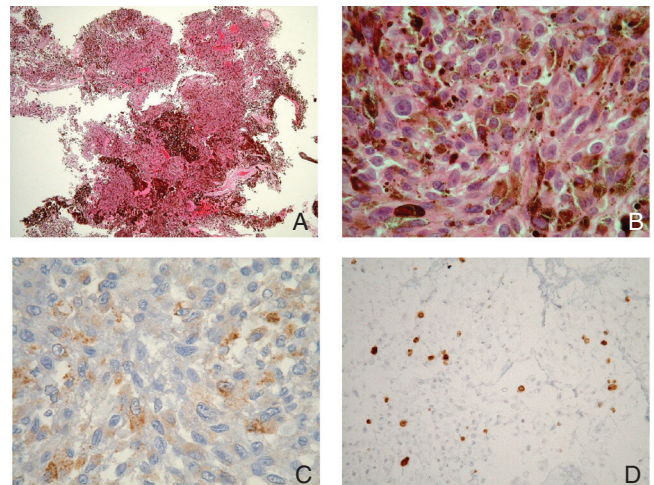


Fig. 3 A, B: Histological examination revealed that the section included a sheet-like proliferation of spindled to polygonal cells with enlarged nuclei and prominent nucleoli. A moderate variation in nuclear size and shape was observed. Tumor cells had many dark pigments in the cytoplasm (hematoxylin eosin stain). C: Immunohistochemical staining was positive for human melanoma black (HMB)-45. D: Mind bomb homolog-1 (MIB-1) labeling averaged 6–7% in multiple fields. The histological diagnosis is malignant melanoma.

perform annual follow-up and MRI in future. Additional surgery, radiotherapy, chemotherapy, and biological therapy, including interferon- α interferon- γ , and interleukin-2 will be attempted if central nervous system dissemination is detected during the follow-up period.

Discussion

It has been suggested that primary spinal malignant melanoma exhibits a slow progression and is less aggressive than the more common case of cutaneous melanoma metastasizing to central nervous system.⁸⁾ The average survival of patients with primary spinal malignant melanoma is 5–6 years after the onset of symptoms, which is clearly longer compared to central nervous system metastasis of cutaneous malignant melanoma, which exhibits a fast progression with systemic spread and leads to a fatal outcome in <6 months.^{5,8,13)} A previous report stated that the presence of the blood brain barrier in the spinal cord prevents hematogenous spread and hampers the process of metastasis.⁴⁾ Considering the slow progression primary spinal malignant melanoma, it is critical to establish a precise diagnosis, because patients should undergo tumor removal to slow down the onset of neurological deficits, even in the case of central nervous system dissemination. MRI is the method of choice for the diagnosis of spinal tumors, including spinal malignant melanoma. According to most authors,^{1–3)} the MRI pattern of spinal malignant melanoma includes signal hyperintensity on T₁-weighted images and signal isointensity or hypointensity on T₂-weighted images. The MRI signal of melanocytic tumors depends on the presence of melanin, as well as on acute or chronic intratumoral hemorrhage and fat deposits.^{1,3)} Our MRI findings were similar to the descriptions available. Importantly, complete removal of the tumor may be possible in cases in which MRI reveals a tumor located in the intradural/extramedullary regions without dissemination, similar to several cases reported previously^{8,9)} and the present case. Therefore, spinal malignant melanoma should be considered as a differential diagnosis when spinal MRI reveals a space-occupying solid lesion with a hyperintense signal on T₁-weighted images and a hypointense signal on T₂-weighted images, and surgical removal of tumor should be performed before dissemination. The following criteria for the diagnosis of primary melanoma of central nervous system has been proposed: (i) no malignant melanoma, either primary or metastatic, should be present elsewhere outside central nervous system; (ii) the tumor should not involve nerve roots and the dura; and (iii) the diagnosis should be confirmed in pathological studies.¹⁴⁾ Our case was diagnosed as primary spinal malignant melanoma according to these criteria. Primary melanoma of the central nervous system originates from aberrant pigment cells from the neural crest or melanocytic elements of the pia mater.^{15,16)} Judging from the intraoperative findings such as the tight adherence of the tumor to the pia mater in some areas and the lack of involvement of spinal cord, nerve roots, or the dura, melanocytic elements of the pia mater may be the source of origin of the tumor in the present case. Previous report demonstrated the

classification of spinal melanoma according to the shape and differentiation status of the cells, and indicated a favorable outcome of pure spindle cell type spinal melanoma.⁴⁾ However, our case had an obviously different histological subtype (may be mixed type). Therefore, further investigation is necessary to conclude whether the histological subtype indicates the prognosis. Most authors agree that complete surgical excision, whenever possible, is the best treatment for this type of tumor. Based on the data obtained for previous cases^{4,17)} and for our case, the detection of the tumor before dissemination may be critical for complete tumor removal and improvement of the average survival times of patients. However, surgical excision of the lesion alone is incomplete because of central nervous system dissemination and is not usually curative in most cases.¹⁰⁾ Therefore, adjuvant radiotherapy and chemotherapy after surgery are frequently recommended, although the effects of radiotherapy and chemotherapy remain controversial.^{2,8–12)} To our knowledge, this is the first case of incidental discovery of a primary spinal malignant melanoma. In addition, this is the case with the longest survival without recurrence among the reported patients with primary spinal malignant melanoma who were treated by surgery alone. The present case may indicate the existence of patients with primary spinal malignant melanoma who survive >5 years without recurrence after complete surgical removal of the tumor alone. We believe that the case has a good prognosis because early detection and total removal of tumor was performed before central nervous system dissemination. In addition, in case of tumors covered with an intact capsule, as well as in the present case, we believe that it is important to avoid tearing the capsule during the operation to prevent tumor dissemination. Although the standard therapeutic protocol in such case is unclear, complete tumor removal and absence of dissemination can be considered as indications for avoiding adjuvant therapy. If cases of malignant melanoma are not diagnosed, and selected conservative medication is not administered because of the absence of neurological signs, tumor dissemination will occur and the opportunity of complete tumor removal may be lost. A precise diagnosis via MRI may increase the detection rates of primary spinal malignant melanoma before dissemination, and prompt surgical removal would improve the prognosis of patients. Moreover, because primary spinal malignant melanoma has an unpredictable clinical course, annual follow-up and MRI examinations are recommended for an extended period. Because an MIB-1 index of >3% may be the factor associated with dissemination,^{6,9)} great care must be taken to detect dissemination in the present case. Periodical reverse transcriptase-polymerase chain reaction assays may also be effective for detecting melanoma cells in the cerebrospinal fluid.¹⁸⁾ Additional surgery, radiotherapy, and chemotherapy, and biological therapy will be attempted if central nervous system dissemination is detected.

Conflicts of Interest Disclosure

The authors have no conflicts of interest to report.

References

- 1) Farrokh D, Fransen P, Faverly D: MR findings of a primary intramedullary malignant melanoma: case report and literature review. *AJNR Am J Neuroradiol* 22: 1864–1866, 2001
- 2) Yamasaki T, Kikuchi H, Yamashita J, Asato R, Fujita M: Primary spinal intramedullary malignant melanoma: case report. *Neurosurgery* 25: 117–121, 1989
- 3) François P, Lioret E, Jan M: Primary spinal melanoma: case report. *Br J Neurosurg* 12: 179–182, 1998
- 4) Kim MS, Yoon DH, Shin DA: Primary spinal cord melanoma. *J Korean Neurosurg Soc* 48: 157–161, 2010
- 5) Salpietro FM, Alafaci C, Gervasio O, La Rosa G, Baio A, Francolini DC, Batolo D, Tomasello F: Primary cervical melanoma with brain metastases. Case report and review of the literature. *J Neurosurg* 89: 659–666, 1998
- 6) Yu J, Zhao DD, Chen S, Zhang JM, Xu J. Primary melanoma of the cervical spine with cerebral metastases: case report and review of the literature. *J Inter Med Res* 40: 1207–1215, 2012
- 7) Hirschberg A: Chromatopharoma medullae spinalis. Ein Beitrag zur Kenntnis der primären chromatopharome des Zentralnervensystem. *Virchows Arch* 186: 229–240, 1906 (Dutch)
- 8) Larson TC, Houser OW, Onofrio BM, Piepgras DG: Primary spinal melanoma. *J Neurosurg* 66: 47–49, 1987
- 9) Nishihara M, Sasayama T, Kondoh T, Tanaka K, Kohmura E, Kudo H: Long-term survival after surgical resection of primary spinal malignant melanoma. *Neurol Med Chir (Tokyo)* 49: 546–548, 2009
- 10) Herbert SH, Solin LJ, Rate WR, Schultz DJ, Hanks GE: The effect of palliative radiation therapy on epidural compression due to metastatic malignant melanoma. *Cancer* 67: 2472–2476, 1991
- 11) Lee SM, Betticher DC, Thatcher N: Melanoma: chemotherapy. *Br Med Bull* 51: 609–630, 1995
- 12) Ozden B, Barlas O, Hacıhanefioğlu U: Primary dural melanomas: report of two cases and review of the literature. *Neurosurgery* 15: 104–107, 1984
- 13) Bremer AM, West CR, Didolkar MS: An evaluation of the surgical management of melanoma of the brain. *J Surg Oncol* 10: 211–219, 1978
- 14) Hayward RD: Malignant melanoma and the central nervous system. A guide for classification based on the clinical findings. *J Neurol Neurosurg Psychiatr* 39: 526–530, 1976
- 15) Pappenheim E, Bhattacharji SK: Primary melanoma of the central nervous system. Clinical-pathological report of a case, with survey and discussion of the literature. *Arch Neurol* 7: 101–113, 1962
- 16) Savitz MH, Anderson PJ: Primary melanoma of the leptomeninges: a review. *Mt Shinai J Med* 41: 774–791, 1974
- 17) Kounin GK, Romansky KV, Traykov LD, Shotekov PM, Stoilova DZ: Primary spinal melanoma with bilateral papilledema. *Clin Neurol Neurosurg* 107: 525–527, 2005
- 18) Hoon DS, Kuo CT, Wascher RA, Fournier P, Wang HJ, O'Day SJ: Molecular detection of metastatic melanoma cells in cerebrospinal fluid in melanoma patients. *J Invest Dermatol* 117: 375–378, 2001

Corresponding author:

Yoshifumi Kawanabe, MD, PhD, (current affiliation) Department of Neurosurgery, Shizuoka General Hospital, 4-27-1, Kita-Antou, Aoi-ku, Shizuoka, Shizuoka 420-8527, Japan.

✉ bwh5255725@yahoo.co.jp