

Vortex Keratopathy in a Patient Receiving Vandetanib for Non-Small Cell Lung Cancer

Jeeyun Ahn¹, Won Ryang Wee², Jin Hak Lee¹, Joon Young Hyon¹

¹Department of Ophthalmology, Seoul National University Bundang Hospital, Seoul National University College of Medicine, Seongnam, Korea

²Department of Ophthalmology, Seoul National University Hospital, Seoul National University College of Medicine, Seoul, Korea

We report a case of vortex keratopathy in a patient treated with vandetanib for non-small cell lung cancer (NSCLC). A 44-year-old female who underwent two cycles of chemotherapy for NSCLC complained of visual blurring in both eyes after the initiation of vandetanib, an anti-epidermal growth factor receptor (EGFR) and anti-vascular endothelial growth factor receptor 2 protein tyrosine kinase inhibitor. On ophthalmic examination, visual acuities were 20 / 20 OU and, with the exception of diffuse vortex keratopathy in both eyes, other findings were unremarkable. Vandetanib is believed to have caused vortex keratopathy in this patient. Anti-EGFR properties affecting normal corneal epithelial cell migration and wound healing or drug associated metabolite deposition, which is the case in numerous drug-associated vortex keratopathies, may be possible underlying mechanisms in the formation of this corneal complication.

Key Words: Epidermal growth factor, Vandetanib, Vortex keratopathy

Vortex keratopathy is characterized by distinctive bilateral corneal subepithelial whorls and is known to be associated with Fabry disease and the use of various drugs. Amiodarone, chloroquine, ibuprofen, indomethacin, naproxen, tamoxifen and chlorpromazine are just a few of the wide array of medications that have been identified so far [1]. Herein, we report a case of vortex keratopathy in a patient treated with vandetanib, a dual epidermal growth factor receptor (EGFR) and vascular endothelial growth factor receptor 2 (VEGFR2) inhibitor used in the treatment of non-small cell lung cancer (NSCLC).

Case Report

A 44-year-old woman was referred to the ophthalmology consultation service in October of 2009 for episodes of intermittent blurred vision in both eyes. Her ophthalmic history was unremarkable. In January of 2009, the patient was diagnosed with NSCLC and after undergoing four cycles of com-

bined chemotherapy consisting of gemcitabine and cisplatin, she was enrolled in a clinical trial for vandetanib (ZD6474), a dual anti-EGFR and anti-VEGFR2 tyrosine kinase inhibitor. After six one-month cycles of vandetanib at 300 mg/day, the patient remarked that she felt as if a thin fog had spread in front of both eyes and she sought ophthalmologic evaluation.

On initial evaluation, her visual acuities were 20 / 20 OU. Intraocular pressures were normal in both eyes. Slit-lamp biomicroscopy examination revealed diffuse subepithelial haze with inferior subepithelial whorls in both corneas (Fig. 1). No staining was observed with the application of fluorescein dye. The conjunctiva was quiet OU and both anterior chambers were deep and clear. Irides, lens and fundus examinations were unremarkable in both eyes and pupillary reaction and ocular motility were also normal. She had no previous use of medications known to be associated with vortex keratopathy.

Although we recommended artificial tear drops for symptomatic relief, the patient felt no dryness in her eyes and wished to forgo the use of any topical medication. She was asked to return to our clinic 3-months later.

Discussion

This case demonstrated vortex keratopathy in both eyes while receiving vandetanib for the treatment of NSCLC. As

Received: December 10, 2009 Accepted: April 19, 2010

Reprint requests to Joon Young Hyon, MD, Department of Ophthalmology, Seoul National University Bundang Hospital, #300 Gumi-dong, Bundang-gu, Seongnam 463-707, Korea. Tel: 82-31-787-7375, Fax: 82-31-787-4057, E-mail: jyhyon@snu.ac.kr

© 2011 The Korean Ophthalmological Society

This is an Open Access article distributed under the terms of the Creative Commons Attribution Non-Commercial License (<http://creativecommons.org/licenses/by-nc/3.0/>) which permits unrestricted non-commercial use, distribution, and reproduction in any medium, provided the original work is properly cited.

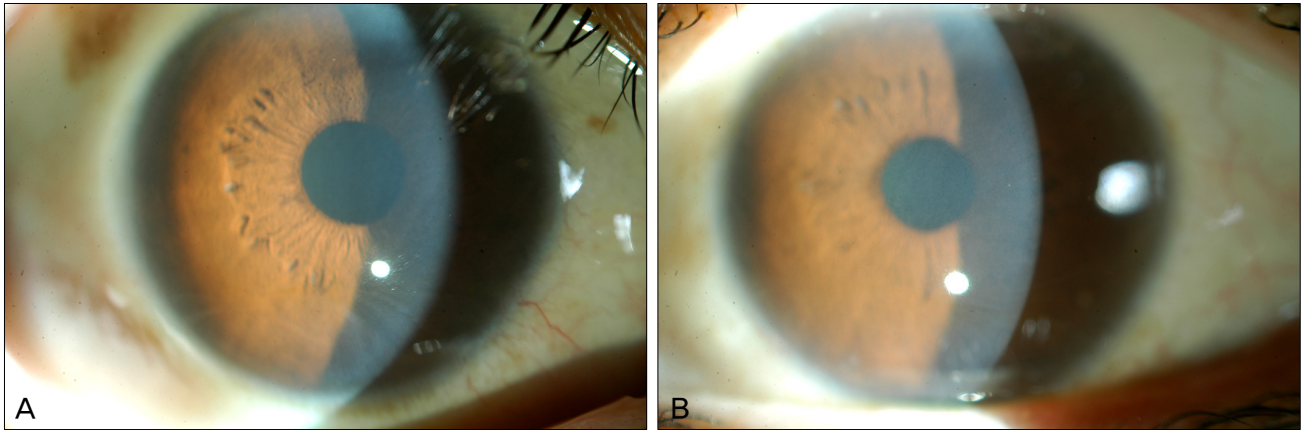


Fig. 1. Photograph of the anterior segment of the right (A) and left (B) cornea of a patient who was treated with vandetanib. Subepithelial corneal haze and whorls are observed.

far as we know, this is the first reported domestic case of vandetanib-induced vortex keratopathy.

Vandetanib (ZD6474) is one of the novel ‘target therapies’ which inhibit signaling pathways involved in the development and progression of cancer [2]. Specifically, it is the first protein tyrosine kinase inhibitor to target both EGFR and VEGFR2. EGFR is known to be over-expressed in the majority of NSCLC and to stimulate cell proliferation, survival, migration and angiogenesis [3,4]. VEGF is the target of numerous antiangiogenesis drugs that seek to limit tumor growth by inhibiting the fundamental process of new blood vessel formation, an essential process for tumor expansion and metabolism.

Epidermal growth factor (EGF) is a small polypeptide that has potent stimulatory effects on epidermal cell proliferation and differentiation [5,6]. In the eye, EGF is one of the main growth factors involved in the maintenance of ocular surface homeostasis [7]. The molecule binds to the EGFR, which is localized in the basal cell layer of the conjunctiva and cornea, stimulates corneal epithelial cell proliferation and migration and is known to play a pivotal role in corneal wound healing [8-11]. Lacrimal EGF messenger RNA was found to be increased in rabbits after corneal epithelial injury. Also, the oral administration of gefitinib (Iressa), an EGFR inhibitor, in rats demonstrated significant effects on the maintenance of normal corneal thickness, epithelial cell proliferation and stratification during corneal epithelial wound healing [12,13].

Reports of ocular complications arising from EGFR inhibitors include reversible recurrent corneal erosions, conjunctival hyperemia, telangiectasia of the eyelid margins, meibomitis, tear film dysfunction, and tortuous eyelashes associated with gefitinib, corneal opacification in animals administered high doses of EGFR inhibitors and trichomegaly and periorbital rash after erlotinib (Tarceva) use [14-17]. There have been only two reports of vortex keratopathy arising after EGFR inhibitor use, namely vandetanib and suramin, an antiparasitic medication that inhibits EGF, platelet-derived growth factor, and tumor growth factor-beta activity [18,19].

Discontinuation of suramin resulted in clearing of the cornea despite persistent corneal opacification and improvement in the patient’s ophthalmic symptoms was observed after vandetanib dose reduction. Interestingly, the patient using vandetanib had underlying epithelial basement membrane dystrophy and a history of recurrent corneal erosions, which may have predisposed her to the development of abnormalities in corneal epithelial wound healing [18].

Vortex keratopathy is characterized by a whorl-like pattern of grayish golden-brown deposits in the corneal epithelium [1]. Although the underlying pathogenesis is yet unclear, intralysosomal lipid-bearing inclusion bodies have been demonstrated in the corneal epithelium of both Fabry’s disease and various drug-induced vortex keratopathy cases [1,20]. Drug-induced vortex keratopathies typically share cationic and amphiphilic properties, allowing them to penetrate lysosomes and bind to cellular lipids, resulting in drug-lipid complexes which are believed to be the intralysosomal inclusion bodies observed in the basal layers of the corneal epithelium [20,21]. On the other hand, biopsies of corneal lesions of suramin-induced vortex keratopathy reveal lysosomal accumulation of glycosaminoglycan [19]. As a biopsy was not performed in our patient, it remains unclear whether the cause for vortex keratopathy was epithelial deposition of vandetanib derived metabolites or defective epithelial turnover and migration due to EGFR inhibitory properties of the drug.

Although this patient did not undergo ophthalmological examination prior to the administration of vandetanib, we could not find any offending factor that could trigger such corneal changes as vortex keratopathy other than vandetanib. Stopping or reducing the dose of vandetanib would have provided better evidence for the establishment of a causal relationship between vandetanib use and vortex keratopathy. Nevertheless, it may be reasonable to assume that vortex keratopathy with subepithelial haziness was induced by vandetanib in this case.

‘Targeted therapies’ have revolutionized cancer treatment

by preferentially targeting cancer cells over normal cells, presumably resulting in better patient tolerability compared to cytotoxic drugs. However, it may be expected that systemic complications will arise from the inhibition of specific signal transmission cascades and the recognition of these drugs as potential causes for such adverse reactions is necessary in light of the expanding use of these drugs in the field of cancer treatment. Increased awareness regarding visual symptoms and regular ophthalmic examination should be deemed mandatory in patients receiving vandetanib for the treatment of various solid malignancies.

Conflict of Interest

No potential conflict of interest relevant to this article was reported.

References

- Hollander DA, Aldave AJ. Drug-induced corneal complications. *Curr Opin Ophthalmol* 2004;15:541-8.
- Pallis AG, Serfass L, Dziadziusko R, et al. Targeted therapies in the treatment of advanced/metastatic NSCLC. *Eur J Cancer* 2009;45:2473-87.
- Schlessinger J. Cell signaling by receptor tyrosine kinases. *Cell* 2000;103:211-25.
- Ciardello F, Tortora G. EGFR antagonists in cancer treatment. *N Engl J Med* 2008;358:1160-74.
- Cohen S. The stimulation of epidermal proliferation by a specific protein (EGF). *Dev Biol* 1965;12:394-407.
- Cohen S, Elliott GA. The stimulation of epidermal keratinization by a protein isolated from the submaxillary gland of the mouse. *J Invest Dermatol* 1963;40:1-5.
- Wilson SE, He YG, Weng J, et al. Effect of epidermal growth factor, hepatocyte growth factor, and keratinocyte growth factor, on proliferation, motility and differentiation of human corneal epithelial cells. *Exp Eye Res* 1994;59:665-78.
- Fрати L, Daniele S, Delogu A, Covelli I. Selective binding of the epidermal growth factor and its specific effects on the epithelial cells of the cornea. *Exp Eye Res* 1972;14:135-41.
- Savage CR Jr, Cohen S. Proliferation of corneal epithelium induced by epidermal growth factor. *Exp Eye Res* 1973;15:361-6.
- Kasayama S, Ohba Y, Oka T. Expression of the epidermal growth factor gene in mouse lacrimal gland: comparison with that in the submandibular gland and kidney. *J Mol Endocrinol* 1990;4:31-6.
- Kinoshita S. Clinical application of epidermal growth factor in ocular surface disorders. *J Dermatol* 1992;19:680-3.
- Wilson SE, Liang Q, Kim WJ. Lacrimal gland HGF, KGF, and EGF mRNA levels increase after corneal epithelial wounding. *Invest Ophthalmol Vis Sci* 1999;40:2185-90.
- Nakamura Y, Sotozono C, Kinoshita S. The epidermal growth factor receptor (EGFR): role in corneal wound healing and homeostasis. *Exp Eye Res* 2001;72:511-7.
- Tullo AB, Esmali B, Murray PI, et al. Ocular findings in patients with solid tumours treated with the epidermal growth factor receptor tyrosine kinase inhibitor gefitinib ('Iressa', ZD1839) in Phase I and II clinical trials. *Eye (Lond)* 2005;19:729-38.
- Yano S, Kondo K, Yamaguchi M, et al. Distribution and function of EGFR in human tissue and the effect of EGFR tyrosine kinase inhibition. *Anticancer Res* 2003;23(5A):3639-50.
- Zhang G, Basti S, Jampol LM. Acquired trichomegaly and symptomatic external ocular changes in patients receiving epidermal growth factor receptor inhibitors: case reports and a review of literature. *Cornea* 2007;26:858-60.
- Lane K, Goldstein SM. Erlotinib-associated trichomegaly. *Ophthal Plast Reconstr Surg* 2007;23:65-6.
- Yeh S, Fine HA, Smith JA. Corneal verticillata after dual anti-epidermal growth factor receptor and anti-vascular endothelial growth factor receptor 2 therapy (vandetanib) for anaplastic astrocytoma. *Cornea* 2009;28:699-702.
- Stein CA, LaRocca RV, Thomas R, et al. Suramin: an anticancer drug with a unique mechanism of action. *J Clin Oncol* 1989;7:499-508.
- D'Amico DJ, Kenyon KR. Drug-induced lipidoses of the cornea and conjunctiva. *Int Ophthalmol* 1981;4:67-76.
- Lullmann H, Lullmann-Rauch R, Wassermann O. Drug-induced phospholipidoses. II. Tissue distribution of the amphiphilic drug chlorphentermine. *CRC Crit Rev Toxicol* 1975;4:185-218.