

This is an Open Access article licensed under the terms of the Creative Commons Attribution-NonCommercial 3.0 Unported license (CC BY-NC) (www.karger.com/OA-license), applicable to the online version of the article only. Distribution permitted for non-commercial purposes only.

Bezoar in a Pediatric Oncology Patient Treated with Coca-Cola

Sara Naramore^a Amy Virojanapa^a Moshe Bell^b Punit N. Jhaveri^c

^aDepartment of Pediatrics, ^cDivision of Pediatric Hematology/Oncology and ^cDivision of Pediatric Gastroenterology, Penn State Hershey Children's Hospital, Hershey, Pa., USA

Key Words

Bezoar · Coca-Cola · Oncology · Intestinal dysmotility

Abstract

A bezoar is a mass of indigestible material. Bezoars can present with a gradual onset of non-specific gastrointestinal symptoms including abdominal pain, nausea and vomiting. However, bezoars can result in more serious conditions such as intestinal bleeding or obstruction. Without quick recognition, particularly in susceptible individuals, the diagnosis and treatment can be delayed. Currently resolution is achieved with enzymatic dissolution, endoscopic fragmentation or surgery. We describe, to our knowledge, the first pediatric patient with lymphoma to have had a bezoar treated with Coca-Cola.

© 2015 S. Karger AG, Basel

Introduction

A bezoar is a mass of indigestible exogenous material accumulated in the gastrointestinal tract. According to the composition, bezoars are classified as diospyrobezoars (unripened persimmons), lactobezoars (inspissated milk), pharmacobezoars (medication), phytobezoars (plant material) or trichobezoars (hair). Diospyrobezoars are the most common gastric bezoar and are formed as the persimmons form a coagulum when mixed with gastric acid. Trichobezoars are found in patients with trichotillomania or trichophagia. The bezoars enlarge with further ingestion of foods containing cellulose and other indigestible materials.

The risk factors for the formation of a bezoar include excessive fiber consumption, chronic antacid treatment, psychiatric or developmental disorders, previous gastric surgery including vagotomy or pyloroplasty, and gastrointestinal dysmotility. In particular, pediatric oncology patients are at risk for dysmotility secondary to adverse effects of medications, poor fluid and dietary intake, and immobility. Patients may present with abdominal pain,

nausea, vomiting, anorexia, weight loss, intestinal bleeding from pressure ulcer necrosis, or intestinal obstruction. The non-specific symptoms arise insidiously, and most bezoars are found incidentally on upper endoscopy or imaging. Resolution of the bezoar can be accomplished by enzymatic dissolution with Coca-Cola or endoscopic fragmentation; surgical intervention may be required for large bezoars causing obstruction or severe bleeding. We describe an adolescent female with a history of T-cell lymphoblastic lymphoma who was found to have a gastric phytobezoar that was successfully treated with Coca-Cola.

Case Report

A 16-year-old female, with a past medical history significant for T-cell lymphoblastic lymphoma in remission and treatment-related myelodysplastic syndrome with subsequent matched sibling bone marrow transplantation in 2013, was admitted to the oncology service due to dehydration in January 2014. The patient had had persistent nausea, early satiety and periumbilical abdominal pain lasting for 2 weeks. The day prior to admission she had developed multiple episodes of non-bloody, non-bilious emesis. For antiemetic therapy she was treated with her home medications of transdermal scopolamine, lorazepam, metoclopramide, promethazine and diphenhydramine as needed. Over the next 2 days, several modifications were made to the dosing and number of her antiemetics, but her nausea persisted. Her abdominal pain was managed with immediate-release oxycodone, which was a chronic home medication. Additionally, she was given pantoprazole for prophylaxis against reactive gastropathy, since she was receiving stress-dose hydrocortisone after having recently been hospitalized for adrenal insufficiency secondary to withdrawal of steroids.

On physical examination she was in no acute distress with stable vital signs including temperature 36.9°C, heart rate 75 bpm, blood pressure 103/55 mm Hg and respiratory rate 18/min. Her weight was 50.8 kg (31st percentile), height 158.5 cm (25th percentile) and BMI 19.9 (38th percentile). She did not have any oral ulcerations or rash, and her abdomen was soft, non-tender and had active bowel sounds.

Further investigation was conducted since initial medical management failed to produce clinical improvement. It was feared that she had developed graft-versus-host disease. Laboratory data revealed no dyselectrolytemia, alanine transaminase 33 U/l (normal 13–69 U/l), aspartate transaminase 47 U/l (normal 15–46 U/l), alkaline phosphatase 69 U/l (normal 38–126 U/l), total bilirubin 0.8 mg/dl and albumin 3.9 g/dl. Blood cell counts showed white blood cells 9,000/ μ l (normal 4,000–104,000/ μ l), platelets 158,000/ μ l (normal 150,000–350,000/ μ l), hemoglobin 11 g/dl (normal 11.7–15 g/dl), hematocrit 31% (normal 35–44%), mean corpuscular volume 90 fl (normal 81–96 fl), mean corpuscular hemoglobin concentration 35 g/dl (normal 32–36 g/dl) and red blood cell distribution width 17% (normal 11.5–14%). Infectious studies including a respiratory viral panel, blood culture and stool testing for *Clostridium difficile* were negative. Routine surveillance testing was negative for Epstein-Barr virus, adenovirus, cytomegalovirus and BK virus.

Pediatric gastroenterology was consulted for further diagnostic evaluation and management of the patient's nausea, emesis and abdominal pain. An upper endoscopy was performed with a gastroscope GIF 190. A large gastric phytobezoar consisting of undigested vegetables was discovered (fig. 1). Cold forceps, in closed position, were used to probe the mass. One liter of saline was used for irrigation. Part of the phytobezoar was fragmented and removed with a Roth Net standard retriever and a Platinum retriever (US Endoscopy). However, the bezoar could not be fully extracted, so 3 l of Coca-Cola were administered through a nasogastric tube over 12 h to dissolve the remaining fragments. Pantoprazole was discon-

tinued to allow gastric acidity to aid in fiber digestion. She was advised to limit her intake of fiber in order to prevent recurrence. Lastly, polyethylene glycol with electrolytes was given to assist with motility and removal of the phytobezoar remnants. Gastric biopsy obtained to evaluate for *Helicobacter pylori* was ultimately negative. A swallow study obtained after treatment with Coca-Cola did not show any filling defects within the stomach or duodenum. She was seen for follow-up 1 and 5 weeks after discharge. Her abdominal pain and emesis had resolved and her nausea was significantly improved.

Discussion

Bezoars are a rare occurrence as the incidence for patients of all ages is 0.4%. Phytobezoars are the most common type found in patients with gastric dysmotility [1]. Patients with oncologic disorders frequently suffer from dysmotility because of adverse effects from medications, poor fluid and dietary intake, and immobility. Gastrointestinal symptoms may develop during their cancer treatment and persist for a prolonged period of time even after completion of therapy. The most common symptoms reported among children with cancer include anorexia, cachexia, nausea, vomiting and constipation [2]. Thus, the rare incidence of bezoars and the demonstration of non-specific symptoms can result in delayed diagnosis.

The formation of the patient's bezoar was secondary to the synergistic effect of multiple risk factors. Her chronic medications contributed to her delayed gastric emptying and constipation. Opioids inhibit gastric emptying by increasing the tone of the pylorus and impair intestinal motility through the development of disordered contractions. The lack of propulsive peristalsis results in increased absorption of fluids and firm stools [3]. Moreover, the treatment of opioid-induced nausea, vomiting and pruritus with first-generation H₁ antagonists, such as diphenhydramine and promethazine, and anticholinergics, such as scopolamine, causes undesirable effects, including constipation [4].

Many oncology patients receive acid suppressants for prophylaxis against reactive gastropathy because corticosteroids are included in numerous chemotherapy regimens. The patient had been receiving significant acid suppression over the last several years. Delayed gastric emptying from acid suppressants may be due to an increase in serum gastrin levels or a decrease in hydrolysis of solid foods. These effects result in larger food particles that do not easily pass through the pylorus and may lead to the development of a bezoar [5]. Moreover, hypochlorhydria along with a high-fiber diet predisposed the patient to a phytobezoar. Fruits, including apples, oranges, berries and persimmons, as well as vegetables, such as green beans, legumes and celery, have been implicated as the foods most commonly causing bezoars [6].

Although the use of vincristine in our patient was remote, it is important to note that vinca alkaloids may cause autonomic neuropathy and intestinal pseudo-obstruction. Vincristine-related pseudo-obstruction has been reported in 21 pediatric cases from 1963 to 2008 [7]. These conditions may manifest as constipation, nausea, vomiting and abdominal pain, all of which are commonly observed in patients undergoing cancer treatment.

The patient had complete resolution of her symptoms, which demonstrates the effectiveness and ease of treatment with Coca-Cola. In a study by Ladas et al. [1], treatment with Coca-Cola alone was successful in removing half of the phytobezoars, but when used in combination with endoscopic techniques, the success rate rose to 90%. Coca-Cola has a pH of 2.6, which is comparable to gastric secretions. Thus, the strong acidity, carbon dioxide gas and the mucolytic effect of sodium bicarbonate are highly effective in dissolving fibrous food particles. The recommended volume based on previous case reports is 3 l given either orally or

by a nasogastric tube over 12 h. However, there must be careful monitoring for the development of small bowel obstruction for up to 6 weeks after the initial treatment, as remnants may migrate distally and become impacted.

Few studies have compared the effectiveness of Coca-Cola in treating other types of bezoars. Ladas et al. [1] demonstrated that only 23% of diospyrobezoars resolved with Coca-Cola alone as compared to 60.6% of phytobezoars. However, subsequent endoscopic procedures resulted in similar outcomes for both types of bezoars. Thus, administration of Coca-Cola assists with softening the hard consistency of diospyrobezoars and allows for easier endoscopic removal. A case report by Harikumar et al. [8] demonstrated the effectiveness of injecting Coca-Cola onto the surface of a pharmacobezoar to cause fragmentation. This resulted in easier removal by a biliary stone extraction basket.

Coca-Cola has been recognized as an effective method of treatment for several types of bezoars, but there have been limited studies evaluating the effectiveness of other carbonated beverages. In a study by Iwamuro et al. [9], Coca-Cola was compared to Coca-Cola Zero and found to be equally effective in dissolution of phytobezoars. Another study by Kramer and Pochapin [10] used Diet Coke and cellulase to dissolve phytobezoars, but the patients required 6–8 weeks of treatment before complete resolution. Oral treatment was used instead of a nasogastric tube, which may have prolonged the treatment time. Moreover, Diet Coke has a higher pH of 3.3, which may have contributed to the length of treatment. The study was unable to determine whether either Diet Coke or cellulase alone would be an effective treatment, but demonstrated that Diet Coke can be used instead of Coca-Cola. This would be beneficial for patients with diabetes who are unable to have a high sugar intake.

Other carbonated beverages have similar levels of acidity, including Pepsi with a pH of 2.5, Diet Pepsi with a pH of 3.0 and Dr. Pepper with a pH of 2.9, so these beverages may ultimately have similar efficacy. Carbonated beverages which do not contain cola have higher pH levels, as seen with Mountain Dew with a pH of 3.2, Sprite with a pH of 3.3 and 7 Up with a pH of 3.2 [11]. Thus, products without cola may not prove to be as effective. The currently accepted practice of treating bezoars with Coca-Cola should remain the first method of management.

Conclusion

Bezoars have been known to develop in patients with conditions affecting gastrointestinal motility. We believe that the patient's chronic medications, decreased oral intake and hypochlorhydria resulted in dysmotility and bezoar development. These factors are often overlooked in hospitalized patients in similar settings. To our knowledge, this is the first report describing the formation of any bezoar in a pediatric oncology patient and the first report demonstrating the resolution of a bezoar after administration of Coca-Cola in any pediatric patient. Although bezoars are rare in the pediatric population, it is important for clinicians to remain cognizant of their formation in susceptible individuals in order to prevent a delay in diagnosis.

Statement of Ethics

Verbal consent was obtained from the patient prior to the writing of this report.

Disclosure Statement

The authors have no conflicts of interest or financial relationships to disclose. No external funding was obtained.

References

- 1 Ladas SD, Kamberoglou D, Karamanolis G, Vlachogiannokos J, Zouboulis-Vafiadis I: Systematic review: Coca-Cola can effectively dissolve gastric phytobezoars as a first-line treatment. *Aliment Pharmacol Ther* 2013;37:169–173.
- 2 Santucci G, Mack JW: Common gastrointestinal symptoms in pediatric palliative care: nausea, vomiting, constipation, anorexia, cachexia. *Pediatr Clin North Am* 2007;54:673–689.
- 3 De Schepper HU, Cremonini F, Park M, Carmilleri M: Opioids and the gut: pharmacology and current clinical experience. *Neurogastroenterol Motil* 2004;16:383–394.
- 4 Simons FER: Non-cardiac adverse effects of antihistamines (H1-receptor antagonists). *Clin Exp Allergy* 1999;29(suppl 3):125–132.
- 5 Parkman HP, Urbain JL, Knight LC, Brown KL, Trate DM, Miller MA, Maurer AH, Fisher RS: Effect of gastric acid suppressants on human gastric motility. *Gut* 1998;42:243–250.
- 6 Sanders M: Bezoars: from mystical charms to medical and nutritional management. *Pract Gastroenterol* 2004;28:37–51.
- 7 Diezi M, Nydegger A, Di Paolo ER, Kuchler H, Beck-Popovic M: Vincristine and intestinal pseudo-obstruction in children: report of 5 cases, literature review, and suggested management. *J Pediatr Hematol Oncol* 2010;32:e126–e130.
- 8 Harikumar R, Kunnel P, Sunilraj R: Dissolution of pharmacobezoar using carbonated beverage. *Indian J Gastroenterol* 2008;27:245–246.
- 9 Iwamuro M, Kawai Y, Shiraha H, Takaki A, Okada H, Yamamoto K: In vitro analysis of gastric phytobezoar dissolubility by Coca-Cola, Coca-Cola Zero, and cellulase, and papain. *J Clin Gastroenterol* 2014;48:190–191.
- 10 Kramer S, Pochapin M: Gastric phytobezoar dissolution with ingestion of Diet Coke and cellulase. *Gastroenterol Hepatol* 2012;8:770–772.
- 11 Jain P, Nihill P, Sobkowski J, Agustin MZ: Commercial soft drinks: pH and in vitro dissolution of enamel. *Gen Dent* 2007;55:150–154.

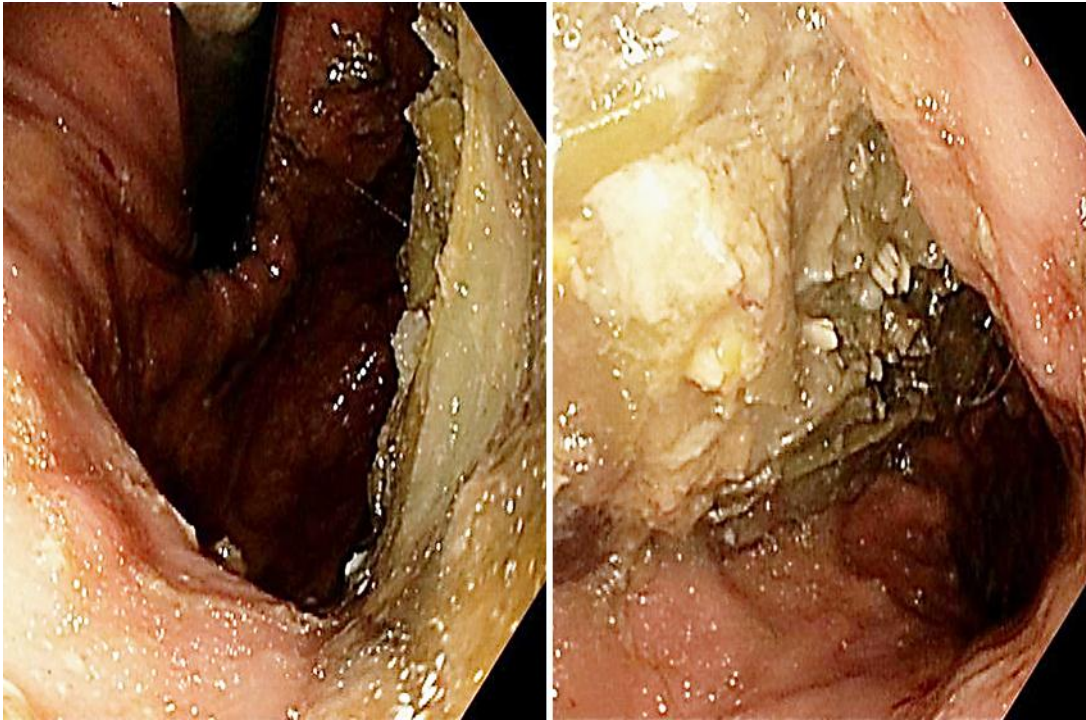


Fig. 1. Upper endoscopy demonstrated a large gastric phytobezoar consisting of undigested vegetables.