

Heterotopic pregnancy with suspicion of superfetation after the intrauterine insemination cycle with ovulation induction using clomiphene citrate: A case report

Ayumu Ito,^{1,2} Takamasa Furukawa,¹
Kentaro Nakaoka,^{1,2} Rika Hayashi,^{1,2}
Tadashi Namihira,^{1,2} Sadanori Kasai,^{1,2}
Kazuko Shimai,¹ Kenji Takahashi,^{1,2}
Masahito Nakakuma¹

¹Department of Obstetrics and Gynecology, Ageo Central General Hospital, Ageo-shi, Saitama-ken;

²Department of Obstetrics and Gynecology, Faculty of Medicine, Toho University, Ota-ku, Tokyo-to, Japan

Abstract

At 22 days after intrauterine insemination with ovulation induction using clomiphene citrate at a previous hospital, a 30-year-old woman was admitted to our hospital owing to right lower quadrant abdominal pain. We diagnosed threatened abortion because of a gestational sac in the uterus on transvaginal ultrasonography. The next day, she complained of increased abdominal pain. Transvaginal ultrasonography revealed a gestational sac-like structure in the echo free space. She was diagnosed with heterotopic pregnancy due to a ruptured right tubal pregnancy, underwent laparoscopic right salpingectomy. Rupture of a gestational age of 5 weeks is extremely rare. If this was a case of a heterotopic pregnancy due to superfetation, it could be explained as this clinical course. When a pregnant woman develops abdominal pain, heterotopic pregnancies should not be excluded from the differential diagnosis, and the possibility of superfetation should be taken into consideration.

Introduction

Superfetation refers to the simultaneous pregnancy of two fetuses of different gestational ages due to the occurrence of ovulation, fertilization, and implantation during a pre-existing pregnancy. Cases of twin pregnancy suspected to be superfetation has rarely been reported.¹⁻³ Although heterotopic pregnancies suspected to be superfetation are extremely rare, there have been a few reported cases.^{4,5}

We report a case of heterotopic preg-

nancy with ruptured tubal fimbria at a gestational age of 5 weeks. Clomiphene citrate was administered to the patient for ovulation induction prior to intrauterine insemination (IUI). The heterotopic pregnancy was likely due to superfetation, occurring after the establishment of an ectopic tubal pregnancy during the preceding untreated self-timing cycle. This case report includes a review of the literature.

Case Report

A 30-year-old primigravid nulliparous woman underwent infertility screening at 8 months prior to consultation at a previous hospital. The patient tested positive for chlamydia IgA, antibody and consequently received clarithromycin therapy; hysterosalpingography subsequently indicated a diagnosis of impaired left fallopian tube patency. Additionally, she was found to have an oligo-ovulatory cycle with a menstrual cycle of 50 days or longer. To induce ovulation, she was treated with clomiphene citrate (50 mg) for 5 days per for 6 cycles prior to intrauterine insemination (IUI). However, pregnancy could not be established. IUI was initiated 3 months before admission. The first IUI treatment after ovulation induction with clomiphene citrate was not successful in establishing a pregnancy. Later, after one untreated self-timing cycle, menstrual-like bleeding occurred. During the next cycle, ovulation was again induced using clomiphene citrate, and 5000 IU of human chorionic gonadotropin (hCG) was administered at day 25 after the start of this menstrual-like bleeding event. During hCG treatment, a total of two ovarian follicles measuring ≥ 16 mm, one in the right ovary and one in the left ovary were detected.

The second IUI was performed on day 26. At 22 days after this treatment, the patient was admitted to the emergency unit at our hospital owing to abdominal pain at the right lower quadrant. Because of her positive pregnancy test result, she was referred to our department for medical consultation. The gestational age, which was calculated based on the number of days since IUI, was determined to be 5 weeks and 1 day. Physical findings included a small amount of vaginal bleeding on speculum examination and mild tenderness at the right adnexal region on pelvic examination. Transvaginal ultrasonography showed a gestational sac measuring 16.6 mm (corresponding to 5 weeks and 2 days of gestation) in the uterus with no fetal heartbeat and no intraperitoneal bleeding. In addition, there was no gestational sac-like structure around the right or left adnexa. The findings

Correspondence: Ayumu Ito, Department of Obstetrics and Gynecology, Faculty of Medicine, Toho University, Ota-ku, Tokyo-to Japan.

Tel./Fax: +8148.773.1111.

E-mail: ayumu.itou@med.toho-u.ac.jp

Acknowledgments: the authors would like to thank all doctors and nurses of Ageo Central General Hospital involved in this case for their support. They are grateful to Ayako Oji of Toho University for carefully proofreading the manuscript.

Key words: Ectopic pregnancy; Heterotopic pregnancy; Infertility treatment; Laparoscopic surgery; Superfetation.

Contributions: AI: drafting of the manuscript; FT: critical revision of the manuscript, supervision; KN: this patients' doctor and in charge of surgery for this patient, critical revision of the manuscript; RH: examined this patients outpatients, critical revision of the manuscript; TN, SK, KS, KT: critical revision of the manuscript; MN: in charge of surgery for this patient, critical revision of the manuscript, supervision.

Conflict of interest: the authors declare no potential conflict of interest.

Funding: none.

Ethical statement: the informed consent had been given by the patient and her families, and we confirmed that patient anonymity should be preserved. This article does not contain any studies with human and animal subjects performed by the any of the authors. Authors must state in the Disclosures section that the protocol for the research project including human subjects has been approved by a suitably constituted Ethics Committee.

Received for publication: 21 January 2019.

Revision received: 3 March 2019.

Accepted for publication: 6 March 2019.

This work is licensed under a Creative Commons Attribution NonCommercial 4.0 License (CC BY-NC 4.0).

©Copyright A. Ito et al., 2019
Licensee PAGEPress, Italy
Clinics and Practice 2019; 9:1129
doi:10.4081/cp.2019.1129

showed a luteinized unruptured follicle measuring 22.4 mm in the left ovary, and absence of echo-free space (EFS) in the pouch of Douglas. Based on physical findings, the patient was diagnosed with threatened abortion, however findings from other gynecological modalities did not show any abnormalities. Therefore, our department decided to employ a wait-and-see approach with respect to follow-up. Later, the patient

consulted our hospital's surgical department for further evaluation of her right lower quadrant abdominal pain at the right lower quadrant. Appendicitis was suspected based on pain; as the patient was pregnant, the surgeon decided not to perform imaging tests, such as computed tomography (CT) and magnetic resonance imaging (MRI), which could allow for a definitive diagnosis. The patient was admitted to the surgery department and treated with antibiotics and analgesics. On day 2 after admission, the patient complained of increased abdominal pain. Abdominal ultrasonography showed massive ascites suspected blood that required another consultation with the gynecology department. Speculum examination showed a small amount of vaginal bleeding, whereas pelvic examination revealed strong tenderness at the right adnexal region. Transvaginal ultrasonography revealed the presence of a 37.7 mm gestational sac with abnormalities of the uterine contour. Findings for the ovaries indicated that the left ovary showed no change, whereas the right ovary was indistinct. However, findings for the pouch of Douglas indicated an EFS, leading to a suspicion of intraperitoneal bleeding with a maximum depth of 36.6 mm. In addition, the findings showed a gestational sac-like structure measuring 15.5 mm in the area corresponding to the EFS (Figure 1). The serum hCG level was 6447.55 mIU/mL. Based on these findings, the patient was diagnosed with heterotopic pregnancy due to a ruptured right tubal pregnancy, which was surgically managed by laparoscopic right salpingectomy on the same day. Laparotomy findings revealed numerous blood clots in the abdominal cavity and ruptured right tubal pregnancy (Figure 2). Postoperative histopathological findings showed that the rupture site was located on the tubal fimbria and that villous components were present at the site. Therefore, the patient was diagnosed with ruptured right fimbrial pregnancy. The postoperative course was uneventful and the patient was discharged on postoperative day 5. Later, the intrauterine pregnancy spontaneously aborted and findings on postoperative day 38 confirmed negative serum hCG level. As an impaired patency of the residual left fallopian tube was previously diagnosed, the attending physician will treat the patient using assisted reproductive technology (ART) in the future.

Discussion

In 1948, De Voe *et al.*⁶ reported that the incidence rate of heterotopic pregnancy was

0.003% in a natural ovulation cycle, 0.013–0.026% in an ovulation induction cycle,^{7–9} and 0.15–2.9% in an ART cycle,^{10–13} indicating higher rates in the latter two cycles than in a natural ovulation cycle. Calculation based on IUI dates in this case report indicated that the rupture occurred as early as 5 weeks into pregnancy. In a previous study that included 232 cases of ectopic pregnancy, Goksedef *et al.*¹⁴ reported that ruptures occurring before 6 weeks accounted for 9 cases (3.88%), with the risk of rupture being 3.67 times higher between 6 and 8 weeks and 46.5 times higher after 8 weeks. Further, they elucidated that this was due to the size of the gestational sac, which increased with gestational age. However, gestational age in spontaneous pregnancies may be inaccurate owing to the variation in ovulation dates because of menstrual irregularities, resulting in the probability of an

ectopic pregnancy rupture before 6 weeks of pregnancy actually being lower than that mentioned in the report. Therefore, rupture at a gestational age of 5 weeks and 2 days is extremely rare. In our case study, pregnancy occurred after IUI.

The intrauterine gestational sac actually corresponded to a gestational age of 5 weeks and 2 days, suggesting that intrauterine pregnancy very likely resulted from the IUI that we performed. Therefore, we examined the possibility that the ruptured fimbrial ectopic pregnancy may have been a superfetation pregnancy.

Superfetation is defined as the occurrence of ovulation, fertilization and implantation of a second or additional embryo(s) during a preexisting pregnancy.¹ Commonly known to occur in various animals, superfetation has also been rarely reported in humans.^{1–3} Although heterotopic pregnancies

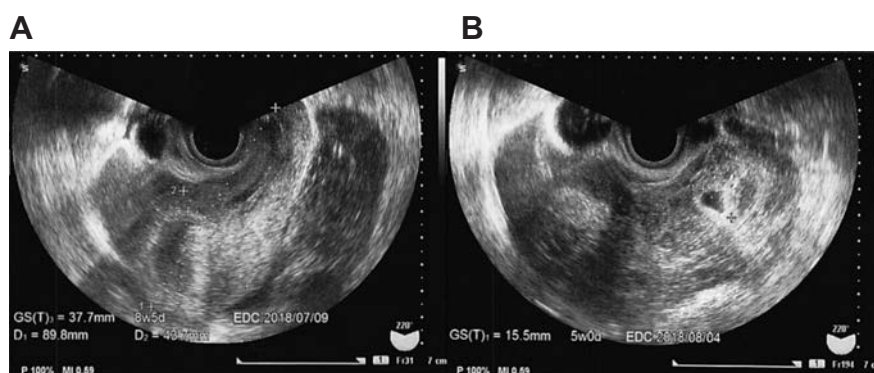


Figure 1. Image showing an intrauterine gestational sac and an image of an estimated extrauterine gestational sac after tubal rupture. A gestational sac with deformities was found inside the uterus (A). A gestational sac-like structure was found inside an echo-free space in the pouch of Douglas (B).

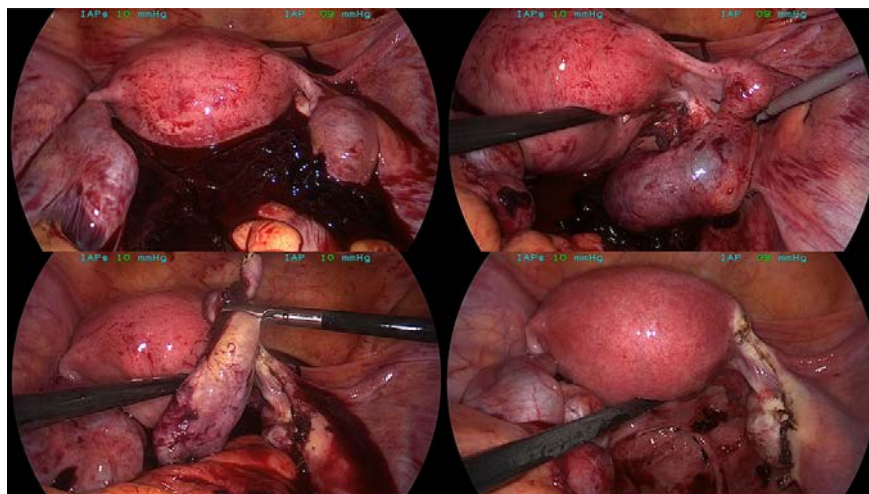


Figure 2. Photograph taken during laparoscopic surgery (at a gestational age of 5 weeks and 2 days according to calculations based on the number of days since intrauterine insemination). Several blood clots were found in the peritoneal cavity. The site of the rupture was in the right fallopian tube resulting in a right salpingectomy was performed.

suspected to be superfetation are extremely rare, there have been a few reported cases.^{4,5} In this case report, assuming that the calculations for the establishment of the pregnancy occurred during the previous cycle, the rupture of the ectopic pregnancy may have occurred at a gestational age of 9-12 weeks considering the patient's cycles due to menstrual irregularities and unknown ovulation dates. The former treating physician assessed the presence of a menstruation-like bleeding and endometrial thinning at the onset of menstruation and prescribed clomiphene citrate as treatment. However, a retrospective view showed that the phase of evaluated basal body temperature had persisted. With respect to the menstruation-like bleeding, the patient reported that she had the impression of normal menstruation. It seems contradictory to think that tubal pregnancy had already been established at this stage. However, Speert *et al.*¹⁵ previously reported that approximately 8% of bleeding, occurring at 1 month after conception was due to pregnancy and that the bleeding from the endometrium was a physiological response to implantation. Alternatively, Lanitieri *et al.*⁴ recommended the preferable measurement of hCG levels before ovulation induction even in the presence of menstruation-like bleeding, suggesting that at least the basal body temperature should have been measured in the case to evaluate the onset of menstruation.

With respect to the mechanism of superfetation occurrence, Tuppen *et al.*² previously showed that superfetation was due to ovulation occurring at different times within the first 3 months of pregnancy.

Several possible mechanisms through which superfetation occurs have been proposed, including polyovulation, and a genetically determined mechanism in which quantitative or qualitative genetic abnormalities in the placental production of hCG could stimulate a secondary ovulation and allow for embryo implantation. Tarin *et al.*¹ previously reported that a luteal out-of-phase like event, in which an atypical increase in E2 levels was observed during the mid-luteal phase, occurred between 1 and 3 weeks after ovulation and may allow passive sperm transport from the vaginal fornix to ovary, triggering a peak in luteinizing hormone (LH) level and ovulation in the ipsilateral fallopian tube. According to Kato *et al.*⁵ if for some reason, estrogen/progesterone secretion from the corpus luteum, which had formed from the first pregnancy, did not reach a level high enough to inhibit the hypothalamic-pitu-

itary system via negative feedback, a secondary ovulation could occur. In addition, they mentioned that in cases of ectopic tubal pregnancies, such as that described in our study, estrogen/progesterone levels might be lower because of an intrauterine pregnancy. In our case study, a secondary ovulation was artificially induced using clomiphene citrate, which may have increased the probability of superfetation occurrence. In fact, Lanitieri *et al.*⁴ previously described a case in which an ectopic tubal pregnancy established from the previous cycle was left unnoticed, as IUI was performed after ovulation induction using gonadotropin therapy, resulting in a heterotopic pregnancy.

Conclusions

Finally, early detection and treatment of ectopic pregnancies, including heterotopic pregnancies, are necessary. In this case study, the condition was diagnosed at approximately 2 days after the amount of intraperitoneal bleeding increased. When a pregnant woman develops abdominal pain, it is important to not exclude heterotopic pregnancies from the differential diagnosis, even if an intrauterine pregnancy has been confirmed. To accomplish this, it is important that the patient interview is thorough and that sufficient information is obtained. This will lead to a more accurate diagnosis. In particular, careful attention should be paid to patients undergoing fertility treatment and ovulation induction and to those who have undergone embryo transplantation for more than two times. Although such cases are extremely rare, the possibility of superfetation should be taken into consideration, and information about the preceding cycle should be acquired.

References

1. Tarin JJ, Garcia-Pérez MA, Hermenegildo C, Cano A. Unpredicted ovulations and conceptions during early pregnancy: an explanatory mechanism of human superfetation. *Reprod Fertil Dev* 2013;25:1012-9.
2. Tuppen GD, Fairs C, de Chazal RC, Konjoe JC. Spontaneous superfetation diagnosed in the first trimester with successful outcome. *Ultrasound Obstet Gynecol* 1999;14:219-21.
3. Bsat FA, Seoud MAF. Superfetaion sec-

ondary to ovulation induction with clomiphene citrate: a case report. *Fertil Steril* 1987;47:516-8.

4. Lanitieri T, Revelli A, Gaglioti P, et al. Superfetation after ovulation induction and intrauterine insemination performed during an unknown ectopic pregnancy. *Reprod BioMed Online* 2010;20:664-8.
5. Kato S, Hashida O, Hashimoto A, et al. A case of superfetaion : intrauterine pregnancy diagnosed after laparoscopic surgery of tubal pregnancy. *Kanto J Obstet Gynecol* 2016;53:35-9.
6. De Voe RW, Pratt JH. Simultaneous intrauterine and extrauterine pregnancy. *Am J Obstet Gynecol* 1948;56:1119-26.
7. Richards SR, Stempel LE, Carlton BD. Heterotopic pregnancy: reappraisal of incidence. *Am J Obstet Gynecol* 1982;141:928-30.
8. Reece EA, Petrie RH, Sirmans MF, et al. Combined intrauterine and extrauterine gestations: a review. *Am J Obstet Gynecol* 1983;146:323-30.
9. Bello GV, Schonholz D, Moshirpur J, et al. Combined pregnancy: the Mount Sinai experience. *Obstet Gynecol Survey* 1986;41:603-13.
10. Dimitry ES, Subak-Sharpe R, Mills M, et al. Nine cases of heterotopic pregnancies in 4 years of in vitro fertilization. *Fertil Steril* 1990;53:107-10.
11. Rizk B, Tan SL, Morcos S, et al. Heterotopic pregnancies after in vitro fertilization and embryo transfer. *Am J Obstet Gynecol* 1991;164:161-64.
12. Tummon IS, Whitmore NA, Daniel SA, et al. Transferring more embryos increases risk of heterotopic pregnancy. *Fertil Steril* 1994;61:1065-7.
13. Clayton HB, Schieve LA, Peterson HB, et al. A comparison of heterotopic and intrauterine-only pregnancy outcomes after assisted reproductive technologies in the United States from 1999 to 2002. *Fertil Steril* 2007;87:303-9.
14. Goksedef BP, Kef S, Akca A, et al. Risk factors for rupture in tubal ectopic pregnancy: definition of the clinical findings. *Eur J Obstet Gynecol Reprod Biol* 2011;154:96-9.
15. Speert H, Guttmacher AF. Frequency and significance of bleeding in early pregnancy. *J Am Med Assoc* 1954;155:712-5.