

Case Report

Peripheral primitive neuroectodermal tumor of the cervical spine

Gustavo A. P. S. Cabral, Cristian F. Nunes, José O. Melo Jr, Rodrigo D. Guimarães, Mariangela B. Gonçalves, Ruy S. Rodrigues, Jorge Luiz A. Correa, Orlando M. Teixeira Jr, João Klescoski Jr, Mario A. Lapenta, José A. Landeiro

Department of Neurosurgery, Galeão Air Force Hospital, Rio de Janeiro, Brazil

E-mail: *Gustavo A. P. S. Cabral - gustavo.cabral@gmail.com; Cristian F. Nunes - cristian.nunes@gmail.com; José O. Melo Jr, - jomjunior@gmail.com; Rodrigo D. Guimarães - rdguimaraes@gmail.com; Mariangela B. Gonçalves - goncalvesmb@gmail.com; Ruy S. Rodrigues - ruyrodrigues657@yahoo.com.br; Jorge Luiz A. Correa - jorgeluizacorreia@gmail.com; Orlando M. Teixeira Jr - orlandomaia@globlo.com; João Klescoski Jr - klesco@gmail.com; Mario A. Lapenta - mariolapenta@hotmail.com; José A. Landeiro - jalandeiro@gmail.com

*Corresponding author

Received: 26 June 12

Accepted: 03 July 12

Published: 21 August 12

This article may be cited as:

Cabral GA, Nunes CF, Melo JO, Guimarães RD, Gonçalves MB, Rodrigues RS, et al. Peripheral primitive neuroectodermal tumor of the cervical spine. *Surg Neurol Int* 2012;3:91.

Available FREE in open access from: <http://www.surgicalneurologyint.com/text.asp?2012/3/1/91/99938>

Copyright: © 2012 Nunes CF. This is an open-access article distributed under the terms of the Creative Commons Attribution License, which permits unrestricted use, distribution, and reproduction in any medium, provided the original author and source are credited.

Abstract

Background: Primitive neuroectodermal tumor (PNET) is a malignant neoplasm that generally arises from bone and soft tissues, with predilection for young adults. This neural crest origin tumors share biologic and histologic features with Ewing's sarcoma (ES).

Case Description: We present a case of a 22-year-old woman with history of severe progressive neck pain, without radiation, associated with paresthesia in the right arm, and palpable right posterior cervical mass. Neurological examination showed increased reflexes in all four limbs, bilateral Hoffman's sign, right Babinski's sign, and right hemi-hypoesthesia. Neuroimaging revealed a right posterior cervical lesion with heterogeneous contrast enhancement extending to the neural foramina of the atlas and axis. Patient underwent microsurgical removal of the lesion, and histopathological and immunohistochemical analysis confirmed the diagnosis of peripheral primitive PNET (pPNET). The patient had adjuvant treatment with radiotherapy and chemotherapy. After twelve months, neuroimaging showed no signs of tumor regrowth and the patient had no neurological deficits. However, three months later, the patient developed hydrocephalus and cerebrospinal fluid (CSF) was positive for neoplastic cells. No other treatment was administered and the patient died.

Conclusion: pPNET is a rare malignant tumor with poor prognosis, although promising results with multimodal treatment-surgery, radiotherapy, and chemotherapy. Diagnosis requires immunohistochemical analysis, with identification of neuronal differentiation markers.

Key Words: Cervical spine, Ewing's sarcoma, primitive neuroectodermal tumor

Access this article online

Website:

www.surgicalneurologyint.com

DOI:

10.4103/2152-7806.99938

Quick Response Code:

INTRODUCTION

The Primitive neuroectodermal tumor (PNET) is a malignant neoplasm originating in neural crest cells that generally affects children and young adults.^[4,5] When present outside the central nervous system (CNS) it is called peripheral PNET (pPNET), being included in the Ewing's sarcoma family of tumors, as it is biologically related to this neoplasm.^[12,15] Diagnosis requires immunohistochemical analysis to identify neuronal differentiation markers. The aim of this paper is to report a case of pPNET in the cervical region with intradural extension in a young patient.

CASE REPORT

Black 22-year-old female was referred to our center with a history of severe progressive neck pain, more intense on the right side, without radiation, associated with paresthesia in the right arm. Symptoms started during pregnancy and progressed for 5 months. Neurological examination showed increased reflexes in all four limbs, bilateral Hoffman's sign, right Babinski's sign, normal muscle strength and right hemi-hypoesthesia. Magnetic resonance imaging (MRI) of the cervical spine showed a right posterior space-occupying cervical lesion with heterogeneous contrast enhancement extending to the neural foramina of the atlas and axis [Figure 1a-d]. The lesion had an anterior lateral intraspinal component compressing the spinal cord.

After informed consent, the patient underwent microsurgical removal of the lesion via suboccipital craniotomy and removal of the right posterior arch of the atlas by the senior author. The initial diagnosis of the frozen material was meningioma. Figure 2 shows the MRI performed in the immediate postoperative period, with adequate decompression of the spinal cord. Histopathological analysis showed a primitive neuroectodermal tumor, and immunohistochemical analysis showed positivity for CD99, synaptophysin, and EMA and negativity for desmin, myogenin, S-100 protein, and pancytokeratin AE1/AE3, favoring the diagnosis of pPNET. Cerebrospinal fluid (CSF) analysis showed no malignant cells.

The patient had a good recovery after surgery, with improvement of the sensory deficit and without cervical pain, being discharged five days later.

Treatment was supplemented with cycles of chemotherapy and radiotherapy for 12 months. Despite complications during adjuvant therapy, such as infection (pneumonia), dysphagia, and dysphonia, the patient improved and regained good quality of life, and returned to work.

Figure 3 shows the radiological follow-up after adjuvant treatment, the absence of contrast enhancement in the region previously occupied by the tumor.

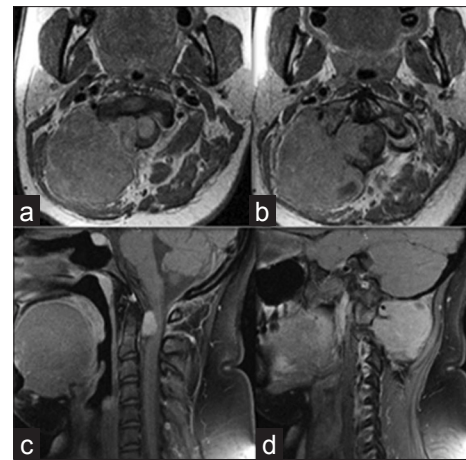


Figure 1: (a) Postgadolinium axial T1-weighted magnetic resonance imaging scan demonstrating intense enhancement of the lesion in the right posterior cervical region, with cervical spine extension. (b and c) intraspinal component compressing the spinal cord antero-laterally. (d) tumoral invasion through right foramina of atlas and axis

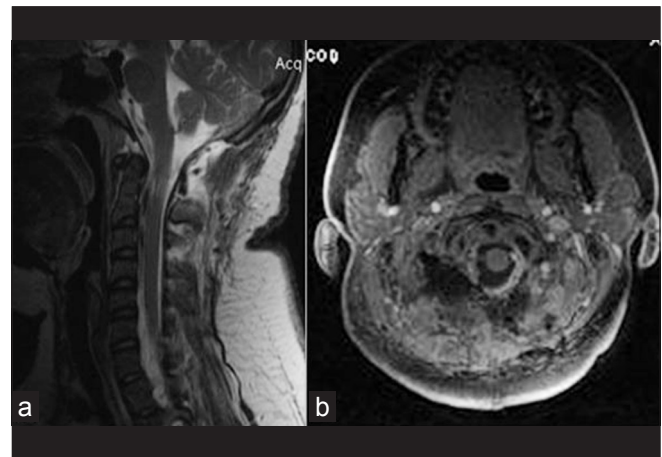


Figure 2: (a) Postoperative sagittal T2-weighted magnetic resonance imaging (MRI) scan showing removal of intraspinal component of the tumor. (b) Postgadolinium axial T1-weighted MRI scan demonstrating good decompression and no enhancement in the cervical region

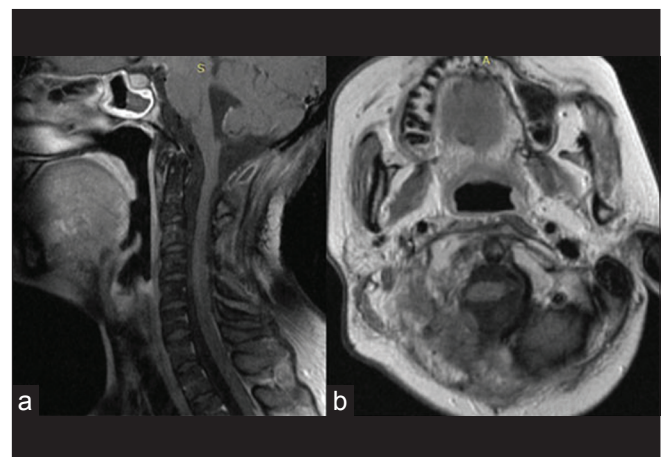


Figure 3: (a, b) Postgadolinium axial T1-weighted MRI scan showing no post-treatment tumor re-growth

Approximately three months after completing the adjuvant treatment, the patient presented with intense generalized headache and vomiting. Emergency CT scan showed communicating hydrocephalus. The patient underwent ventriculoperitoneal shunting, with significant improvement of neurological symptoms. CSF analysis was positive for neoplastic cells, leading to the decision to administer salvage chemotherapy. However, the patient died before any treatment was begun.

DISCUSSION

PNET is a malignant neoplasm composed of small round cells, with neural crest origin and variable degree of differentiation.^[4,5,7,10] It used to be classified as an embryonic tumor of the central nervous system (CNS). Currently, peripherally located tumors of this histological behavior are called pPNET. This neoplasm is included in the Ewing's sarcoma family of tumors, due to its biological similarities with osseous and extrasosseous Ewing's sarcomas.

pPNET is the second most common soft tissue sarcoma in children.^[10] It is more common in males and Caucasians. Paravertebral region, chest wall, pelvis and limbs are the most frequent primary sites.^[2,3] Cases of kidney, myocardium, rectum, ovary, retroperitoneum, and bladder involvement have been reported.^[1,6,10,12,14]

There are no pathognomonic signs and symptoms. Clinical presentation depends on the affected site and the degree of tumor invasion. Systemic manifestations such as fever, anemia, and leukocytosis have been described.^[7]

Diagnostic imaging studies should include magnetic resonance imaging (MRI) and computerized tomography (CT). Radiologic findings are non-specific, with heterogeneous contrast enhancement.^[8]

Definitive diagnosis requires histopathology. Cytological and histological analysis alone is not sufficient for diagnosis; immunohistochemistry and cytogenetic analysis are required.

Microscopically, these tumors consist of small round cells with rounded nuclei, fine chromatin, and an eosinophilic cytoplasm. The term "Ewing's sarcoma" is reserved for undifferentiated neuroectodermal tumors, while "PNET" is used for differentiated tumors. The presence of mitotic figures, necrosis, endothelial hyperplasia, and Homer-Wright rosettes favor the diagnosis of PNET instead of Ewing's sarcoma.^[9]

In immunohistochemical analysis, positivity for surface antigens CD99, 12E7, E2, 013, and HBA71, which are all products of the *MIC2* gene, is very helpful for diagnosing the tumor. Immunoreactivity for synaptophysin, NSE, PGP9.5, vimentin, S100 and neurofilament, indicating neuroectodermal differentiation, may also be observed,

supporting the diagnosis of pPNET.^[10]

The presence of the t (11; 22) (q24, q12) chromosomal translocation, identified by reverse transcription polymerase chain reaction (RT-PCR), is important for confirming the diagnosis and can the prognosis in certain cases.^[2,3,14] The differential diagnosis includes central PNET, malign meningioma, rhabdomyosarcoma, neuroblastoma, and lymphoma.

Due to the aggressive behavior of the neoplasm and its great potential to metastasize, treatment should be multimodal, involving radical surgical resection, radiotherapy, and chemotherapy.^[5]

Surgical approach is effective in controlling local disease and is always recommended. Radiation therapy is commonly used as an adjuvant treatment for residual disease. In recent years, chemotherapy has been showing encouraging results for the treatment of pPNET; the regimen includes multiple agents such as doxorubicin, vincristine, and cyclophosphamide, alternating with ifosfamide and etoposide.^[11,15]

In the medical literature, some factors have been associated with poor outcomes, such as tumor volume >100 cm³, axial location, increased LDH levels, low serum albumin levels, metastasis, older age, and neural differentiation.^[1] Due to the aggressiveness of these tumors, the prognosis is still poor; disease-free survival is approximately 45% at 7 years.^[13]

ACKNOWLEDGEMENT

We thank Dr. Diego Alfaro for helping with the text.

REFERENCES

1. Aparicio J, Munárriz B, Pastor M, Vera FJ, Castel V, Aparisi F, et al. Long-term follow-up and prognostic factors in Ewing's sarcoma. A multivariate analysis of 116 patients from a single institution. *Oncology* 1998;55:20-6.
2. de Alava E, Kawai A, Healey JH, Fligman I, Meyers PA, Huvos AG, et al. EWS-FLII fusion transcript structure is an independent determinant of prognosis in Ewing's sarcoma. *J Clin Oncol* 1998;16:1248-55.
3. de Alava E, Panizo A, Antonescu CR, Huvos AG, Pardo-Mindan FJ, Barr FG, et al. Association of EWS-FLII type I fusion with lower proliferative rate in Ewing's sarcoma. *Am J Pathol* 2000;156:849-55.
4. Dehner LP. Peripheral and central primitive neuroectodermal tumors. A nosologic concept seeking a consensus. *Arch Pathol Lab Med* 1986;110:997-1005.
5. Dehner LP. Primitive neuroectodermal tumor and Ewing's sarcoma. *Am J Surg Pathol* 1993;17:1-13.
6. Fukumoto S, Takamura K, Nakanishi K, Yamamoto M, Inaba S, Makimura S, et al. Peripheral primitive neuroectodermal tumor involving the paravertebral and retroperitoneal regions. *Intern Med* 1997;36:424-9.
7. Grier HE. The Ewing family of tumors: Ewing's sarcoma and primitive neuroectodermal tumors. *Pediatr Clin North Am* 1997;44:991-1004.
8. Ibarburen C, Haberman JJ, Zerhouni EA. Peripheral primitive neuroectodermal tumors. CT and MRI evaluation. *Eur J Radiol* 1996;21:225-32.
9. Jürgens HF. Ewing's sarcoma and peripheral primitive neuroectodermal tumor. *Curr Opin Oncol* 1994;6:391-6.
10. Kim KJ, Jang BW, Lee SK, Kim BK, Nam SL. A case of peripheral primitive

- neuroectodermal tumor of the ovary. *Int J Gynecol Cancer* 2004;14:370-2.
11. Madero L, Muñoz A, Sánchez de Toledo J, Díaz MA, Maldonado MS, Ortega JJ, *et al.* Megatherapy in children with high-risk Ewing's sarcoma in first complete remission. *Bone Marrow Transplant* 1998;21:795-9.
 12. Pomara G, Cappello F, Cuttano MG, Rappa F, Morelli G, Mancini P, *et al.* Primitive neuroectodermal tumor (PNET) of the kidney: A case report. *BMC Cancer* 2004;4:3.
 13. Schmidt D, Herrmann C, Jurgens H, Harms D. Malignant peripheral neuroectodermal tumor and its necessary distinction from Ewing's sarcoma. A report from the Kiel Pediatric Tumor Registry. *Cancer* 1991;68:2251-9.
 14. Song DE, Choi G, Jun SY, Ro JY. Primitive neuroectodermal tumor of the gallbladder. *Arch Pathol Lab Med* 2004;128:571-3
 15. Windfuhr JP. Primitive neuroectodermal tumor of the head and neck: Incidence, diagnosis, and management. *Ann Otol Rhinol Laryngol* 2004;113:533-43.