



OPEN ACCESS

Paediatric cystic ovarian torsion masquerading appendicitis

Smriti Kapoor , Shoaib Saeed, Dinesh Balasubramaniam

General Surgery, Maidstone and Tunbridge Wells NHS Trust, Tunbridge Wells, UK

Correspondence to

Dr Smriti Kapoor;
smritikapoor@doctors.org.uk

Accepted 4 February 2021

SUMMARY

A 7-year-old girl presented with a 2-day history of right iliac fossa pain, fever and elevated inflammatory markers. Clinical examination supported a diagnosis of appendicitis. The patient was taken to theatre for an open appendicectomy the following morning. Intraoperatively, a right-sided ovarian haemorrhagic cyst with 360 degrees torsion was discovered. The ovary was torted along with the cyst. Both were detorted and the abdomen was closed. The patient was discharged 48 hours later, with gynaecology outpatient follow-up 6–8 weeks later. Paediatric ovarian torsions caused by a haemorrhagic cyst greater than 2 cm are rare. Here, we discuss an atypical presentation of ovarian torsion and how the clinical presentation can mimic appendicitis.

BACKGROUND

In the paediatric population, torsion of the ovary is rare with an incidence of around 5 in 100 000.¹ While ovarian cysts measuring 1 cm or less have a prevalence in the prepubertal population of 2%–5%, cysts greater than 2 cm are considered to be rare.² Some cysts are hormonally active and facilitate the development of sexual characteristics.³ Cysts greater than 2 cm require follow-up until regression is seen due to their risk of torsion.

Ovarian torsions usually present with a sudden onset of abdominal pain and may be a differential diagnosis of an acute surgical abdomen. Torsion usually results from twisting of the ligamentous support that results in venous congestion.^{1 3} The condition has previously been managed with an oophorectomy; however, a systematic review has shown detorsion alone to be sufficient, with promising results for future fertility.¹

CASE PRESENTATION

A 7-year-old girl presented to the accident and emergency department in the evening with a 2-day history of worsening right-sided abdominal pain. The pain was non-migratory in nature and was associated with anorexia, a single episode of diarrhoea and vomiting. This was the first time she had experienced this pain. The patient was fit and well with no other medical conditions. She was premenarcheal. Her mother gave an uneventful perinatal history and family history.

On assessment by the surgical team, the patient was found to be feverish with a temperature of 38.1°C. She displayed generalised tenderness over her lower abdomen, but particularly in the right iliac fossa. Her bloods revealed an inflammatory response with a white blood cell (WBC) count of

19 x 10⁹/L and C reactive protein of 62 mg/L. The patient was started on intravenous antibiotics. As the patient remained clinically stable overnight, a plan was made to perform an open appendicectomy the following morning.

Intraoperatively, she was found to have an appendix adhering to the posterior aspect of the caecum, which looked macroscopically normal. While no free fluid was identified, mesenteric lymph nodes of the small bowel were identified with no Meckel's diverticulum. A decision was made to remove the appendix.

Before closure, a limited inspection of the pelvis was performed through the right iliac fossa wound. This revealed a suspicious black lesion and so the wound was extended to allow further exploration. The patient was found to have a large haemorrhagic torted ovarian cyst measuring 7×3 cm, which ruptured on mobilisation. The attached ovary appeared ischaemic (figure 1). The cyst had torted through a full 360°. The ovary's appearance did not change following detorsion. After detorting the cyst, senior gynaecology input was sought. The advice was that, in spite of the appearance of the ovary, there was potential for it to recover and retain function, and so both the ovary and the cyst were carefully placed back into the pelvis. The wound was closed as per normal.

Over the following 24 hours, the WBC normalised and the patient improved clinically. She was discharged home and has recovered well.

INVESTIGATIONS

The patient had a urinary microscopy culture and sensitivity, which was unremarkable.

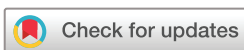No imaging was conducted.

OUTCOME AND FOLLOW-UP

The patient has recovered well following her surgery. The patient had a follow-up ultrasound scan at 3 months, which demonstrated the left ovary measuring 38×17×26 mm and a right ovary measuring 18×10×18 mm with viable ovarian tissue.

DISCUSSION

The case described above is uncommon as both the ovary and associated haemorrhagic cyst of 7×3 cm had torted. Differentiating appendicitis from ovarian torsion is difficult as they present in very similar ways. It is often thought that ovarian torsion is secondary to a cyst or ovarian tumour.⁴ However, other theories have been proposed to



© BMJ Publishing Group Limited 2021. Re-use permitted under CC BY-NC. No commercial re-use. See rights and permissions. Published by BMJ.

To cite: Kapoor S, Saeed S, Balasubramaniam D. *BMJ Case Rep* 2021;**14**:e239188. doi:10.1136/bcr-2020-239188

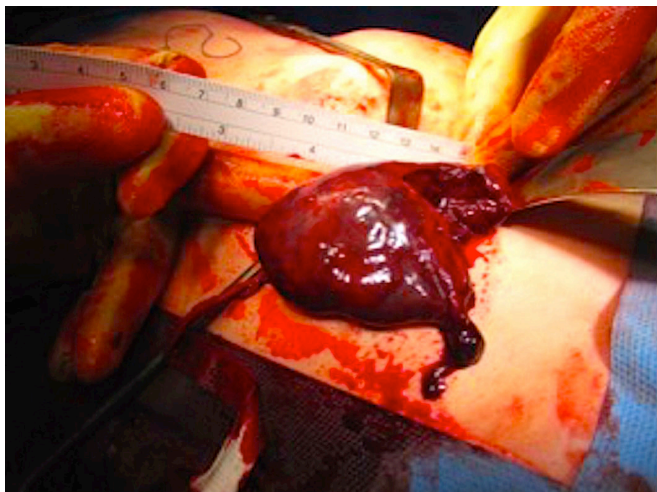


Figure 1 Intraoperative images of torted haemorrhagic cyst and ovary.

explain torsion in a regular ovary, including excessive movements secondary to a predisposing long utero-ovarian ligament.⁵

Appendicitis is considered a clinical diagnosis, with blood tests and imaging playing a supportive role. In our case, there was enough clinical suspicion to warrant early surgical intervention. While an ultrasound scan may have diagnosed the true pathology preoperatively, there was a low clinical suspicion of a gynaecological pathology in a prepubertal patient. Research suggests sonography alone to be inconclusive in this age group.⁶ Doppler ultrasound scans should be considered as they offer the greatest sensitivity and specificity compared with MRIs and CT.^{6,7}

Traditional surgical intuition would be to remove a structure that appeared ischaemic and non-viable. However, current evidence suggests that the cyst and ovary should be left in situ as there is potential for the ovary to function as normal.¹ The necrotic appearance of the ovary is more a consequence of venous congestion as oppose to arterial insufficiency. Therefore, detorsion alone can provide a good chance of recovery. Long-term follow-up of adult females following detorsion of an ovary has shown folliculogenesis on ultrasonography and successful pregnancies.³ Traditionally, oophorectomies have been performed due to the potential of missing a malignant cause. However, further evidence is required to support this.^{1,8}

Resected ovarian specimens have shown the presence of viable parenchyma despite their necrotic appearance advocating for the use of ovarian sparing surgery. Laparoscopic surgery can be used for ovarian cysts measuring less than 7.5 cm and a laparotomy for those that are larger.⁹ The initial approach should be for detorsion alone. The patient must be followed up with regular ultrasound scans. Absence of cyst regression warrants further investigation with CT and tumour markers.⁹

Regardless of the underlying pathology, it was clear operative management was needed in this case. In the absence of a dedicated paediatric surgical service, an open approach is commonly adopted; especially in smaller patients. This patient may have benefited from a laparoscopic approach, as it would have facilitated quick identification of the underlying pathology and management could have proceeded without extending the incision. Nonetheless, the patient has recovered well and her follow-up imaging have shown promising results for future fertility.

Patient's perspective

When I was informed that my daughter's pain had not been caused by appendicitis but due to her right cystic ovary having twisted, although I was relieved the cause had been discovered and rectified, I also felt confused as to how a large cyst had developed in her ovary at such a young age and concerned about her future fertility prospects.

Learning points

- ▶ Ovarian torsion should always be considered as a differential diagnosis in all female patients with acute right iliac fossa pain and raised inflammatory markers.
- ▶ Ultrasound scans can be particularly useful in the female population. However, it can be overlooked in children with such typical features of appendicitis.
- ▶ A laparoscopic approach can help identify pelvic pathology mimicking appendicitis. However, outside of centres for paediatric surgery, often an open approach is preferred, particularly in younger and smaller children.
- ▶ Attempts should be made to salvage torted ovaries regardless of the appearance.
- ▶ A follow-up ultrasound must be arranged to ensure regression of the cyst.

Contributors SK has written the case report with contribution from both SS and DB.

Funding The authors have not declared a specific grant for this research from any funding agency in the public, commercial or not-for-profit sectors.

Competing interests None declared.

Patient consent for publication Parental/guardian consent obtained.

Provenance and peer review Not commissioned; externally peer-reviewed.

Open access This is an open access article distributed in accordance with the Creative Commons Attribution Non Commercial (CC BY-NC 4.0) license, which permits others to distribute, remix, adapt, build upon this work non-commercially, and license their derivative works on different terms, provided the original work is properly cited and the use is non-commercial. See: <http://creativecommons.org/licenses/by-nc/4.0/>.

ORCID iD

Smriti Kapoor <http://orcid.org/0000-0003-0122-9213>

REFERENCES

- 1 Dasgupta R, Renaud E, Goldin AB, *et al*. Ovarian torsion in pediatric and adolescent patients: a systematic review. *J Pediatr Surg* 2018;53:1387–91.
- 2 Millar DM, Blake JM, Stringer DA, *et al*. Prepubertal ovarian cyst formation: 5 years' experience. *Obstet Gynecol* 1993;81:434–8.
- 3 Naffaa L, Deshmukh T, Tumu S, *et al*. Imaging of Acute Pelvic Pain in Girls: Ovarian Torsion and Beyond☆. *Curr Probl Diagn Radiol* 2017;46:317–29.
- 4 Tsai T-C, Wong LY, Wu H-P. Ovarian torsion caused by teratoma masquerading as perforated appendicitis in a 5-year-old girl. *Pediatr Neonatol* 2011;52:51–4.
- 5 Kokoska ER, Keller MS, Weber TR. Acute ovarian torsion in children. *Am J Surg* 2000;180:462–5.
- 6 Ochsner TJ, Roos JA, Johnson AS, *et al*. Ovarian torsion in a three-year-old girl. *J Emerg Med* 2010;38:e27–30.
- 7 Ashwal E, Krissi H, Hiersch L, *et al*. Presentation, diagnosis, and treatment of ovarian torsion in Premenarchal girls. *J Pediatr Adolesc Gynecol* 2015;28:526–9.
- 8 Hoey BA, Stawicki SP, Hoff WS, *et al*. Ovarian torsion associated with appendicitis in a 5-year-old girl: a case report and review of the literature. *J Pediatr Surg* 2005;40:e17–20.
- 9 Galinier P, Carfagna L, Delsol M, *et al*. Ovarian torsion. management and ovarian prognosis: a report of 45 cases. *J Pediatr Surg* 2009;44:1759–65.

Copyright 2021 BMJ Publishing Group. All rights reserved. For permission to reuse any of this content visit <https://www.bmj.com/company/products-services/rights-and-licensing/permissions/>
BMJ Case Report Fellows may re-use this article for personal use and teaching without any further permission.

Become a Fellow of BMJ Case Reports today and you can:

- ▶ Submit as many cases as you like
- ▶ Enjoy fast sympathetic peer review and rapid publication of accepted articles
- ▶ Access all the published articles
- ▶ Re-use any of the published material for personal use and teaching without further permission

Customer Service

If you have any further queries about your subscription, please contact our customer services team on +44 (0) 207111 1105 or via email at support@bmj.com.

Visit casereports.bmj.com for more articles like this and to become a Fellow