

Video Abstracts

## Isolated Propriospinal Myoclonus as a Presentation of Cervical Myelopathy

Paula Marrero-González<sup>1</sup>, Berta Pascual-Sedano<sup>1,5</sup>, Alejandro Martínez-Domeño<sup>1</sup>, L. Estefanía Díaz-Polo<sup>2</sup>, Esther Granell<sup>3</sup>, Rodrigo Rodríguez<sup>4</sup>, Alexandre Gironell<sup>1,5</sup> & Daniel Guisado-Alonso<sup>1\*</sup>

<sup>1</sup> Department of Neurology, Hospital de la Santa Creu i Sant Pau, Universitat Autònoma de Barcelona, Barcelona, ES, <sup>2</sup> Department of Pediatric Oncology and Hematology, Hospital de la Santa Creu i Sant Pau, Universitat Autònoma de Barcelona, Barcelona, ES, <sup>3</sup> Department of Neuroradiology, Hospital de la Santa Creu i Sant Pau, Universitat Autònoma de Barcelona, Barcelona, ES, <sup>4</sup> Department of Neurosurgery, Hospital de la Santa Creu i Sant Pau, Universitat Autònoma de Barcelona, Barcelona, ES, <sup>5</sup> CibERNed (Center of Biomedical Network Research on Neurodegenerative Diseases), ES

### Abstract

**Background:** Propriospinal myoclonus is an infrequent type of hyperkinetic movement that can be commonly idiopathic but also may occur after spinal cord lesions.

**Phenomenology Shown:** We describe an 8-year-old female showing repetitive flexor and extensor arrhythmic brief jerks of the trunk, compatible with propriospinal myoclonus secondary to cervical myelopathy.

**Educational Value:** Isolated propriospinal myoclonus may be the clinical sign that leads to the diagnosis of incipient myelopathy.

**Keywords:** Clinical neurology examination, myoclonus, propriospinal myoclonus, spinal cord, Arnold–Chiari, sickle-cell disease

**Citation:** Marrero-González P, Pascual-Sedano B, Martínez-Domeño A, Díaz-Polo LE, Granell E, Rodríguez R, et al. Isolated propriospinal myoclonus as a presentation of cervical myelopathy. Tremor Other Hyperkinet Mov. 2018; 8. doi: 10.7916/D8GQ8FNJ

\*To whom correspondence should be addressed. E-mail: dguisado@santpau.cat

**Editor:** Elan D. Louis, Yale University, USA

**Received:** August 12, 2018 **Accepted:** October 11, 2018 **Published:** November 26, 2018

**Copyright:** © 2018 Marrero-González et al. This is an open-access article distributed under the terms of the Creative Commons Attribution–Noncommercial–No Derivatives License, which permits the user to copy, distribute, and transmit the work provided that the original authors and source are credited; that no commercial use is made of the work; and that the work is not altered or transformed.

**Funding:** None.

**Financial Disclosures:** None.

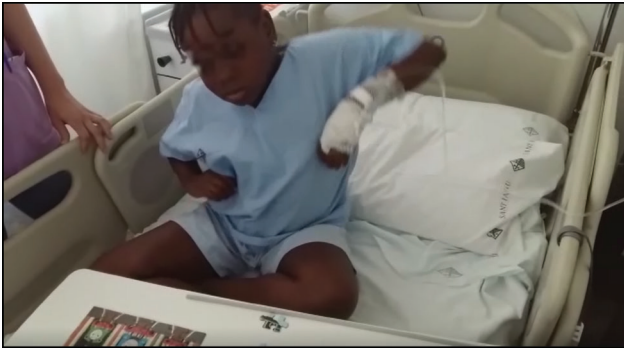**Conflicts of Interest:** The authors report no conflict of interest.

**Ethics Statement:** All patients that appear on video have provided written informed consent; authorization for the videotaping and for publication of the videotape was provided.

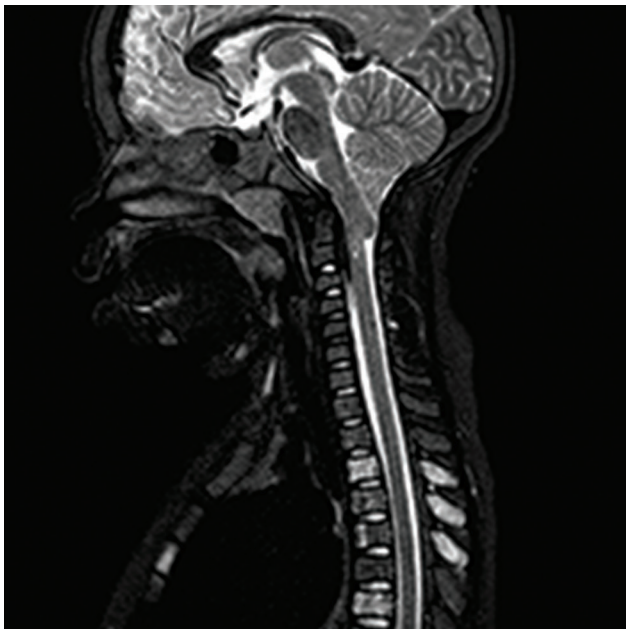
We present an 8-year-old girl with sickle cell disease (SCD) who was referred to our hospital because of bone infarctions. The patient developed bone pain three weeks before the admission and a bone scintigraphy showed bone infarctions in D9-L3 vertebral bodies. Hyperhydration, hydroxyurea and analgesia with non-steroidal anti-inflammatory drugs and opioid derivatives were initiated. The patient did not have other medical conditions.

Two months before admission, the patient presented with sudden involuntary movements consisting of repetitive flexor and extensor arrhythmic and anarchic brief jerks of the trunk (Video 1). These jerks were involuntary; the patient could not control them. The movements appeared spontaneously but also were stimulus sensitive, triggered by a gentle touch to the scalp around the ears. The jerks were painless, extended caudally, increased slightly when supine, were absent during sleep, and had no facial involvement. The rest of the neurological

examination was normal. She did not complain of headaches spontaneously, but when she was asked the patient described a mild oppressive occipital headache in the last 4–5 months that did not get worse with Valsalva maneuvers. Surface electromyography was performed in the rectus abdominis and elbow flexor and extensor muscles, revealing arrhythmic bursts of >100 ms length and rostrocaudal conduction with axial muscle predominance and involvement of the distal segment and other spinal segments. Conduction velocities were not measured. Reticular myoclonus was ruled out because the absence of facial involvement that indicated caudorostral conduction and segmental myoclonus, which, in contrast to this case, is usually confined to one or few contiguous myotomes and the jerks are commonly rhythmic and not sensitive to stimulus. Therefore clinical phenomenology and electrophysiologic features were suggestive of propriospinal myoclonus.<sup>1,2</sup>



**Video 1. Propriospinal Myoclonus.** Sudden and involuntary movements consisting in repetitive flexor and extensor arrhythmic and anarchic brief jerks of the trunk. The movements are spontaneous, painless and with no facial involvement.



**Figure 1. Magnetic Resonance Imaging (MRI) Findings.** Short tau inversion recovery sequence of MRI showing high signal intensity in the cervical spine at the C1–C2 level corresponding to spinal cord compression due to herniation of the cerebellar tonsils through the foramen magnum (Arnold–Chiari type I malformation).

Cervical C1–C2 myelopathy due to Arnold–Chiari malformation (ACM) type 1 was evidenced by magnetic resonance imaging (MRI) (Figure 1). Cerebral MRI did not show any ischemic lesions and the neurosonological study did not indicate increased risk of stroke. Electroencephalography was normal. Toxic–metabolic causes were ruled out. Suboccipital craniectomy and cervical laminectomy of the C1 posterior arch were performed. A few days after neurosurgical decompression of the foramen magnum, the myoclonus disappeared. The temporal relationship of clinical improvement with surgery was clear; there was no evidence of vaso-occlusion that caused ischemic damage to the central nervous system and the other conditions remained unchanged: the painful bone infarction persisted and the same analgesics continued to be administered. Consequently, in this case propriospinal myoclonus was probably secondary to structural cervical myelopathy because of ACM.

ACM does not have a higher prevalence in patients with SCD, nevertheless it should be considered in the differential diagnosis of neurological symptoms in these patients.<sup>3</sup>

Finally, we would like to emphasize that isolated propriospinal myoclonus may be the clinical sign that leads to the diagnosis of incipient myelopathy. A broad study must be done in order to rule out secondary etiologies when we face patients with this clinical presentation.

### Acknowledgments

The authors wish to thank Carla Temprano for editing the video and James Shaw for reviewing the English.

### References

1. Roze E, Bounolleau P, Ducreux D, Cochen V, Leu-Semenescu S, Beaugendre Y, et al. Propriospinal myoclonus revisited: clinical, neurophysiologic, and neuroradiologic findings. *Neurology* 2009;72:1301–1309. doi: 10.1212/WNL.0b013e3181a0fd50
2. van der Salm SM, Erro R, Cordivari C, Edwards MJ, Koelman JHTM, van den Ende T, et al. Propriospinal myoclonus: clinical reappraisal and review of literature. *Neurology* 2014;83:1862–1870. doi: 10.1212/WNL.0000000000000982
3. Jordan LC, McKinstry III RC, Kraut MA, Ball WS, Vendt BA, Casella JF et al. Incidental findings on brain magnetic resonance imaging of children with sickle cell disease. *Pediatrics* 2010;126:53–61.