

PRIMARY LUNG TUMORS IN MICE FOLLOWING THE  
CUTANEOUS APPLICATION OF COAL TAR.\*

BY JAMES B. MURPHY, M.D., AND ERNEST STURM.

(From the Laboratories of The Rockefeller Institute for Medical Research.)

PLATES 35 AND 36.

(Received for publication, June 23, 1925.)

It has been a not unusual observation in our experience that mice failing to develop skin cancer as the result of the application of coal tar are found to have tumors of the lungs. The first explanation of the pulmonary tumors which suggests itself is that a cancer of the skin had occurred as a result of the tar, had given off a metastasis to the lung, and had then either healed or sloughed out. But frequent and careful examination of the animals during life failed to show any lesions of the skin suggesting cancer, and at autopsy there were no scars or other evident abnormalities in the painted areas. Furthermore, histological examination of the nodules in the lungs revealed a structure and a type of cell different from the metastases which occur from the tar skin cancers. Spontaneous tumors in the mouse lung have been frequently observed but they rarely occur in such young animals or in such a high proportion of individuals as in our experiments. In the following experiments we have attempted to eliminate completely the probability of skin lesions while determining the influence of the external application of tar on the incidence of primary tumors of the lungs.

*Experimental Method.*

It is well known that the induction of skin cancer in mice by the application of coal tar requires frequently repeated applications of this agent. With the product used in this laboratory three applications weekly for 3 months suffice to induce cancer in a fair proportion

\* This investigation was carried out by means of funds from the Rutherford Donation.

of the animals. When a high rate of incidence is desired it is necessary to continue the paintings for 4 months.

*Tar Preparation.*—The tar product used throughout these experiments had for its base the residue from a coke oven in which the crude tar had been distilled at a temperature of approximately 377°C.<sup>1</sup> This hard residue was pulverized and extracted with benzene. The soluble fraction was concentrated, washed first with 12 per cent NaOH, and then with 30 per cent H<sub>2</sub>SO<sub>4</sub>. The precipitates were removed and the benzene fraction was then evaporated down until all of the excess benzene had been removed.<sup>2</sup>

*Method of Application.*—The tar was applied by means of a swab to an area of skin somewhat less than a centimeter in diameter. There were twelve such areas on the surface of each mouse, painted in rotation according to the following scheme.

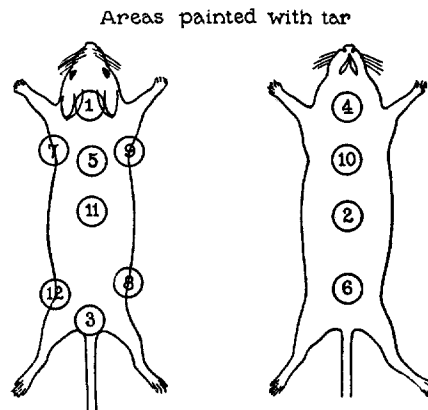
Area.	Days of application of tar.			Area.	Days of application of tar.		
1	1	29	57	7	15	43	71
2	3	31	59	8	17	45	73
3	6	34	62	9	20	48	76
4	8	36	64	10	22	50	78
5	10	38	66	11	24	52	80
6	13	41	69	12	27	55	83

By this method each mouse received thirty-six applications of tar distributed over 83 days. Each individual area received three applications during this time with practically a month between each painting. The selection of the areas and the order in which they were painted were so arranged as to avoid the possibility of overlapping of tarred spots. The location of the areas and the order in which they were painted are shown in Text-fig. 1.

<sup>1</sup> This material was kindly furnished by the Barrett Company.

<sup>2</sup> For details of preparation see Murphy, Jas. B., and Landsteiner, K., *J. Exp. Med.*, 1925, xli, 807.

*Experiment 1.*—20 mice from 3 to 4 months old, selected from a fairly uniform stock with an extremely low cancer incidence, were painted with tar according to the above scheme. Of these 12 survived for from 1 month to 6 months after the tar paintings had been stopped. When killed 10 of the 12 showed one or more pearly white nodules in the lungs varying in size from 1 to 4 mm. in diameter. There was no detectable change in the skin of the painted regions. Microscopic examination of the lung nodules showed them to be typical epithelial tumors in eight of the specimens. In the other two instances the nodules were lost. The



TEXT-FIG. 1.

lung tumor rate for this experiment was 66.6 per cent, as confirmed by histological examination, and 83.3 per cent if the 2 animals are included in which the diagnosis was made only on the gross specimen.

As a control to this experiment 22 mice from the same stock ranging in age from 8 months to a year, and kept under the same laboratory conditions, were killed. Careful examination of the lungs failed to show a single instance of tumor.

*Experiment 2.*—A second group of mice was subjected to the same system of tar applications as that used in Experiment 1. All but 5 of the animals were lost in an epidemic early in the experiment. The surviving animals were killed 6 months after the last tar application and 3 of the 5 were found to have tumors of the lungs, confirmed by microscopic examination, and 1 a tumor of the uterus. The tumor incidence for this experiment was thus 80 per cent and there were lung tumors in 60 per cent.

*Experiment 3.*—This group was made up of 40 mice between 2 and 3 months old, selected from a fairly uniform stock known to have a low tumor incidence. The animals were painted with tar in the same fashion as in Experiment 1. About 4 months after the last application 23 of them were killed. The skin showed no alteration in the painted regions. In 2 animals the lungs were normal but in all of the remaining 21 there were pearly white nodules in these organs. As many as 15 such tumors were found in the lungs of 1 animal. In diameter they varied from 1 to 4 mm. (Text-fig. 2). Microscopic examination showed the growths to be epithelial tumors of the same type as those in the preceding experiments in 18 of the 23 animals. The age of the mice at the time they were killed was between 9 and 10 months.

For controls a group of 16 untreated mice from the same stock, but from 1 to 6 months older than the experimental animals, was kept under the same conditions and killed at the same time. The age of these mice at the time they were killed ranged from 12 to 16 months. In not a single instance was a tumor of the lung or other organ encountered. The tumor incidence for the painted animals was in this experiment 78.3 per cent as compared with 0.0 per cent for the controls.

*Character of the Tumors.*—The cells making up the tumors are fairly large, cuboidal or ovoid in shape, usually lying in a single layer on either side of a thin shred of stroma (Figs. 1 to 4). The general pattern gives the impression that the tumor is composed of closely packed folds of an epithelial cord. There is some variation in the density of the tumors and in the amount of stroma, but the general histologic type is uniform. Mitotic figures are present in fair number. As a rule the tumors are sharply demarcated from the surrounding lung tissue but it is not uncommon to find finger-like processes invading the lung tissue. Occasionally there is some reaction at the edge of the growth and an inflammatory condition in the neighboring lung tissue but this is an exceptional finding.

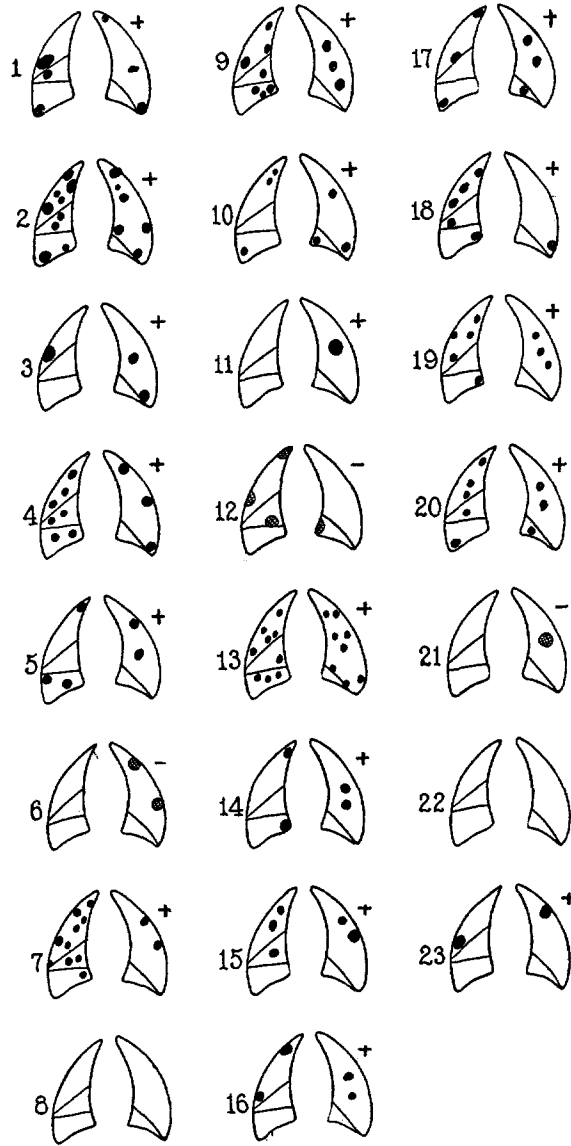
The growths are identical in structure with those described as primary tumors of the lung in mice by Livingood,<sup>3</sup> Haaland,<sup>4</sup> Tyzzer,<sup>5</sup> and Murray.<sup>6</sup> They have been variously designated as adeno-

<sup>3</sup> Livingood, L. E., *Bull. Johns Hopkins Hosp.*, 1896, vii, 177.

<sup>4</sup> Haaland, M., *Ann. Inst. Pasteur*, 1905, xix, 165.

<sup>5</sup> Tyzzer, E. E., *J. Med. Research*, 1907-08, xvii, 155.

<sup>6</sup> Murray, J. A., *3rd Scient. Rep. Imperial Cancer Research Fund*, London, 1908.



TEXT-FIG. 2. Schematic representation of the relative size and number of tumors in the lungs of mice from Experiment 3. The solid black areas indicate that the tumors had the gross appearance of new growths while those cross-hatched were of doubtful nature. The + indicates that a neoplasm was present on microscopic examination and - that no evidence of tumors was found.

carcinoma, papillary cystadenoma, and adenoma. However, judging by the descriptions and published illustrations there is but little variation amongst them and they unquestionably represent a distinct type of epithelial tumor.

#### DISCUSSION.

As already stated, spontaneous tumors of the lung are not uncommon in certain strains of mice. Tyzzer<sup>5</sup> has reported a high incidence in one of the groups he studied. Slye<sup>7</sup> has noted such tumors in some of her strains. In our tumor stock it is rare to find a lung tumor in animals 12 months old or younger, while the highest rate comes between 26 and 29 months of age.<sup>8</sup> In the case of two special strains, with a lung tumor rate between 59 and 70 per cent, in only one instance has a tumor occurred in a mouse as young as 13 months while the average age is about 20 months. With these facts before us we have attempted to eliminate as completely as possible the chance of spontaneous tumors from our experimental material. In Experiment 1 all but four of the mice were killed before they were 11 months old and the remaining four were killed at 13 months. In Experiment 3 all of the animals were from 9 to 10 months old at the time they were killed and the control mice were from 12 to 16 months old. Therefore it can be definitely said that all of the experimental animals were below the age at which spontaneous lung tumors occur in even a high tumor strain and that they were from a stock showing no lung tumors even at a more advanced age than the experimental animals.

The mechanism of the tar action is not clear. The experiment effectually eliminated the possibility that the lung tumors are in the nature of metastases from skin cancers. Two other possibilities may be considered; *i.e.*, that tar particles get into the lungs through the lymphatics; or that the tar painting so alters the body state that tumors occur at points of incidental irritation at which under ordinary circumstances they would not develop. The first possibility seems a little far fetched. The tar particles might be absorbed through the skin or the alimentary canal since some of the tar is licked off by the animals. In either case the tar would have to pass through at least

<sup>7</sup> Slye, M., Holmes, H. F., and Wells, H. G., *J. Med. Research*, 1914, xxx, 417.

<sup>8</sup> Observations in process of publication.

one set of lymph glands in case it was to reach the lungs. The possibility of the inhalation of particles can be eliminated as the tar is usually either licked or rubbed off before it dries. When some does adhere it becomes very hard and is powdered with difficulty.

In support of the second hypothesis we have accumulated a large amount of data which go to show that the repeated application of tar greatly reduces an animal's resistance to transplanted cancer.<sup>9</sup> Animals of tested resistance, either natural or induced, may be rendered susceptible to a subsequent transplant by tar application. Granting that the application of tar reduces the general resistance to cell growth, is there any evidence that the lungs are the site of irritant processes such as might conceivably act to precipitate the development of neoplasms? Our mice lived in burrows under sawdust and shavings mixed with chopped hay. There is every probability that the inhalation of some small foreign particles resulted in irritation. As a matter of fact inflamed areas are not uncommon findings in the lungs of mice. This hypothesis seems to us the most feasible but further work would be required to establish it.

#### SUMMARY.

The external application of tar to a number of separated areas on the surface of mice, in such fashion that no single area is irritated sufficiently long to cause lesions of the skin, has resulted in a very high incidence of lung tumors. This incidence ranged from 60.0 per cent in one experiment to 78.3 per cent in another. Control mice from the same stock but from 3 to 6 months older, and for that reason the more liable to spontaneous lung tumors, failed to show a single instance of such growths. Even in a stock in which spontaneous lung tumors had been frequent, the incidence for corresponding age periods has never been above 5.5 per cent while the average has been between 1 and 2 per cent over a period of years. The tumors in the tar-painted animals occur as small white nodules, either single or multiple. They are typical epithelial neoplasms, identical histologically with those described by previous authors as occurring spontaneously in mice.

Some possible factors in the causation of the tumors are briefly discussed.

<sup>9</sup> The data will be published in full in a subsequent article.

## EXPLANATION OF PLATES.

## PLATE 35.

FIG. 1. Low power photomicrograph of a section through the lower lobe of the lung of a mouse which had received external applications of tar.

FIG. 2. A photomicrograph of an earlier stage of a primary tumor of the lung following external applications of tar.

## PLATE 36.

FIG. 3. A primary tumor of the lung following external applications of tar.

FIG. 4. A high power photomicrograph of a lung tumor in a tar-painted mouse, showing mitotic figures.



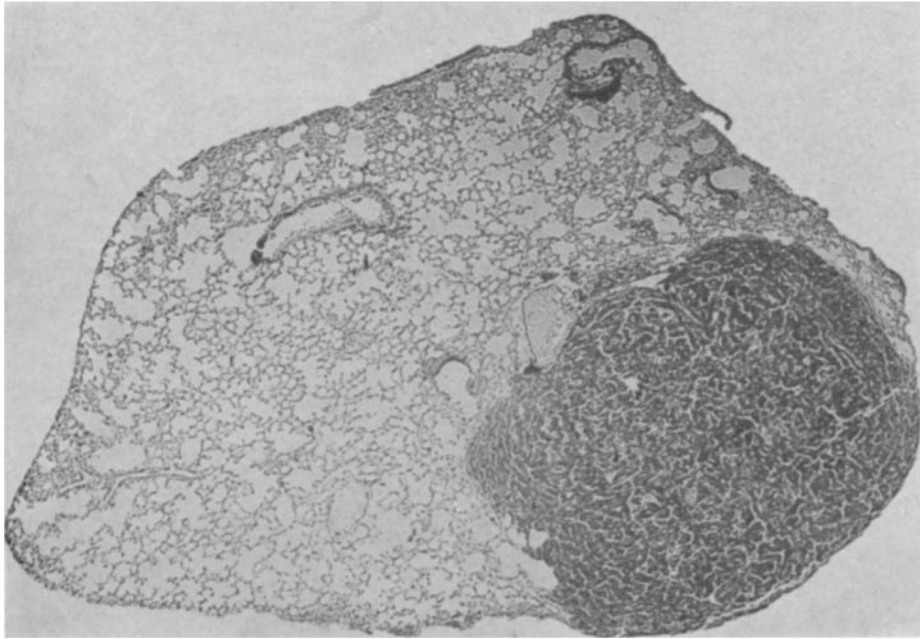


FIG. 1.

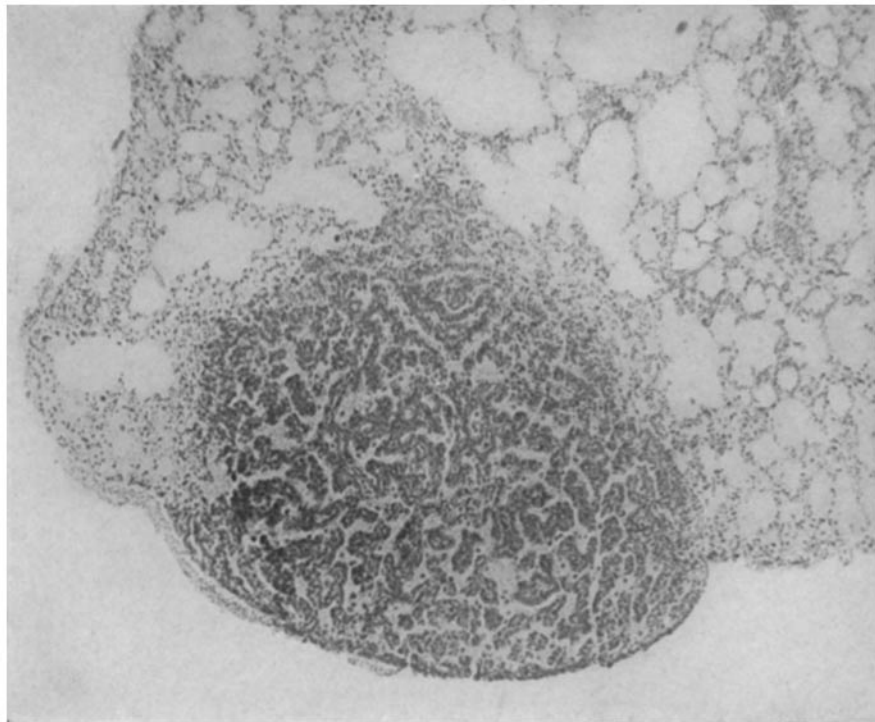


FIG. 2.

(Murphy and Sturm: Primary lung tumors in mice.)

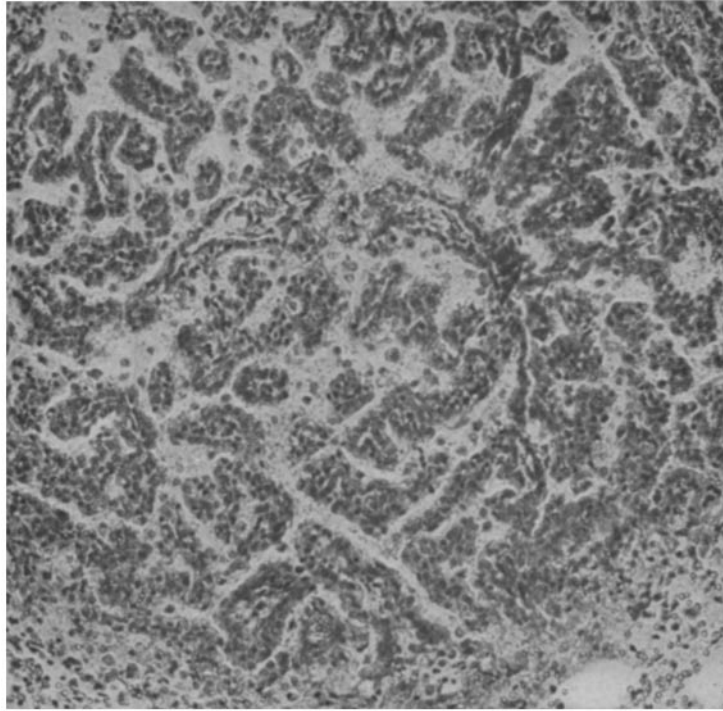


FIG. 3.

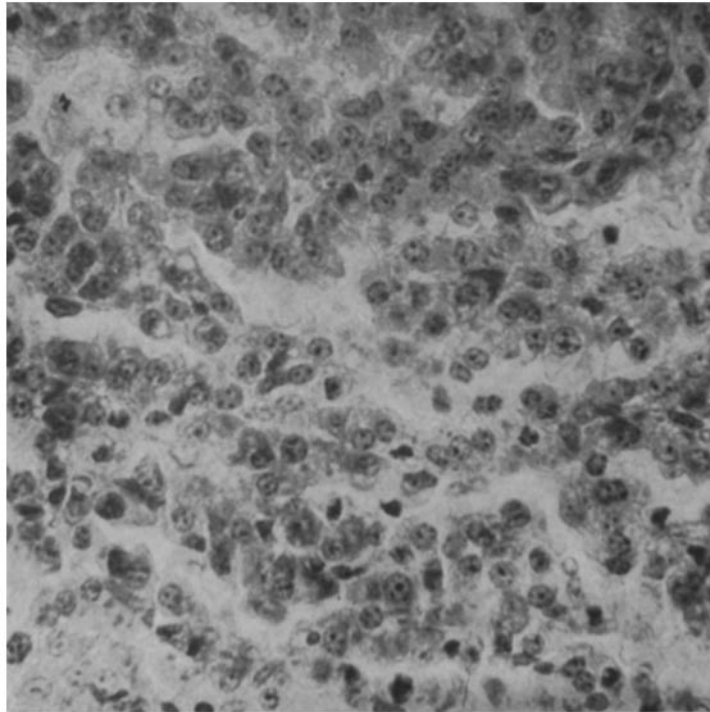


FIG. 4.

(Murphy and Sturm: Primary lung tumors in mice.)