

Current Methods for the Treatment of Alveolar Cleft

Nak Heon Kang

Department of Plastic and Reconstructive Surgery, Chungnam National University School of Medicine, Daejeon, Korea

Alveolar cleft is a tornado-shaped bone defect in the maxillary arch. The treatment goals for alveolar cleft are stabilization and provision of bone continuity to the maxillary arch, permitting support for tooth eruption, eliminating oronasal fistulas, providing an improved esthetic result, and improving speech. Treatment protocols vary in terms of the operative time, surgical techniques, and graft materials. Early approaches including boneless bone grafting (gingivoperiosteoplasty) and primary bone graft fell into disfavor because they impaired facial growth, and they remain controversial. Secondary bone graft (SBG) is not the most perfect method, but long-term follow-up has shown that the graft is absorbed to a lesser extent, does not impede facial growth, and supports other teeth. Accordingly, SBG in the mixed dentition phase (6–11 years) has become the preferred method of treatment. The most commonly used graft material is cancellous bone from the iliac crest. Recently, many researchers have investigated the use of allogeneic bone, artificial bone, and recombinant human bone morphogenetic protein, along with growth factors because of their ability to decrease donor-site morbidity. Further investigations of bone substitutes and additives will continue to be needed to increase their effectiveness and to reduce complications.

Keywords Alveolar bone grafting / Bone substitutes / Bone morphogenetic proteins

Correspondence: Nak Heon Kang
Department of Plastic and Reconstructive Surgery, Chungnam National University School of Medicine, 282 Munhwa-ro, Jung-gu, Daejeon 35015, Korea
Tel: +82-42-280-7385
Fax: +82-42-280-7384
E-mail: nhk488@cnu.ac.kr

No potential conflict of interest relevant to this article was reported.

Received: 30 Jan 2017 • Revised: 15 Apr 2017 • Accepted: 21 Apr 2017

pISSN: 2234-6163 • eISSN: 2234-6171 • <https://doi.org/10.5999/aps.2017.44.3.188> • Arch Plast Surg 2017;44:188-193

INTRODUCTION

Alveolar cleft occurs in response to divergence from normal development during frontonasal prominence growth, contact, and fusion. The most common alveolar portion of the cleft is located between the lateral incisor and the canine. Reconstruction of the alveolar cleft was introduced by von Eiselsberg [1] using autologous tissue, while Lexer [2] first described a nonvascular bone graft. Drachter [3] reported the repair of an alveolar cleft using the tibial bone, and Schmid [4] first utilized this procedure for implanting iliac bone grafts into the bony gap. Skoog [5] developed a boneless bone graft technique known as gingivoperiosteoplasty. Until the 1970s, primary bone grafting

(PBG) with rib bone at the infant stage was the main surgical procedure used to treat alveolar cleft [6]. However, negative responses to PBG, such as midface retrusion and anterior cross-bite, have been reported upon closer examination and over the course of long-term follow-up. In contrast, positive responses to secondary bone grafting (SBG) have been reported, and reconstruction of the alveolar cleft is performed most frequently in the mixed dentition period (between 6 and 11 years) [7]. Although various analytical methods have been proposed, it is difficult to determine the outcomes of bone grafting. Choi et al. [8] compared the amount of graft measured with preoperative 3-dimensional computed tomography (3D CT) to the amount actually used for surgery and found that 3D CT could accurately

measure the amount of bone graft needed prior to surgery. Recently, low-dose maxillary 3D cone-beam computed tomography (CBCT) has been widely used for preoperative planning and postoperative evaluations. Amirlak et al. [9] compared the amount of bone defect to the amount of graft by using CBCT before and after simulated surgery. Methods for using materials such as allogeneic freeze-dried bone (FDB), demineralized freeze-dried bone (DFDB), demineralized bone matrix (DBM), and recombinant human bone morphogenetic protein (rh-BMP) have also been investigated to reduce the morbidity of donor sites and to obtain good results [10].

SECONDARY ALVEOLAR BONE GRAFTING

Secondary repair is divided into early, conventional, and late grafting. Early secondary repair usually occurs between 2 years and 5 or 6 years before the eruption of permanent teeth after complete eruption of the primary dentition. Transitional (conventional) secondary repair is performed in the mixed dentition stage, and late secondary (tertiary) repair is performed after permanent eruption. The purpose of SBG is to eliminate oronasal communication and prevent the retention of food particles in order to improve oral hygiene and prevent inflammation [11]. This method also stabilizes the maxillary segment and improves facial aesthetics and symmetry by inducing tooth eruption, orthodontic movement of the teeth, nasal support, and projection with appropriate alveolar bone support. Initially, it was not important to cover the grafted bone and little attention was paid to flap design. However, since Abyholm et al. [12] first discussed the importance of flap design in 1981, completely covering the implanted bone with the elevated mucoperiosteal flaps without tension after the bone graft (watertight closure) has been considered one of the most important factors affecting the surgical outcome. When performing SBG, special care should be taken to not cause inflammation by opening the nasal lining. Semb [13] reported on the basis of a long-term evaluation that SBG did not affect the anteroposterior or vertical maxillary growth. Chang et al. [14] reported that no difference in maxillofacial growth was observed in the cephalograms of a bone-grafted group and a non-grafted group. Several other researchers have also investigated tooth eruption. Troxell et al. [15] reported that tooth eruption occurred through a bone graft in 9% of cases, while El Deeb et al. [16] reported that tooth eruption was observed in only 27% of the bone graft recipients. Appropriate bone graft thickness is also important because a prosthetic tooth can be inserted into the bone-grafted alveolar bone in the absence of teeth eruption [7].

Source of bone graft material

Both cortical and cancellous bones can be used for a bone graft, but cancellous bone is known to be better because of the cell transfer and revascularization in osteoinduction and osteoconduction. A variety of autologous, allogeneic, and xenogeneic bone materials; rhBMP; and growth factors have been used for correcting alveolar cleft. Of these, fresh autologous cancellous bone is the ideal bone graft source [17].

Iliac crest

Iliac bone is the most commonly used bone in bone grafting because it is easy to harvest, it can provide a large amount of cancellous bone, and cleft preparation can be performed at the same time. However, the disadvantages of using this bone are possible scarring, postoperative pain, delayed ambulation, and risk of cutaneous nerve injury. To reduce complications, limited incision, minimal musculature elevation, meticulous hemostasis, reapproximation of the cartilage cap, adequate pain control, and early ambulation should be employed. Ilankovan et al. [18] reported that sufficient cancellous bone could be obtained using the trephine technique. Sharma et al. [19] reported that bone harvesting with a power-driven trephine system resulted in reduced operative time and length of hospital stay, low pain scores, and low analgesic use.

Cranium

The cranium has little resorption, less postoperative pain, and the advantage of a concealed scar. According to Hudak et al. [20], the survival rate of cranial bone grafts is approximately 85.0%, which is similar to that of iliac bone grafts reported by Oberoi et al. [21] (84%). However, a long operative time and serious side effects such as hematoma, seroma, dural tear, dural exposure, and cerebrospinal fluid leakage are possible [22].

Tibia

The use of the tibia results in less bleeding, postoperative pain, operative time, and scarring, as well as faster ambulation and a shorter hospital stay. However, most studies are based on the collection of relatively small amounts of bone in adult patients, and it may be necessary to obtain the product from both legs if a large amount is required. Moreover, its success in children is poor because of the possibility of growth disturbance due to injury of the epiphyseal cartilage [18].

Mandibular symphysis

The mandible has the same embryonic origin as the maxilla. Because it is a membranous bone, revascularization is relatively fast and resorption is low. Surgery can be performed in the same

operative field and postoperative discomfort is reduced, thus reducing the length of the hospital stay. However, there is a risk of canine, incisor root, and mental nerve damage, and the amount that can be collected depends on the development of the mandible [23].

Bone-graft substitutes

There are several types of allogeneic bones that can be used as autologous graft substitutes in alveolar cleft repair. DFDB or DBM possess superior osteoinduction characteristics, and FDB, a mineralized bone, is known to have high osteoconduction activity [24]. With the advantages of both types of bone materials, these materials have been widely implanted together when replacing autologous bone. Although these substitutes have the advantage of reducing donor-site morbidities, infection, disease transmission, and host incompatibility have been reported [25]. Further, artificial bone materials such as hydroxyapatite (HA) and tricalcium phosphate (TCP) are mixed with rhBMP, but there may be teratogenic and carcinogenic effects because of overgrowth [26]. Recent studies investigating the addition of growth factors such as platelet-rich plasma (PRP) and platelet-rich fibrin (PRF) with graft materials have been carried out during bone grafting, but these methods have not yet been widely used [27]. In some studies, rhBMP has been used for maxillofacial surgical purposes and has been shown to be better than an autologous iliac bone graft, but the bone volume remaining after surgery has been found to be lower when this method is employed [28]. However, most studies using DBM and rhBMP have reported acceptable results. In addition, Francis et al. [29] compared the results in various ways and suggested the possibility of substituting an iliac bone graft for a bone graft by adding rhBMP to the DBM scaffold. Some studies of the application of this technique in spinal column repair surgery revealed significant operative site edema and resorption of vertebral bodies as postoperative complications. In animal studies, premature fusion and growth restriction of the suture line have been reported [28].

Surgical procedure

Under general anesthesia and vasoconstrictor infiltration, gingival mucoperiosteal flaps are designed along the cleft margins, and elevated medial and lateral mucoperiosteal flaps are generated from the cleft and the gingival sulcus of the teeth. To obtain adequate mobility of the posterior flap, the flap must be extended to the first or the second molar and back-cut up to the buccal sulcus while taking care not to injure the alveolar bone covering the roots of the teeth. These flaps are raised up to and around the piriform aperture, and then are separated from the nasal mu-

cosa. The palatal mucoperiosteal flaps along the cleft margins are then elevated from the palate. After complete exposure of all the bony clefts, the nasal lining of the nostril floor is approximated and sutured, and the palatal flaps are then turned back and sutured to make a soft-tissue pocket. Grafting of the defect is accomplished with a cancellous bone from the ilium. The grafted bone should be compressed into the cleft defect to maximize the number of osteo-competent cells and the osteoid material per unit graft volume. When packing bone particles, it is better to create the maxilla and alveolar ridges and elevate the depressed nostril by appropriately supporting the nasal base and aligning the symmetry. The rest can then be covered with gingival mucoperiosteal flaps through tension-free transposition (Figs. 1–3) [11,12].

In the case of bilateral clefts, the orthodontic alignment of the premaxilla is set and the cleft is repaired using a method similar to that used for repairing a unilateral alveolar cleft [8]. It is very important to design the mucoperiosteal flap to be sufficiently elevated and to seal the flap without tension, so that the grafted bone particles are not exposed. To accomplish this, there should be no excessive tension on the flap closure, particularly on the roof side of the defect, and the nasal lining site must be sealed watertight to prevent postoperative inflammation or infection.

Complications

An alveolar bone graft may be exposed by excessive tension or trauma during recovery after surgery. Minor exposure can be improved by conservative treatment, but bone graft exposure should be avoided if possible. Even if bone grafts are overpacked, graft resorption and alveolous notching can occur. Significant graft failure may occur in less than 5% of the patients, in which case reoperation is required [20]. Sivak et al. [30] reported that BMP or DBM was better than an autologous iliac bone graft after bone graft failure.

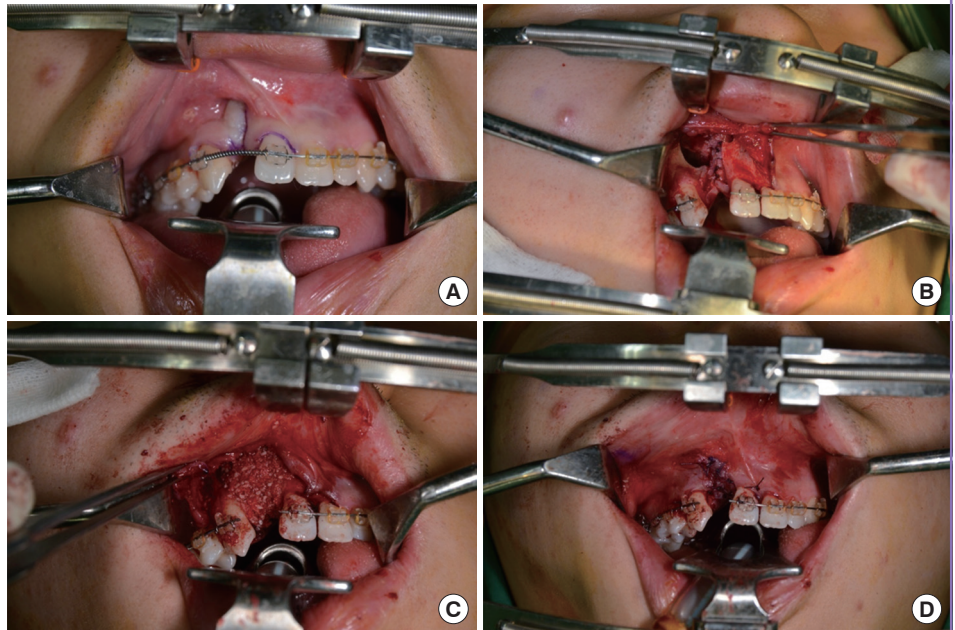
Survival of alveolar bone grafts

The results of bone grafts in patients with alveolar cleft can vary from a highly successful graft with minor reabsorption to a poor outcome with a small amount or a lack of bone bridging. Since Bergland et al. [31] introduced what is known as the Bergland scale in 1986 to quantify the amount of implanted bone, several researchers have proposed various methods such as the Enmark score, the Long rating scale, the Kindelan scale, and the Chelsea scale [32–35]. Recently, most methods for evaluating the results of an alveolar bone graft have used dental radiographs and CBCT.

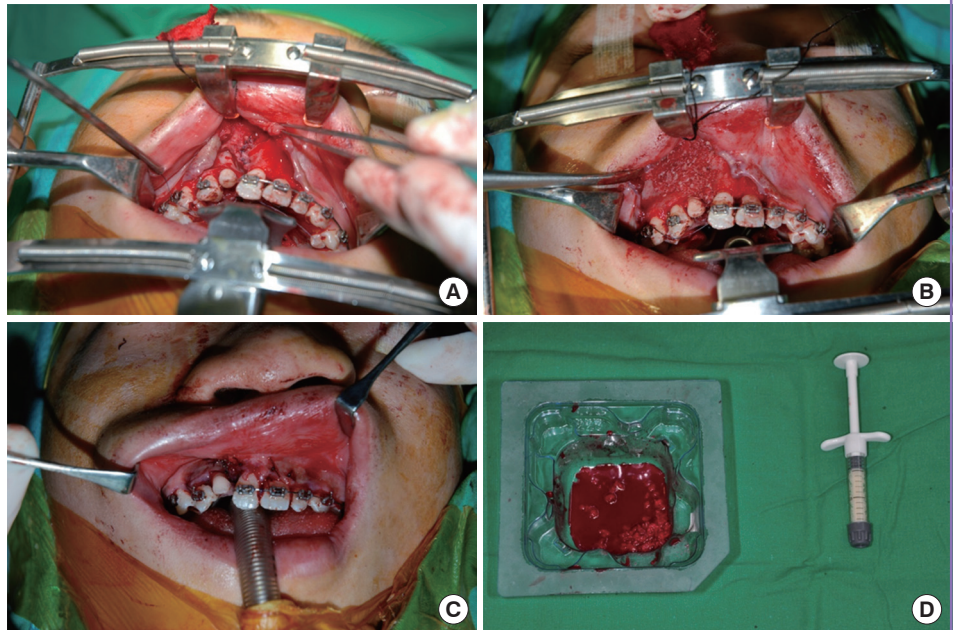
In 2007, Feichtinger et al. [36] evaluated the volumetric changes of 24 cases over 3 years. The grafted bone was absorbed

Fig. 1. Alveolar cleft repair

(A) Preoperative view of an unilateral alveolar cleft after the orthodontic alignment of maxillary segments and teeth. (B) The flaps were raised over the greater and lesser segments of the maxilla in the subperiosteal plane, and the cleft mucosa was separated from the labial mucosa. The author elevated the flap to the subperiosteal plane, leaving little gingival attachment. (C) Iliac cancellous bone graft was packed within the cleft defect. (D) The larger posterior mucoperiosteal flap was transposed across the labial surface of the graft and sutured to the anterior flap without tension. When closing the mucosal flap, it was important to repair it with a watertight graft so that the roots of the teeth were not exposed.

**Fig. 2. Unilateral alveolar cleft in a 12-year-old patient**

(A) The nasal lining of the floor and the palatal flaps were repaired. (B) Autologous cancellous bone mixed with DBM was packed in the cleft. (C) Tension-free coverage was obtained by redraping the mucoperiosteal flaps. (D) Autologous bone and DBM. DBM, demineralized bone matrix.

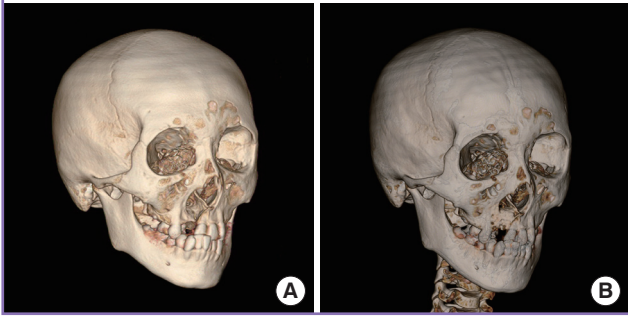

by 49.5% in the first year, and 52% in 3 years. In particular, an 8.0% increase in bone volume was reported. Honma et al. [37] studied the grafted bone-bridge volume of 15 cases at 3 months and 1 year postoperatively. The mean preoperative volume of the grafted bone was $1.1 \pm 0.3 \text{ cm}^3$ post-surgery, $1.2 \pm 0.6 \text{ cm}^3$ at 3 months postoperatively, and $1.1 \pm 0.5 \text{ cm}^3$ at 1 year postoperatively. However, 1 year after surgery, the volume showed a considerable degree of variability, ranging from 0.3 to 2.0 cm^3 . An-

other study by Trindade et al. [38] assessed 65 secondary alveolar bone grafts at a 1-year-postoperative follow-up. Of the 65 cases, 68%–71% were classified as Bergland type I, implying that the interdental septum height was normal, and 15% as Bergland type II, implying that the height was 75% of normal. In the rest of the cases, the absorption rate could not be measured, as the volume continued to change because of the orthodontic treatment and the eruption of the permanent teeth [38]. In a

Fig. 3. CT scans of alveolar cleft

(A) Preoperative and (B) 6-month postoperative CT scans of right-side alveolar cleft in an 11-year-old patient. CT, computed tomography.



5-year prospective study of 100 cases by Tan et al. [39], long-term changes in the grafted bone were assessed. At 5 years postoperatively, the authors reported that 88.9% of the patients with unilateral clefts and 84.6% of the patients with bilateral clefts were scored as Bergland type I, implying that the septal bone height was normal. Enemark et al. [32] observed 95 cases of unilateral and bilateral alveolar clefts for 4 years. Of these 95 patients, 76 exhibited no difference in the bone height, and in another 14 cases, the bone height changed to 75% of the normal alveolar bone height. It is reasonable to expect that the amount of grafted bone will change slightly over time. The observation that the grafted bone changes over a long period of time may be helpful in evaluating the surgical outcome.

CONCLUSIONS

Treatment of alveolar cleft has changed over the past century. The most widely accepted treatment protocol is grafting using autologous cancellous bone from the iliac crest in patients aged between 6 and 11 years, in the mixed dentition period. Although autologous bone is the ideal graft material, bone substitutes have been used in recent years because of limited bone retrieval. A combination of allogeneic demineralized bone, which has superior osteoinduction activity, with mineralized bone, which has high osteoconduction activity, low resorption, and good volume retention, is widely used as an alternative to autologous bone grafts. Further, growth factors such as PRP and PRF, and transplantation additives such as rhBMP have been used; rhBMP may be used by being mixed with an artificial bone material such as HA or TCP. The use of new technologies such as allogeneic, xenogeneic, and synthetic bones; rhBMP; and growth factors has been reported to reduce donor-site morbidity and can be particularly useful in the case of a lack of bone source or in complicated cases. However, alveolar bone grafting

must include autologous bone, and none of the currently available methods can replace autologous bone completely. Therefore, further studies investigating the ideal correction time, donor site, graft substitutes, and additives should be conducted.

REFERENCES

1. von Eiselsberg F. Zur technik der uranoplastik. *Arch Klin Chir* 1901;64:509-29.
2. Lexer E. Die Verwendung der freien knochenplastik nebst versucher uber gelenkversteifung und gelenktransplantation. *Arch Klin Chir* 1908;86:939-43.
3. Drachter R. Die Gaumenspalte und deren operative Behandlung. *Dtsch Z Chir* 1914;131:1-89.
4. Schmid E. Die aufbauende kieferkamm plastik. *Ost J Stomat* 1954;51:582-3.
5. Skoog T. The use of periosteum and Surgicel for bone restoration in congenital clefts of the maxilla: a clinical report and experimental investigation. *Scand J Plast Reconstr Surg* 1967;1:113-30.
6. Kyung H, Kang N. Management of alveolar cleft. *Arch Craniofac Surg* 2015;16:49-52.
7. Cohen M, Polley JW, Figueroa AA. Secondary (intermediate) alveolar bone grafting. *Clin Plast Surg* 1993;20:691-705.
8. Choi HS, Choi HG, Kim SH, et al. Influence of the alveolar cleft type on preoperative estimation using 3D CT assessment for alveolar cleft. *Arch Plast Surg* 2012;39:477-82.
9. Amirlak B, Tang CJ, Becker D, et al. Volumetric analysis of simulated alveolar cleft defects and bone grafts using cone beam computed tomography. *Plast Reconstr Surg* 2013; 131:854-9.
10. Santiago PE, Schuster LA, Levy-Bercowski D. Management of the alveolar cleft. *Clin Plast Surg* 2014;41:219-32.
11. Daw JL Jr, Patel PK. Management of alveolar clefts. *Clin Plast Surg* 2004;31:303-13.
12. Abyholm FE, Bergland O, Semb G. Secondary bone grafting of alveolar clefts. A surgical/orthodontic treatment enabling a non-prosthetic rehabilitation in cleft lip and palate patients. *Scand J Plast Reconstr Surg* 1981;15:127-40.
13. Semb G. Effect of alveolar bone grafting on maxillary growth in unilateral cleft lip and palate patients. *Cleft Palate J* 1988;25:288-95.
14. Chang HP, Chuang MC, Yang YH, et al. Maxillofacial growth in children with unilateral cleft lip and palate following secondary alveolar bone grafting: an interim evaluation. *Plast Reconstr Surg* 2005;115:687-95.
15. Troxell JB, Fonseca RJ, Osborn DB. A retrospective study of

- alveolar cleft grafting. *J Oral Maxillofac Surg* 1982;40:721-5.
16. El Deeb M, Messer LB, Lehnert MW, et al. Canine eruption into grafted bone in maxillary alveolar cleft defects. *Cleft Palate J* 1982;19:9-16.
 17. Rawashdeh MA, Telfah H. Secondary alveolar bone grafting: the dilemma of donor site selection and morbidity. *Br J Oral Maxillofac Surg* 2008;46:665-70.
 18. Ilankovan V, Stronczek M, Telfer M, et al. A prospective study of trephined bone grafts of the tibial shaft and iliac crest. *Br J Oral Maxillofac Surg* 1998;36:434-9.
 19. Sharma S, Schneider LF, Barr J, et al. Comparison of minimally invasive versus conventional open harvesting techniques for iliac bone graft in secondary alveolar cleft patients. *Plast Reconstr Surg* 2011;128:485-91.
 20. Hudak KA, Hettinger P, Denny AD. Cranial bone grafting for alveolar clefts: a 25-year review of outcomes. *Plast Reconstr Surg* 2014;133:662e-668e.
 21. Oberoi S, Chigurupati R, Gill P, et al. Volumetric assessment of secondary alveolar bone grafting using cone beam computed tomography. *Cleft Palate Craniofac J* 2009;46:503-11.
 22. Cohen M, Figueroa AA, Haviv Y, et al. Iliac versus cranial bone for secondary grafting of residual alveolar clefts. *Plast Reconstr Surg* 1991;87:423-7.
 23. Rahpeyma A, Khajehahmadi S. Chin bone graft for maxillary alveolar cleft: indications and limitations. *J Craniofac Surg* 2014;25:1650-2.
 24. Misch CE, Dietch FM. Keys to bone grafting and bone grafting materials. In: Misch CE, editor. *Contemporary implant dentistry*. St. Louis: Mosby Elsevier; 2008. p.839-68.
 25. Bajaj AK, Wongworawat AA, Punjabi A. Management of alveolar clefts. *J Craniofac Surg* 2003;14:840-6.
 26. Rodella LF, Favero G, Labanca M. Biomaterials in maxillofacial surgery: membranes and grafts. *Int J Biomed Sci* 2011;7:81-8.
 27. Steven MR, Emam HA. Dental implant prosthetic rehabilitation: allogeneic grafting/bone graft substitutes in implant dentistry. In: Bagheri SC, Bell RB, Khan HA, editors. *Current therapy in oral and maxillofacial surgery*. St. Louis, Mo: Elsevier Saunders; 2011. p.157-62.
 28. Kinsella CR Jr, Cray JJ, Durham EL, et al. Recombinant human bone morphogenetic protein-2-induced craniosynostosis and growth restriction in the immature skeleton. *Plast Reconstr Surg* 2011;127:1173-81.
 29. Francis CS, Mobin SS, Lypka MA, et al. rhBMP-2 with a demineralized bone matrix scaffold versus autologous iliac crest bone graft for alveolar cleft reconstruction. *Plast Reconstr Surg* 2013;131:1107-15.
 30. Sivak WN, Macisaac ZM, Rottgers SA, et al. Management of failed alveolar bone grafts: improved outcomes and decreased morbidity with allograft alone. *Plast Reconstr Surg* 2014;133:345-54.
 31. Bergland O, Semb G, Abyholm FE. Elimination of the residual alveolar cleft by secondary bone grafting and subsequent orthodontic treatment. *Cleft Palate J* 1986;23:175-205.
 32. Enemark H, Sindet-Pedersen S, Bundgaard M. Long-term results after secondary bone grafting of alveolar clefts. *J Oral Maxillofac Surg* 1987;45:913-9.
 33. Long RE Jr, Spangler BE, Yow M. Cleft width and secondary alveolar bone graft success. *Cleft Palate Craniofac J* 1995;32:420-7.
 34. Kindelan JD, Nashed RR, Bromige MR. Radiographic assessment of secondary autogenous alveolar bone grafting in cleft lip and palate patients. *Cleft Palate Craniofac J* 1997;34:195-8.
 35. Witherow H, Cox S, Jones E, et al. A new scale to assess radiographic success of secondary alveolar bone grafts. *Cleft Palate Craniofac J* 2002;39:255-60.
 36. Feichtinger M, Mossbock R, Karcher H. Assessment of bone resorption after secondary alveolar bone grafting using three-dimensional computed tomography: a three-year study. *Cleft Palate Craniofac J* 2007;44:142-8.
 37. Honma K, Kobayashi T, Nakajima T, et al. Computed tomographic evaluation of bone formation after secondary bone grafting of alveolar clefts. *J Oral Maxillofac Surg* 1999;57:1209-13.
 38. Trindade IK, Mazzottini R, Silva Filho OG, et al. Long-term radiographic assessment of secondary alveolar bone grafting outcomes in patients with alveolar clefts. *Oral Surg Oral Med Oral Pathol Oral Radiol Endod* 2005;100:271-7.
 39. Tan AE, Brogan WF, McComb HK, et al. Secondary alveolar bone grafting: five-year periodontal and radiographic evaluation in 100 consecutive cases. *Cleft Palate Craniofac J* 1996;33:513-8.