



OPEN ACCESS

Clinical effectiveness of electroacupuncture in meralgia paraesthetica: a case series

Rosemary E Alexander

Correspondence to

Dr Rosemary E Alexander,
Rheumatology Department,
Edgware Community Hospital,
Edgware Road, Edgware,
Middlesex, HA8 0AD, UK;
rosemary.alexander2@nhs.net

Received 2 June 2013

Revised 13 August 2013

Accepted 14 August 2013

Published Online First

23 October 2013

ABSTRACT

Background Meralgia paraesthetica is a fairly common condition resulting from entrapment of the lateral femoral cutaneous nerve. I have found that acupuncture produces a rapid improvement, sometimes effecting a cure, after only one or two treatments. I therefore invited referrals in order to collect a case series.

Methods A series of 10 patients, which included two who had refused surgery, but excluded those with significant lumbar spine problems, were treated. Visual Analogue Scale pain scores and analgesic intake were recorded weekly, starting before treatment. Four patients were receiving high doses of analgesics and the average period of symptoms was 3–4 years. Acupuncture points used were BL25, GB30, GB34, GB31, GB32, *Huatuojiaji* and *ah shi* points of the buttock and thigh, up to a depth of 7.5 cm. Electroacupuncture was normally given from the second treatment.

Results Without exception, patients were specifically tender over GB31 before they started treatment. Most were also tender over the upper lumbar spine. An average of four to five sessions of acupuncture was given. The pain scores for all 10 patients improved by at least 50%, including that of a patient with a 20-year history. At follow-up (varying from 3 to 36 months), improvement was nearly 100%. Most patients were able to stop their analgesics.

Conclusions Meralgia paraesthetica appears to respond rapidly to electroacupuncture. A significant trigger point at GB31 was universally present, which may aid diagnosis, although the reason for this is unclear. Further controlled studies are justified.

INTRODUCTION

Meralgia paraesthetica (MP) or Bernhardt–Roth syndrome is a fairly common condition resulting from entrapment of the lateral femoral cutaneous nerve (LFCN). Although not life

threatening, the symptoms can cause considerable problems for the patient.

This was recognised by Hager in 1885 who tried to treat it surgically, then described extensively in 1895 by Martin Bernhardt,¹ a German neuropathologist who had noticed evidence of severe neuritis at the ‘femoral ring’, where the LFCN emerged, in some patients with sensory symptoms of the thigh.

The condition was named shortly afterwards by Vladimir Roth, a Russian neurologist, as meralgia paraesthetica² (Greek: meros=thigh and algos=pain), after noticing it in cavalrymen, who wore their belts too tightly, compressing the emerging LFCN.

Bernhardt and Roth described a syndrome characterised by sensory symptoms of paraesthesiae and burning pain, affecting mainly the lateral or, less commonly, the anterior part of the thigh, with no motor signs. In the early 20th century it seemed to be a common diagnosis, prompting a flurry of papers to be written.

Familial occurrence had been described and in 1895 Sigmund Freud described it in himself and his son (!).³

The LFCN typically arises from L2–3 nerve roots, although occasionally L1 is involved. Cadaver dissections have shown that it may be derived from the femoral or genitofemoral nerves in up to 30% of patients,⁴ in which case the symptoms may be different.

The LFCN pierces the psoas muscle, travels laterally across the pelvis then passes under or through the inguinal ligament 1–6 cm medial to the anterior superior iliac spine. Bifurcation into anterior and posterior divisions occurs 5–12 cm below this, the anterior division becoming superficial and supplying the skin of the anterior and lateral parts of the thigh as far as the knee. The posterior division pierces the



To cite: Alexander RE.
Acupunct Med 2013;**31**:
435–439.

fascia lata, passing backwards to supply the skin from the greater trochanter to the middle of the thigh (figure 1).

The reported prevalence of MP has been described in a general practice database population in the Netherlands as 4.3 per 10 000.⁵ However, this condition may be much commoner, being underdiagnosed and confused with lumbar radiculopathy.

Patients are usually aged 30–65 years and the female:male ratio is 1:2; 10% of cases are bilateral.

MP may be idiopathic or has been associated with the following conditions:

- A. internal pressure in the pelvis: due to pregnancy, ascites, tumour or obesity;
- B. external pressure: due to tight jeans, rucksacks, tight corsets, wide belts or seat belt injury;
- C. neuropathy: diabetes;
- D. surgery: laparoscopic herniorrhaphy, anterior pelvic procedures, lumbar spine surgery (one series of 110 patients reported an incidence of 12%)⁶;
- E. pathology of the lumbar nerve root.⁷

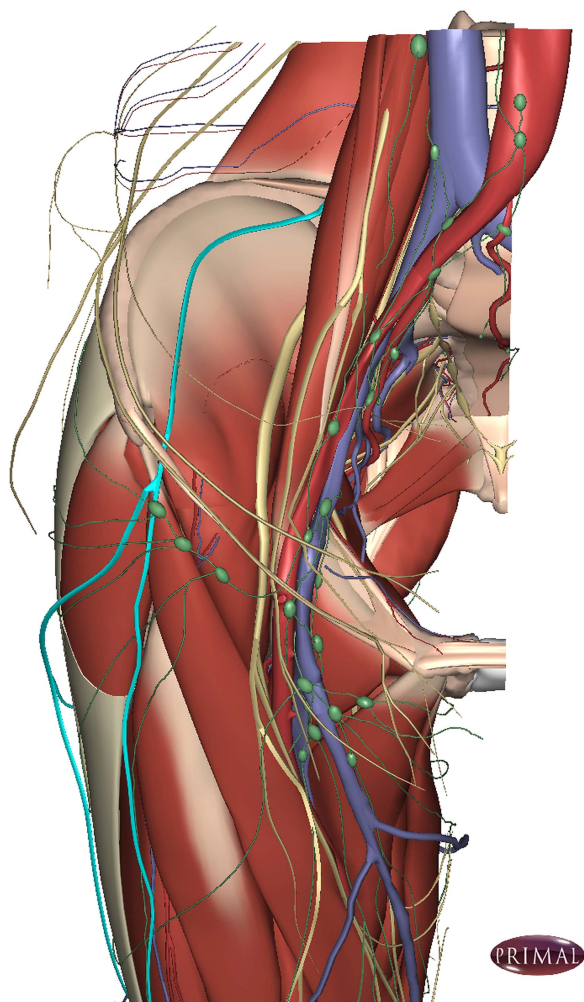


Figure 1 Path of the lateral cutaneous nerve. 3D anatomy image copyright Primal Pictures. From Primal Interactive Hip – 2013 Edition www.primalpictures.com

Symptoms are often characterised by tingling, burning, lightning pain, numbness or deep muscle aching, usually affecting a well demarcated area of the anterolateral thigh. Patients complain of being woken at night and needing strong analgesia. Local hair loss can occasionally occur as the LFCN also includes efferent sympathetic fibres.

A lieutenant in the Royal Army Medical Corps in 1916⁸ related that he had seen at least a dozen cases in 10 years, including those of five soldiers. He gives an excellent description of the condition, which included symptoms ‘like scalding water dripping down the leg’, loss of light touch sensation, mild and severe paroxysmic pain and how it can be relieved by flexing the hip and bending the knee for 2 min.

On examination, an area of numbness may be found on the thigh, but motor signs such as weakness of the quadriceps or iliopsoas muscles, or a diminished knee jerk denote another diagnosis, such as femoral neuropathy or radiculopathy of the lumbar spine.

Diagnosis is based on the presence of the typical signs and symptoms of MP, but sometimes by exclusion of other diagnoses by radiology or MRI scans of the lumbar spine.

Occasionally nerve conduction studies are used, which may show a reduction in sensory nerve action potentials of the LFCN. Two studies show differing efficacy in using sensory nerve conduction potentials and somatosensory evoked potentials (segmental and dermatomal),^{9 10} although the later study suggested combining both methods. Since the test results are unreliable, they were not used in my study.

Reported treatments vary from rest to transection or neurolysis of the LFCN. A Cochrane review¹¹ highlights the lack of randomised controlled trials and any objective evidence for choice of treatment in MP, but describes observational studies involving at least five patients. One study showed spontaneous improvement in 69% and four studies, using injections of steroid and local anaesthetic, showed an improvement or cure in 83% of 157 cases. Surgical treatments were found to be beneficial, success rates being 88% with decompression and 94% with neurectomy, although permanent numbness of the thigh often resulted.

METHODS

A case series of 10 patients with MP was started in 2008, after seeing a dramatic improvement in response to acupuncture in my own practice.

I included two patients from my own practice (where the condition is not uncommon), and asked consultant rheumatologists in my hospital trust to refer patients to me. All patients had had lumbar spine radiology and some MRI scans but patients who also had significant lumbar spine pathology or sciatica were excluded. All patient procedures were part of normal care so ethics approval was not needed for this study.

Table 1 Acupuncture for meralgia paraesthetica: individual patient results

Meralgia paraesthetica results												
Patients	VAS pain scores, scale 0–10				Time interval for follow-up Months	Score Follow-up Day	Score Follow-up Night	No. of treatments	Average analgesics per week Before	Average analgesics per week After	Duration of symptoms before treatment	
	Score	Score	Score	Score								
	Initial	Initial	Final	Final								
	Day	Night	Day	Night								
1 (M)	8	0	3	0	3	0–1	0	6	0	0	20 Years	
2 (M)	8	8	2	0	12	0	0	7	14 (A)	0	18 Months	
3 (F)	9	5	2	0	24	2 (occasions)	0	5	21 (B) and 17 (A)	0	4–5 Years	
4 (F)	4–5	0	2–3	0	3	0	0	3	2 (C)	0	3 Weeks	
5 (F)	8–9	8–9	4–5	4–5	9	0	0	2	56 (D)	0	3 Years	
6 (M)	5–6	5–6	1	1	3	0	0	2	0	0	18 Months	
7 (F)	7–8	2–3	1	0	2 and 36	0	0	4	0	0	3 Months	
8 (F)	5	0	1	0	3 and 6	0	0	5	28 (E)	7 (for arthritis)	6 Months	
9 (M)	5	0	1	0	3 and 6	1	0	8	0	0	5 Years	
10 (M)	10	6	2	2	Moved house	2	2	3	0	0	5 Years	

(A), co-proxamol; (B), diclofenac; (C), ibuprofen; (D), co-codamol; (E), paracetamol. VAS, Visual Analogue Scale.

At the beginning of each treatment session, patients filled in an average weekly Visual Analogue Scale score for pain, both night and morning. Day and night scores before and after treatment were analysed as was the 3-month follow-up. Patients were invited to attend the clinic or contacted by telephone. The average number of analgesics was recorded each week and these were found to have been taken regularly by four patients.

Traditional Chinese acupuncture points were used following the Gall Bladder meridian—for example, GB30, GB31, GB32, GB34+BL25 as well as (*Huatuojiaji*) points, 0.5 cun lateral to the lower ends of the lumbar dorsal spines (often spinal segments L1–3 on the opposite side). Other relevant deep gluteal and thigh trigger points were used, especially if also classic points. Japanese needles from Acumedic were used, the insertion depth varying from 25 to 75 mm. Needles were left in for about 20–25 min with an infrared lamp heating the local area.

Electroacupuncture was used after the first treatment if significant benefit was not obtained. A pulsed current with a biphasic spike waveform and a dense-disperse programme of 20/100 Hz¹² was used to the limit of the patient's tolerance, as patients seem to show the least amount of sensory adaptation with this type of stimulation.

The number of treatments varied between two and eight.

RESULTS

Patients were aged between 30 and 70 years and 50% were male.

One patient (no 10 in table 1) only had three sessions of acupuncture because he moved out of the area. (He has since been contacted to obtain follow-up data.)

The cause of MP was often uncertain but one patient had diabetes and several were obese. Three patients also had inflammatory joint disease. One woman wore tight corsets and two men wore tight belts or jeans. One male hairdresser had had to stop work before the acupuncture treatment as he was unable to stand without pain.

The average duration of symptoms was 3–4 years. All had tried conservative treatment, physiotherapy or injections and two patients had refused surgery.

Without exception all patients were tender, specifically over GB31, and were less tender after treatment. The majority of patients were also tender over an upper lumbar facet joint on the opposite side, approximating to L2–3.

Day and night scores before and after treatment and at the 3-month follow-up were analysed.

The pain scores presented in table 1 and figures (2A and B) improved by at least 50%, including those of a patient with a 20-year history of pain. At follow-up (varying from 3 to 36 months), the improvement in the Visual Analogue Scale day pain

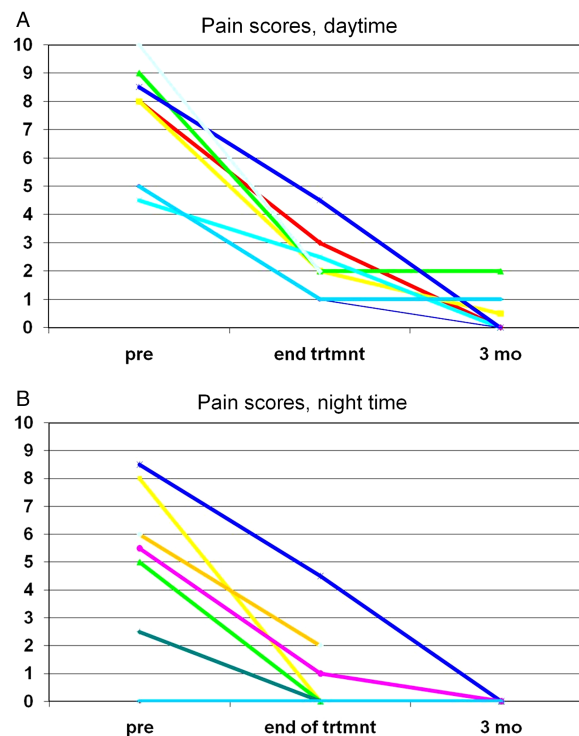


Figure 2 (A) Pain scores daytime. (B) Pain scores night time.

score was 92% and night pain score was 94%. This result included the patient unable to complete his course of treatment and as a consequence was the only patient to have any residual night pain.

Patients were able to stop all their analgesics. The response was often very quick, especially after the first two treatments.

There were no reported significant side effects.

DISCUSSION

Acupuncture produced a dramatic improvement in the symptoms of MP, both during treatment and long term even in patients who had had symptoms for many years.

There are few previous reports of acupuncture used for this condition. One earlier paper¹³ discussed two case reports of the treatment of MP with acupuncture, where the patients had chronic pain and paraesthesiae of the lateral thigh, resistant to treatment. They quickly became free of symptoms.

All patients had extreme tenderness over GB31, which can be located at the tip of the middle finger when the patient stands with their arm resting on the lateral thigh. The majority also had tenderness over a facet joint on the opposite side of the upper lumbar spine, suggesting lumbar spine pathology. The significance of these findings is unclear.

This was only a small group of patients, with no control group, but all had tried other treatments. Most patients had had their symptoms for several years, making spontaneous improvement unlikely.

Although many patients with MP respond to steroid injections, these may need to be repeated. Surgery is not always successful and its use is limited by side effects.

Electroacupuncture appears to be a safe effective treatment for this disabling condition, although the mechanism of the effect of the needles is unclear.

Controlled trials are warranted.

Competing interests None.

Provenance and peer review Not commissioned; externally peer reviewed.

Open Access This is an Open Access article distributed in accordance with the Creative Commons Attribution Non Commercial (CC BY-NC 3.0) license, which permits others to distribute, remix, adapt, build upon this work non-commercially, and license their derivative works on different terms, provided the original work is properly cited and the use is non-commercial. See: <http://creativecommons.org/licenses/by-nc/3.0/>

REFERENCES

- Bernhardt M. Ueber isoliert im Gebiete des N. cutaneus femoris externus vorkommende paraesthesien. *Neurol Centralbl* 1895;14:242–4.
- Roth VK. *Meralgia paraesthetica*. Berlin: Karger, 1895.
- Freud S. Ueber die Bernhardt'sche Sensibilitaetsstoeung. *Neurol Centralbl* 1895;14:491–2.
- Keegan JJ, Holyoke EA. Meralgia paraesthetica—an anatomical and surgical study. *J Neurosurg* 1962;13:341.
- Van Slobbe AM, Bohnen AM, Bernsen RM, *et al*. Incidence rates and determinants in meralgia paraesthetica in general practice. *J Neurol* 2004;251:294–7.
- Gupta A, Muzumda D, Ramani P. *Neurol India* 2004;52:64–6.
- Rinkel GJ, Wokke JH. *Clin Neurol Neurosurg* 1990;92/4:365–67.
- Rutherford WJ. Meralgia paraesthetica. *BMJ* 1916:583–4.
- Seror P. LFCN conduction v somatosensory evoked potentials for electro-diagnosis of meralgia paraesthetica. *Am J Phys Med Rehabil* 1999;78:313–16.
- El-Tantawi GA. Reliability of sensory nerve conduction and somatosensory evoked potentials for diagnosis of meralgia paraesthetica. *Clin Neurophys* 2009;120/7:1346–51.
- Khalil N, Nicotra A, Rakowicz W. Treatment for meralgia paraesthetica. *Cochrane database of Systematic Reviews* 2008 (updated 2012) Issue 3. Art.No:CD004159
- Han JS, Sun SL. Differential release of enkephalin and dynorphin by low and high frequency electroacupuncture in the central nervous system. *Acupunct Sci Int J* 1990;1:19–27.
- Aigner N, Aigner G, Fialka C, *et al*. Therapy of meralgia paraesthetica with acupuncture (two case reports). *Der Schmerz* 1997;11:113–15.