

Incidental detection of pancreatic hemangioma mimicking a metastatic tumor of renal cell carcinoma

Sung Hyun Kim¹, Ji-Ye Kim², Jin Young Choi³, Young Deuk Choi⁴, and Kyung Sik Kim¹

Departments of ¹Hepatobiliary and Pancreatic Surgery, ²Pathology, ³Radiology, and ⁴Urology, Severance Hospital, Yonsei University College of Medicine, Seoul, Korea

Adult pancreatic hemangioma is a rare disease. We presented a case of a woman with pancreatic tail mass mimicking a distant metastasis from the kidney. A 68-year-old woman was found with a left kidney mass on medical checkup. Computed tomography scan showed a 4.3 cm-sized mass in the left kidney, suggesting renal cell carcinoma (RCC), and a strongly enhancing tiny nodule in the pancreatic tail. We could not rule the possibility of RCC metastasis, hence, surgical resection of the pancreatic mass simultaneously with radical nephrectomy for RCC was conducted. Gross pathologic examination revealed hemangioma. Immunohistochemistry revealed that the tumor was positive for CD34, CD31 and factor VIII-related antigen. There were no significant postoperative events, and the patient was discharged on postoperative day 7 without any complications. Treatment strategies for pancreatic hemangioma have not been established. To our knowledge, this was the first case report of asymptomatic pancreatic hemangioma. In previous literature, treatment differed on a case-by-case basis, ranging from observation to surgical resection. The most important factor in deciding whether to perform surgery is possibly risk-benefit effectiveness; however, tumor location, patient symptoms, and other factors are also important. ([Korean J Hepatobiliary Pancreat Surg 2016;20:93-96](#))

Key Words: Pancreas; Hemangioma; Adult hemangioma; Incidental discovery; CD34

INTRODUCTION

Hemangiomas are tumors characterized by increased numbers of normal or abnormal vessels filled with blood. Occasionally, hemangiomas can occur internally, and nearly one-third of these internal lesions are found in the liver. Pancreatic hemangiomas are especially rare; pancreatic vascular neoplasms collectively account for only 0.1% of all pancreatic tumors.¹ These tumors are usually diagnosed fortuitously by laparotomies performed to diagnose a large, palpable abdominal mass.²⁻⁵ We presented a very rare case in which a woman without specific symptoms was found with a cavernous hemangioma in the pancreas tail that mimicked metastatic tumor.

CASE

A 68-year-old woman was found with a mass in her left kidney on medical checkup. She had no significant past medical history except hypertension and no symptoms (e.g., hematuria, abdominal pain, or abdominal discomfort). An axial contrast-enhanced computed tomography (CT) scan showed a heterogeneous solid mass in the left kidney, suggesting the presence of renal cell carcinoma (RCC). There was a strongly enhancing tiny nodule in the tail of the pancreas that was most likely either a neuroendocrine tumor or a RCC metastasis (Fig. 1A). Because she had no specific symptoms or abnormal laboratory findings, the possibility of RCC metastasizing into the pancreas could not be ruled out. Therefore, surgical resection, including left radical nephrectomy and distal pancreatectomy was conducted. There were no significant postoperative events,

Received: August 31, 2015; **Revised:** September 16, 2015; **Accepted:** September 21, 2015

Corresponding author: Kyung Sik Kim

Department of Hepatobiliary and Pancreatic Surgery, Severance Hospital, Yonsei University College of Medicine, 50-1 Yonsei-ro, Seodaemun-gu, Seoul 03722, Korea

Tel: +82-2-2228-2100, Fax: +82-2-313-8289, E-mail: KSKIM88@yuhs.ac

Copyright © 2016 by The Korean Association of Hepato-Biliary-Pancreatic Surgery

This is an Open Access article distributed under the terms of the Creative Commons Attribution Non-Commercial License (<http://creativecommons.org/licenses/by-nc/4.0>) which permits unrestricted non-commercial use, distribution, and reproduction in any medium, provided the original work is properly cited.

Korean Journal of Hepato-Biliary-Pancreatic Surgery • pISSN: 1738-6349 • eISSN: 2288-9213

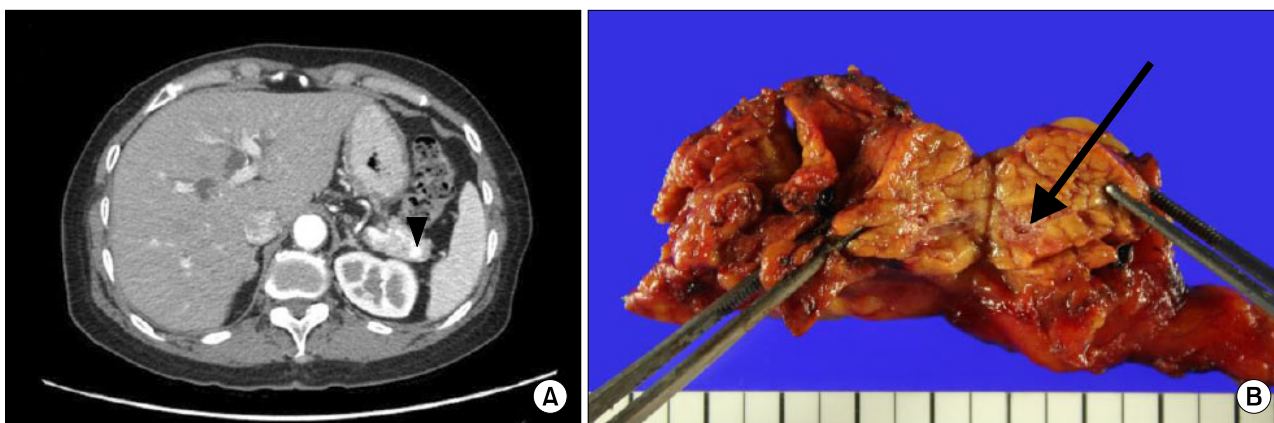


Fig. 1. Imaging study and gross morphology. (A) Axial contrast-enhanced CT scan during the arterial phase shows a strongly enhancing tiny nodule in the pancreatic tail (arrowhead); (B) Gross specimen; pancreatic hemangioma confined to the pancreas (arrow).

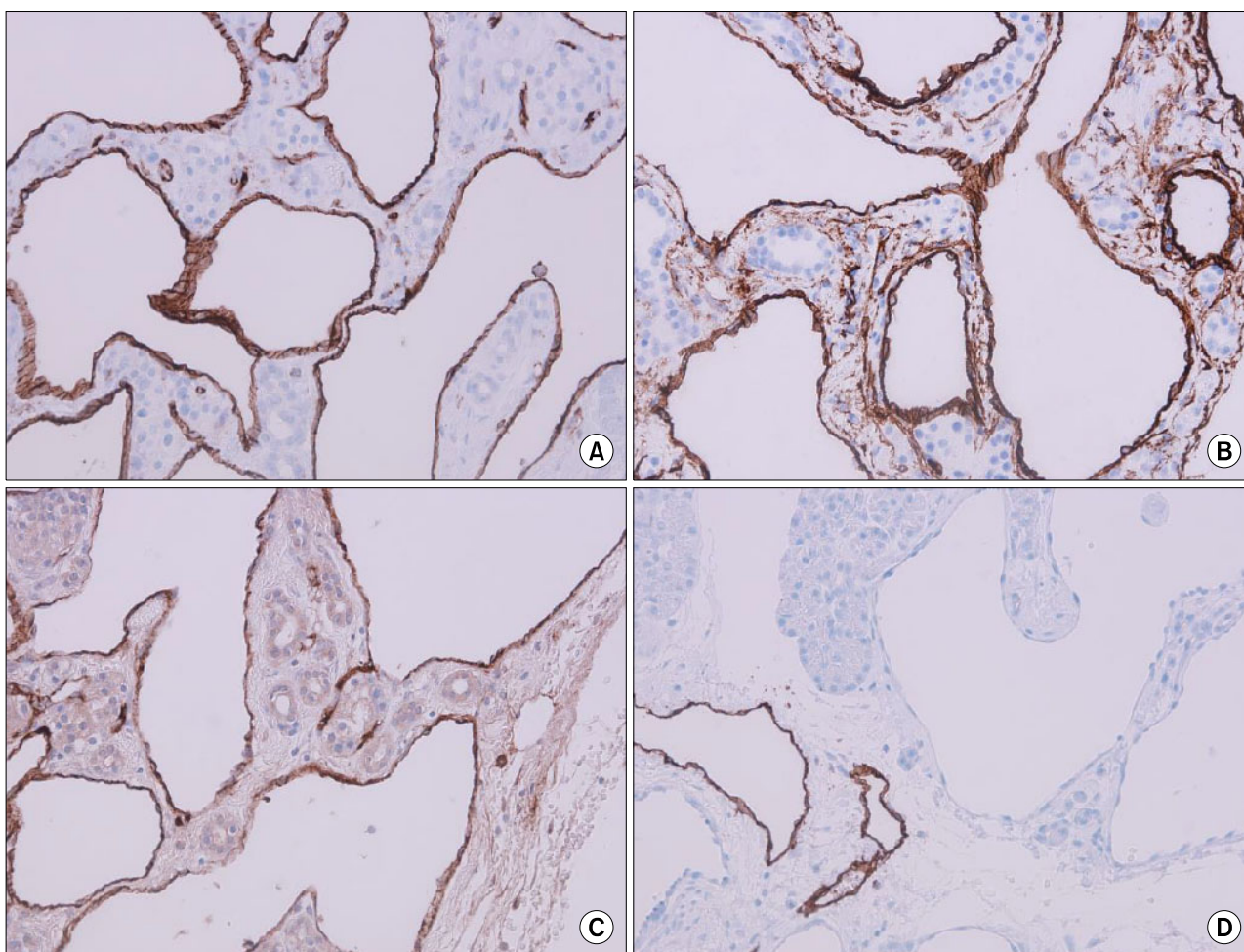


Fig. 2. Immunohistochemical stain shows a cavernous, ectatic endothelial neoplasm arising amid pancreatic parenchymal tissue. (A) CD31 (100×); (B) CD34 (100×); (C) factor VIII-related antigen (100×); and (D) D2-40 (100×).

and the patient was discharged home on postoperative day 7 without any morbidity or complications.

Gross pathologic examination revealed a 0.6×0.5 cm-sized

hemangioma confined to the pancreas, and the tissue had a tumor-free margin (Fig. 1B). Immunohistochemical analysis showed that the tumor was positive for CD31, CD34,

and factor VIII-related antigen, and negative for D2-40, RCC, and CD56 (SCLC), supporting the diagnosis of hemangioma (Fig. 2). The left kidney mass was confirmed as RCC with no evidence of metastasis.

DISCUSSION

Hemangiomas rarely occur in the pancreas and often are not suspected clinically; only 14 patients are reported in the literature since 1939. Review of the previous literature reports on pancreatic hemangioma indicated that most hemangiomas occur in females (12/15 patients, including our patient) and are symptomatic (9/15 patients had abdominal pain, and one patient each had melena, thrombocytopenia, abdominal distension, and palpitation, suggesting bleeding). Only 1 tumor was found incidentally, in 1939 upon autopsy.²⁻⁷

The hemangioma was found incidentally at a pre-operative evaluation for RCC. Unlike previous studies, we found no symptoms suggesting pancreatic hemangioma, likely because it was a tiny pancreatic tail mass. Typically, hemangiomas are strongly contrast enhancing in the arterial phase of conventional contrast-enhanced CT imaging,⁸ however, our case did not present these findings, likely because of the small lesion size. The pancreatic hemangioma thus mimicked metastatic cancer originating from the RCC. To our knowledge, this case was the first report of pancreatic hemangioma without a symptomatic event, and the tumor is the smallest of the reported cases. After surgery, the pancreatic tail tumor was pathologically confirmed as a hemangioma.

Microscopic findings revealed a typical feature of hemangioma i.e., blood-filled spaces separated by fibrous connective tissue. For a definite diagnosis, immunohistochemistry is required to assess the presence of the factor VIII-related antigen, a marker for vascular endothelium that was reported by Chang and colleagues.⁹ Subsequently, Munding and colleagues reported that neoplastic cells in hemangioma also express the endothelial markers CD31 and CD34.⁵ In our patient, immunohistochemical findings were positive for all 3 markers; whereas, D2-40, a marker for lymphatic endothelium, and CD56, a marker for neural cell, were both negative, further indicating that the tumor mass was a hemangioma.

Because of its rarity, there is no standard treatment for

pancreatic hemangioma. Reviewing the previous literature on pancreatic hemangioma, we found that multiple different treatments were administered, from observation to surgical resection.²⁻⁷ Furthermore, the possibility of abdominal pain or hemorrhagic events is typically increased in patients with larger hemangioma masses. Therefore, some clinicians suggested that surgery is the best treatment option. However, other clinicians suggested that if the patient's symptoms are minimal, observation is a possible treatment option, because pancreatic hemangiomas are benign.

The location of the pancreatic hemangioma is variable, and may be important for determining the best treatment option. Upon reviewing previous literature, we found that pancreatic hemangiomas were located at the head (8/15 patients), neck (1/15 patients), or body/tail (6/15 patients).²⁻⁷ When the tumor is located at the body/tail, distal pancreatectomy is an option. However, if the tumor is located at the proximal site of the pancreas, pylorus-preserving pancreaticoduodenectomy is indicated. Patients who underwent pylorus-preserving pancreaticoduodenectomy had a higher rate of morbidity than patients who underwent distal pancreatectomy (34.7% vs. 27.8%, $p < 0.05$).¹⁰ Therefore, if a patient has a pancreas head hemangioma with minimal symptoms that can be controlled, close observation and regular follow-up can be one of the treatment options according to risk-benefit analysis. Because our case was confined to a tiny mass at the distal pancreas, and we could not rule out distant metastasis from the RCC tumor, we decided to perform a distal pancreatectomy.

The literature review indicated that treatment decisions require assessment of the severity of symptoms and location of the tumor. When all the cases were collectively considered, determining the timing of surgery based on comparison of surgical risk-benefit analysis emerged as an important factor. Future reports will provide more data on the optimal treatment strategies for pancreatic hemangioma.

REFERENCES

1. Robbins SL, Kumar V. Robbins and Cotran pathologic basis of disease. 8th ed. Philadelphia, PA: Saunders/Elsevier, 2010.
2. Weidenfeld J, Zakai BB, Faermann R, Barshack I, Aviel-Ronen S. Hemangioma of pancreas: a rare tumor of adulthood. *Isr Med Assoc J* 2011;13:512-514.
3. Lee J, Raman K, Sachithanandan S. Pancreatic hemangioma

- mimicking a malignant pancreatic cyst. *Gastrointest Endosc* 2011;73:174-176.
- Jarboui S, Salem A, Gherib BS, Ben Moussa M, Rajhi H, Mnif N, et al. Hemangioma of the pancreas in a 60-year-old woman: a report of a new case. *Gastroenterol Clin Biol* 2010;34:569-571.
 - Mundinger GS, Gust S, Micchelli ST, Fishman EK, Hruban RH, Wolfgang CL. Adult pancreatic hemangioma: case report and literature review. *Gastroenterol Res Pract* 2009;2009:839730.
 - Williamson JM, Finch-Jones M, Pope I. Endoscopic ultrasonography allowing expectant management of pancreatic haemangioma. *Ann R Coll Surg Engl* 2014;96:e1-e2.
 - Naito Y, Nishida N, Nakamura Y, Torii Y, Yoshikai H, Kawano H, et al. Adult pancreatic hemangioma: a case report. *Oncol Lett* 2014;8:642-644.
 - Kobayashi H, Itoh T, Murata R, Tanabe M. Pancreatic cavernous hemangioma: CT, MRI, US, and angiography characteristics. *Gastrointest Radiol* 1991;16:307-310.
 - Chang WT, Lee KT, Yang SF. Cavernous hemangioma of the pancreas: report of a case. *Pancreas* 2003;26:310-312.
 - Kneuert PJ, Pitt HA, Bilimoria KY, Smiley JP, Cohen ME, Ko CY, et al. Risk of morbidity and mortality following hepato-pancreato-biliary surgery. *J Gastrointest Surg* 2012;16:1727-1735.