

Recent advances in intestinal imaging

Rakesh Sinha

Department of Clinical Radiology, South Warwickshire NHS Foundation Trust, Warwick, England

Correspondence: Dr. Rakesh Sinha, Department of Clinical Radiology, South Warwickshire NHS Foundation Trust and Warwick Medical School, Lakin Road, Warwick CV345BW, UK. E-mail: rakeshsinha@btinternet.com

Abstract

In recent years, advances in scanner technology and competition from other specialties have produced rapid changes in the way the intestines are imaged. MRI and CT scan along with the traditional enteroclysis examination have emerged at the forefront of intestinal imaging. Functional modalities such as diffusion and perfusion imaging are also changing the way tumors and inflammatory bowel diseases are evaluated. CT colonography is now a valid alternative to optical colonoscopy. Contrast-enhanced USG is being used for the assessment of inflammation and post-treatment changes. In this review, recent advances in intestinal imaging are described.

Key words: Computed tomography; intestines; magnetic resonance imaging

Introduction

Traditionally, barium examinations have been the mainstay of radiological investigations of the small and large intestines. However, the standard barium follow-through (SBFT) examination has high false-negative and false-positive rates for the detection of abnormalities.^[1] This is because only 25–35% of the bowel length can be adequately assessed on a standard examination due to overlapping loops, poor coating, and other factors.^[1] Several new techniques have therefore evolved that provide better diagnostic capabilities and higher accuracy rates.^[2–4] In this article, the newer techniques and modalities being employed for imaging of the bowel are detailed, with an overview of their strengths and weaknesses.

Current Role of Barium Examinations

Innovations in intestinal imaging have been driven by the demand for detailed clinical information and the limitations of standard methods of small-bowel examination. Alternative techniques such as the pill camera that allow

high-definition color views of the bowel have appeared. At an average frequency of two frames per second, a total of >50,000 frames are collected in 7–8 h as the pill camera travels through the bowel. Despite the high-resolution images provided by this technique, it has become increasingly apparent that not all mucosal abnormalities seen on wireless capsule endoscopy are clinically relevant. Mucosal erosions may be seen in as many as 14% of asymptomatic healthy subjects, with the rate of such abnormalities being more than double this in users of nonsteroidal anti-inflammatory drug (NSAID) agents.^[5] Furthermore, the pill camera does not provide any information about mural and extramural abnormalities. Therefore, the need for a complementary radiologic examination is apparent. Contraindications to the pill camera include bowel obstruction, history of bowel strictures or fistulae.

The most accurate conventional radiologic method in the diagnosis of small-bowel obstruction, inflammatory bowel disease (IBD), gastrointestinal bleeding, and neoplasms is double-contrast enteroclysis.^[2] However, SBFT has remained the most commonly performed method for the investigation of small-bowel diseases because of its ease of performance and the relative technical complexity of enteroclysis as well as the discomfort to patients during intubation. The SBFT has a low diagnostic yield and low negative predictive value. In a recent study, 8% of patients with known Crohn disease encountered capsule retention despite a previous normal SBFT. Non-intubation examinations do not fully distend the bowel, and therefore partial strictures, obstructions, and small polyps or masses can be easily missed. The advantage of enteroclysis examinations is that

Access this article online

Quick Response Code:



Website:
www.ijri.org

DOI:
10.4103/0971-3026.85363

there is optimal bowel distension, which allows detailed evaluation of all segments^[6] [Figure 1].

Enteroclysis examination with barium–methylcellulose is the most commonly performed enteroclysis method in many countries. However, the disadvantage with this technique is that methylcellulose has a washout effect on superficial mucosal features. Subtle surface abnormalities get effaced as more methylcellulose is infused to achieve a good double-contrast effect and bowel distension. Therefore, this method should be reserved for detection of obstruction or mass lesions or it should be used in combination with CT scan or MRI exams.^[2-4,7] Fluoroscopic evaluation with positive enteral contrast can help distinguish fixed (stenotic) segments of small-bowel narrowing from spasm caused by active inflammation in patients who have Crohn disease and can also differentiate mild stenosis from normal peristaltic contractions.

On the other hand, double-contrast enteroclysis with air/CO₂ and barium is by far the best method for showing mucosal details of the small bowel.^[5,7-8] A scientific study comparing double-contrast air enteroclysis with histopathology showed good correlation between the two for the visualization of aphthae and small ulcers [Figure 2].

Therefore, if capsule endoscopy is unavailable or contraindicated, double-contrast air enteroclysis should be the preferred modality for the detection of early ulcerations, irregularities, and erosions of the small bowel. This technique should also be employed if other imaging tests have been negative and a suspicion of small-bowel pathology still persists. Double-contrast methylcellulose–barium enteroclysis is the best method for the detection of strictures and partial stenoses.^[1,5] This technique can be performed on its own or it can be combined with CT scan or MRI. The pill camera remains the most sensitive method for the evaluation of gastrointestinal tract bleeding.^[8-9]

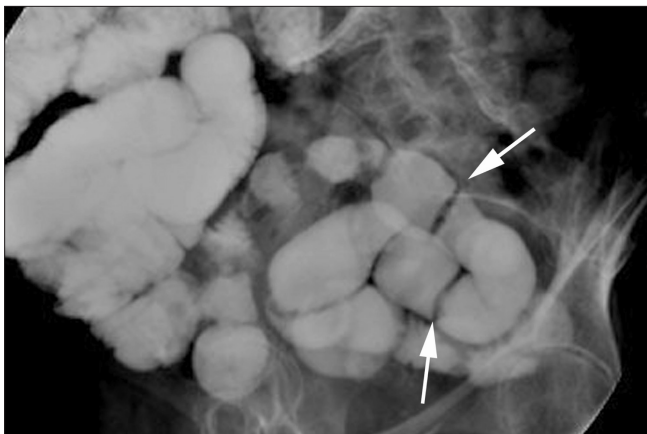


Figure 1: Barium–methylcellulose bowel examination shows linear filling defects (webs) (arrows) in the distal ileum secondary to the use of nonsteroidal anti-inflammatory drugs (NSAIDs)

CT Scan and MRI

Bowel opacification

The most important factor for obtaining good intestinal imaging is optimal distension of the bowel with enteral contrast. Enteral contrast can be positive, neutral, or negative, depending on its density (HU). Positive enteral contrast agents range from a 4–15% contrast solution to a dilute 0.3–6% barium solution. The author prefers an 8–10% iodine concentration of water-soluble contrast because this density allows diagnostic fluoroscopic observations as well as diagnostic radiographs. Neutral contrast agents can be methylcellulose, mannitol, polyethyl glycol, or other bulk fibers and have a density similar to water (0 HU). Negative contrast is mainly used in the imaging of the colon [CT colonography (CTC)], where CO₂ or air is insufflated per rectum.

Enteral contrast can be administered via the intubation method (CT enteroclysis/MRI enteroclysis) or the enterographic method [Figure 3].^[6] For enterographic examination, the patient ingests a large volume of contrast over a set period of time prior to imaging. The author prefers to use 1300 ml of contrast ingested over 50 min. The 1300 ml is divided into two aliquots: the first lot is ingested with a prokinetic agent (metoclopramide) over 25 min and the second lot is consumed over the next 25 min. Just prior to the scan, 200 ml of contrast is administered to outline the stomach and duodenum. The main advantage of the enterographic examination is that it is more acceptable to patients than enteroclysis as intubation may be an unpleasant experience for patients.^[10] The disadvantage of enterographic examination is that it may not provide uniform or adequate bowel distension as compared to enteroclysis.

Water is also routinely used as a neutral enteral contrast agent at many centers; however, its use in dedicated small-bowel studies should be discontinued. Water has been found

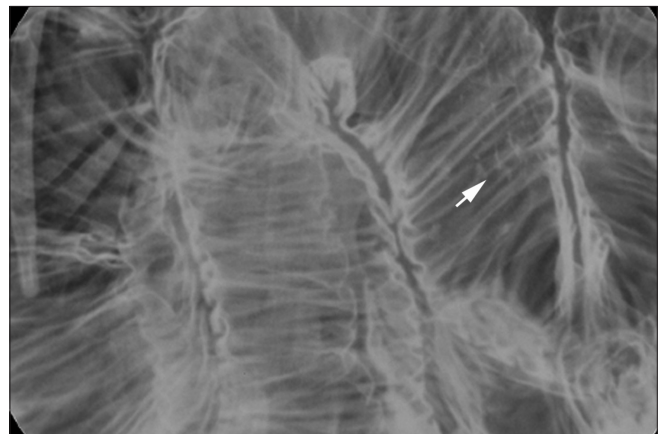


Figure 2: Magnified view from an air–barium double contrast enteroclysis examination shows early linear mucosal breaks and ulcers (arrow) in a patient with proven Crohn disease

to provide inadequate distension (at various volumes and ingestion times) of the small bowel in many studies.^[10-11] This is because water undergoes rapid reabsorption in the bowel and fails to adequately distend the distal small-bowel segments. Therefore, additives (such as contrast, mannitol or other agents) need to be mixed with water to provide an iso-osmolar solution that does not get reabsorbed and remains in the lumen to provide distension. The use of water as a contrast agent may lead to false-negative examinations. Furthermore, collapsed loops are known to demonstrate hyperenhancement on post-contrast studies and this may lead to false-positive diagnoses. Therefore, the author strongly discourages the use of water as an enteral agent in dedicated studies of the small bowel. The only instance where water may be used as an enteral agent is in

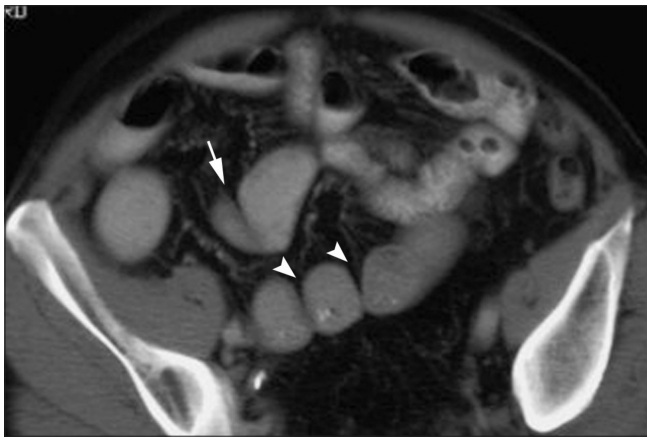

Figure 3: Axial CT enteroclysis examination demonstrates a segment of kinked bowel (arrowhead) and several adhesive bands across other segments (arrows). This patient had undergone several negative CT examinations previously

the enteroclysis technique where the operator exclusively controls distension of the bowel and rate of infusion.

CT scan

The advantage of current-generation multidetector CT (MDCT) scanners is increased anatomical coverage with thinner sections, which provide high-quality multiplanar (MPR) images and fewer motion artifacts.^[12-13] Positive-contrast CT enteroclysis (CTE) or enterography (CTEG) may be used mainly for the diagnostic workup of small-bowel obstruction or in suspected cases of small intestinal tumors or metastases. One of the drawbacks of positive contrast is the production of streak artifacts on MPR reconstruction, particularly on older CT scanners that cannot produce isotropic voxels (slice thickness >2 mm).

Further refinements to these techniques include the use of neutral contrast. The advantages of neutral contrast are that it does not obscure the mucosal lining and does not produce streak artifacts. (It must be remembered that fluoroscopy is not possible with neutral contrast). Neutral contrast allows better visualization of mucosal enhancement, ulcers, and bleeds. Therefore, neutral-contrast CTE or CTEG is indicated for the workup of patients with inflammatory bowel bleed, gastrointestinal bleeding, and suspected bowel pathologies.^[6]

CTC is a technique where the colon is imaged noninvasively. Several studies have shown that CTC has high sensitivity and specificity (>95%) for the detection of polyps and cancers^[14] [Figure 4A]. The colon is distended by insufflating air/CO₂ per rectum.^[15] Datasets of the distended colon are obtained, which can then be manipulated by software to provide virtual colonoscopy images. Recent advances include automated polyp detection software and virtual

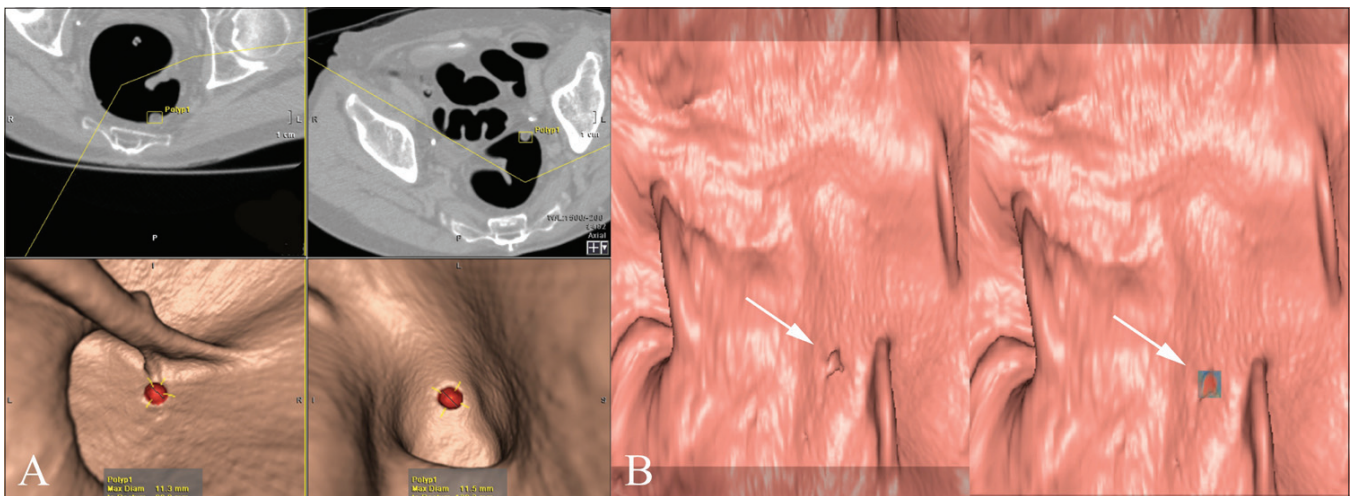


Figure 4 (A,B): Screenshot (A) from a CT colonographic examination shows a polyp in the colon. Top two axial images show the location of the polyp within a marker box, whereas the bottom two are virtual 3D images in the supine and prone positions which detail polyp size and distance from the rectum. Mucosal views (B) show a virtual dissection view of the colon with a small polyp (arrow) in the left image. On the right, translucency rendering shows this lesion to be homogeneously dense (red), implying this is retained fecal matter

dissection views of the colon. Translucency rendering software allows differentiation between fecal matter and polyps [Figure 4B].

MRI

MRI is an emerging technique for comprehensive and functional bowel imaging.^[16] The absence of ionizing radiation and high-contrast resolution are the major advantages of MRI over CT scan. The nonionizing aspect of MRI makes it particularly suited for use in patients with IBD who may need repeated imaging. The inherent high-contrast resolution can provide high diagnostic confidence and also facilitate the detection of discriminating features of intestinal diseases.^[17]

T_1W and T_2W imaging sequences for the imaging of the bowel have been reported in earlier studies.^[10,17-18] However, in recent years, advances with ultra-fast sequences based on steady-state precession have revolutionized bowel imaging. These sequences can be performed within a single breath-hold, and when combined with bowel paralysis (using antiperistaltic agents, e.g., buscopan), the technique allows rapid imaging of the small bowel. These sequences are called true fast imaging with steady-state precession (true-FISP), balanced fast field-echo (FFE), or fast imaging employing steady-state acquisition (FIESTA).^[14] These sequences are relatively insensitive to motion artifacts and provide high contrast between the bowel wall, lumen, and the mesentery. The problem with these sequences is the presence of a “black boundary” artifact along the bowel wall, which may mask small lesions or abnormalities. The addition of fat suppression may help in reducing the effects of the black boundary artifact [Figure 5]. Fast sequences also obviate the need for long breath-holds, and thus reduce motion or respiratory artifacts.

T_2W fast sequences based on rapid acquisition and relaxation, such as half-Fourier single-shot turbo spin-echo (HASTE) or single-shot fast spin-echo (SSFSE) sequences, are also used and can provide high contrast between the lumen and the bowel wall, producing images akin to a conventional barium study. These sequences are susceptible to motion artifacts produced by flow voids and peristalsis. T_1W sequences in two or three dimensions are used for post-contrast imaging. Fat saturation can be used to increase contrast resolution and also for better assessment of bowel enhancement.

Parallel imaging techniques can help in improving spatial and temporal resolution on MRI. It is possible that with this technique, high-resolution three-dimensional datasets comprising isotropic voxels of the entire abdomen could be produced within a single breath-hold. Three-dimensional datasets allow high-quality MPR reconstructions, which can increase diagnostic confidence.

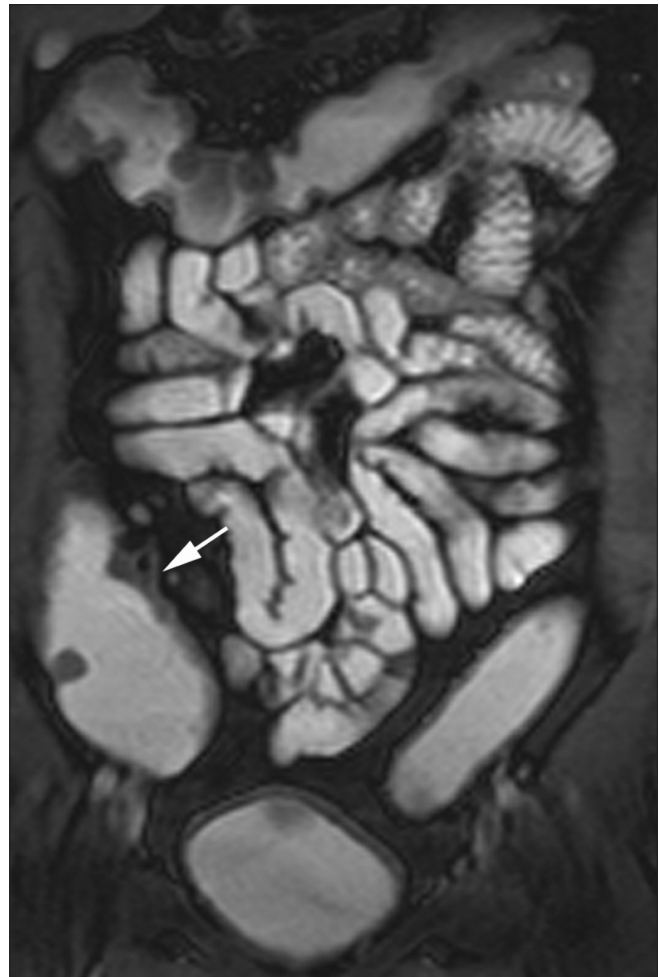


Figure 5: A patient with Crohn disease. MRI enterography examination shows good opacification of the small and large bowel with thickening of the inflamed cecal wall (arrow)

USG

The main advantages of USG are its nonionizing character and general availability. The dynamic, real-time qualities of USG provide high temporal resolution.^[19] USG also allows observation of normal or abnormal bowel peristalsis, fixity, and compressibility. Some studies have employed bowel distension using oral contrast (hydrosonography) although its use remains limited.^[20] The current-generation high-frequency probes provide greater spatial resolution than CT scan or MRI [Figure 6]. Contrast-enhanced USG can provide detailed information about vascularity and inflammation of the bowel.^[21]

Functional Imaging

Several new techniques are now available that can provide functional information in bowel pathologies.

MRI fluoroscopy: Changes in bowel kinetics can be evaluated on MRI fluoroscopy to demonstrate either an obstructive element or abnormalities in peristalsis. MRI fluoroscopy can

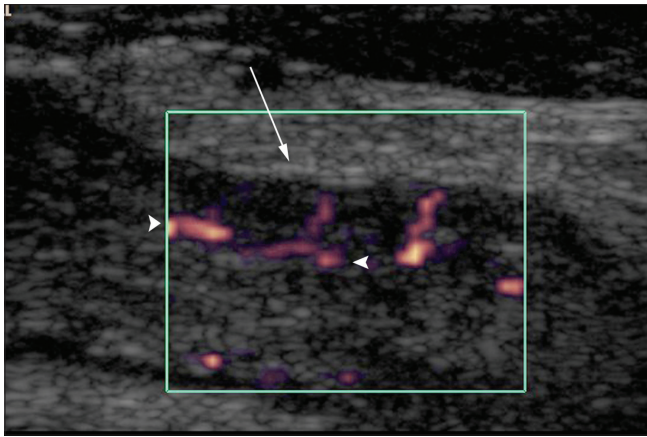


Figure 6: High-resolution USG image shows an inflamed bowel segment, with marked enhancement of the mucosal vessels (arrowheads) and engorgement of the penetrating blood vessels (arrow)

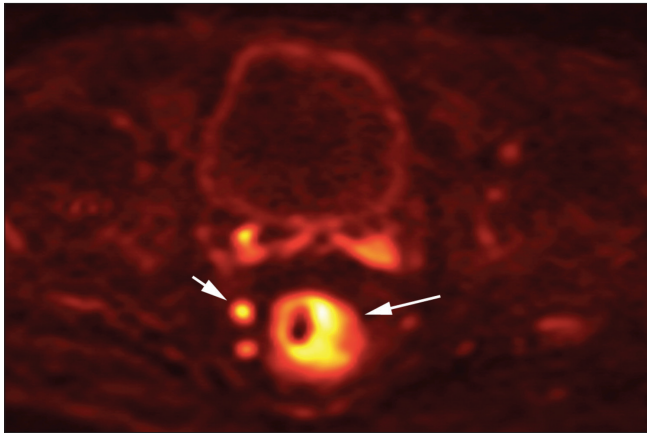


Figure 8: A patient with rectal cancer. Diffusion-weighted MRI image shows high signal in the cancer tissue (arrow) and involved lymph node in the mesorectum (short arrow)

provide functional information regarding bowel motility and may help distinguish between fibrotic strictures and functional bowel spasm.^[10]

PET/CT: Positron emission tomography (PET)/CT depends on the uptake of tracer by abnormal or highly metabolic tissue. Typically, cancers or metastases show up as hot spots due to their higher metabolic rate as compared to the surrounding tissues. The role of PET/CT in intestinal imaging is mainly related to cancer imaging and the detection of distant metastases.^[22] PET-CT also has a role in the detection of recurrent cancers and in quantifying malignancy in suspicious nodes [Figure 7].^[23-24]

Diffusion-weighted MRI imaging: Diffusion-weighted MRI signal is derived from the motion of water molecules within cells or extracellular spaces.^[25] Highly cellular tumors have restricted water diffusion and show up as areas retaining high signal intensity on high *b* value (800–1000

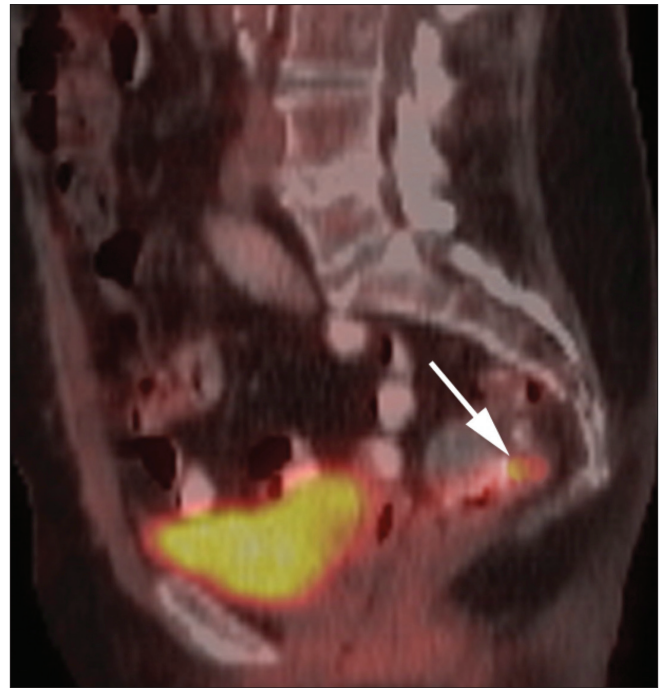


Figure 7: PET/CT image shows a recurrent rectal tumor as a hot spot (arrow) just anterior to the presacral fascia

s/mm)^[2] images. By performing diffusion imaging using different *b* values, it is possible to calculate the apparent diffusion coefficient (ADC, measured in $\mu\text{m}^2/\text{s}$). Areas of restricted diffusion show low ADC values and ADC values are inversely correlated with tumor cellularity. Therefore, reduction in ADC has been shown to have good correlation with response to cytotoxic therapy. Inflammatory tissue also shows high signal on diffusion images. Currently, diffusion imaging is mainly used for detection of abnormal cancerous tissue and involved lymph nodes.^[25] Studies have also been conducted on the detection of active inflammation in IBD patients using diffusion imaging^[26] [Figure 8].

Perfusion imaging: Perfusion CT is a technique that integrates anatomic detail with assessment of vascular physiology. Analysis of tumor enhancement, tumor blood flow, blood volume, mean transit time, and permeability–surface area product are possible. Perfusion CT is a reflection of angiogenesis in tumors, and therefore its main use is in the assessment of colorectal tumors and their response to treatment.^[27]

References

1. Balthazar EJ, Herlinger H, Maglinte D, Birnbaum BA. Clinical Imaging of the Small Intestine. 2nd ed. Germany: Springer; 2001.
2. Maglinte DD, Kelvin FM, O'Connor K, Lappas JC, Chernish SM. Current status of small bowel radiography. *Abdom Imaging* 1996;21:247-57.
3. Maglinte DDT. Small bowel imaging: A rapidly changing field and a challenge to radiology. *Eur Radiol* 2006;16:967-71.

4. Maglinte D, Sandrasegaran K, Tann M. Advances in alimentary tract imaging. *World J Gastroenterol* 2006;12:3139-45.
5. Maglinte D, Sandrasegaran K, Chiorean M, Dewitt J, McHenry L, Lappas J. Radiologic investigations complement and add diagnostic information to capsule endoscopy of small-bowel diseases. *AJR Am J Roentgenol* 2007;189:306-12.
6. Maglinte D, Sandrasegaran K, Lappas J, Chiorean M. CT Enteroclysis. *Radiology* 2007;245:661-71.
7. Maglinte D, Chernish S, Kelvin F, O'Connor K, Hage J. Crohn disease of the small intestine: Accuracy and relevance of enteroclysis. *Radiology* 1992;184:541-5.
8. Maglinte DD, Kohli MD, Romano S, Lappas JC. Air (CO₂) double-contrast barium enteroclysis. *Radiology* 2009;252:633-41.
9. Rajesh A, Sandrasegaran K, Jennings SG, Maglinte DD, McHenry L, Lappas JC, *et al.* Comparison of capsule endoscopy with enteroclysis in the investigation of small bowel disease. *Abdom Imaging* 2009;34:459-66.
10. Sinha R, Murphy P, Hawker P, Sanders S, Rajesh A, Verma R. Role of MRI in Crohn's disease. *Clin Radiol* 2009;64:341-52.
11. Lauenstein T, Schneemann H, Vogt F, Herborn C, Ruhm S, Debatin J. Optimization of oral contrast agents for MR imaging of the small bowel. *Radiology* 2003;228:279-83.
12. Ramachandran I, Sinha R, Rajesh A, Verma R, Maglinte D. Multidetector row CT of small bowel tumours. *Clin Radiol* 2007;62:607-14.
13. Sinha R, Verma R. Multidetector row computed tomography in bowel obstruction, Part 1: Small bowel obstruction. *Clin Radiol* 2005;60:1058-67.
14. Pickhardt PJ, Hassan C, Halligan S, Marmo R. Colorectal cancer: CT colonography and colonoscopy for detection-systematic review and meta-analysis. *Radiology* 2011;259:393-405.
15. Sinha R. CT colonography: A practical guide. *Indian J Radiol Imaging* 2006;16:537-41.
16. Maccioni F. Current status of gastrointestinal MRI. *Abdom Imaging* 2002;27:358-60.
17. Sinha R, Rajiah P, Murphy P, Hawker P, Sanders S. Utility of High-resolution MR imaging in demonstrating transmural pathologic changes in crohn disease. *Radiographics* 2009;29:1847-67.
18. Sinha R, Nwokolo C, Murphy PD. Magnetic resonance imaging in Crohn's disease. *BMJ* 2008;336:273-6.
19. Puylaert JB. Ultrasound of acute GI tract conditions. *Eur Radiol* 2001;11:1867-77.
20. Maconi G, Radice E, Bareggi E, Porro GB. Hydrosoneography of the Gastrointestinal Tract. *AJR Am J Roentgenol* 2009;193:700-8.
21. Migaleddu V, Quaia E, Scano D, Virgilio G. Inflammatory activity in Crohn disease: Ultrasound findings. *Abdom Imaging* 2008;33:589-97.
22. Veit-Haibach P, Kuehle CA, Beyer T, Stergar H, Kuehl H, Schmidt J, *et al.* Diagnostic accuracy of colorectal cancer staging with whole-body PET/CT colonography. *JAMA J Am Med Assoc* 2006;296:2590-600.
23. Vogel WV, Wiering B, Corstens FH, Ruers TJ, Oyen WJ. Colorectal cancer: the role of PET/CT in recurrence. *Cancer Imaging* 2005;5:S143-9.
24. Vlachou P, Sinha R, Verma R. Recurrent rectal tumour: Localization using CT-guided percutaneous "breast coil" placement prior to surgery. *Br J Radiol* 2007;80:241-2.
25. Koh D, Collins D. Diffusion-weighted MRI in the body: Applications and challenges in oncology. *AJR Am J Roentgenol* 2007;188:1622-35.
26. Oto A, Zhu F, Kulkarni K, Karczmar GS, Turner JR, Rubin D. Evaluation of diffusion-weighted MR imaging for detection of bowel inflammation in patients with Crohn disease. *Acad Radiol* 2009;16:597-603.
27. Figueiras RG, Goh V, Padhani AR, Naveira AB, Caamaño AG, Martin CV. The role of functional imaging in colorectal cancer. *AJR Am J Roentgenol* 2010;195:54-66.

Cite this article as: Sinha R. Recent advances in intestinal imaging. *Indian J Radiol Imaging* 2011;21:170-5.

Source of Support: Nil, **Conflict of Interest:** None declared.

Announcement

Android App



Download
**Android
application**

FREE

A free application to browse and search the journal's content is now available for Android based mobiles and devices. The application provides "Table of Contents" of the latest issues, which are stored on the device for future offline browsing. Internet connection is required to access the back issues and search facility. The application is compatible with all the versions of Android. The application can be downloaded from <https://market.android.com/details?id=comm.app.medknow>. For suggestions and comments do write back to us.