

# 2% Crisaborole Ointment for the Treatment of Chronic Cheilitis Caused by Lip Tattoos

Xu Liu <sup>1,\*</sup>, Qingfeng Liu <sup>1,\*</sup>, Linghong Guo <sup>1</sup>, Xian Jiang <sup>1,2</sup>

<sup>1</sup>Department of Dermatology, West China Hospital, Sichuan University, Chengdu, People's Republic of China; <sup>2</sup>Laboratory of Dermatology, Clinical Institute of Inflammation and Immunology, Frontiers Science Center for Disease-Related Molecular Network, West China Hospital, Sichuan University, Chengdu, People's Republic of China

\*These authors contributed equally to this work

Correspondence: Xian Jiang; Linghong Guo, West China Hospital, Sichuan University, #37 Guoxue Alley, Wuhou District, Chengdu, Sichuan, 610041, People's Republic of China, Tel +86-28-85423315, Fax +86-28-85422560, Email [jiangxian@scu.edu.cn](mailto:jiangxian@scu.edu.cn); [linhom.guo@foxmail.com](mailto:linhom.guo@foxmail.com)

**Abstract:** The increasing popularity of tattoo art, including facial cosmetic tattoos, has led to a growing societal acceptance of tattoos. However, complications such as lip inflammation following cosmetic lip tattoos remain a concern. This article presents the case of a 47-year-old Asian woman who experienced recurrent lip swelling, purulent discharge, and scarring after receiving lip tattoos. Despite previous treatment with corticosteroid injections yielding unsatisfactory results, the patient showed significant improvement with topical application of 2% Crisaborole, a phosphodiesterase-4 inhibitor. Crisaborole modulates intracellular cyclic adenosine monophosphate levels, thereby reducing tissue inflammation and swelling associated with chronic cheilitis. Additionally, pulse laser therapy was effective in addressing residual tattoo pigment and scar tissue. This case highlights the therapeutic challenges of managing chronic inflammatory diseases of the lips secondary to cosmetic tattoos and introduces Crisaborole as a promising treatment option, offering insights for managing similar conditions in the future.

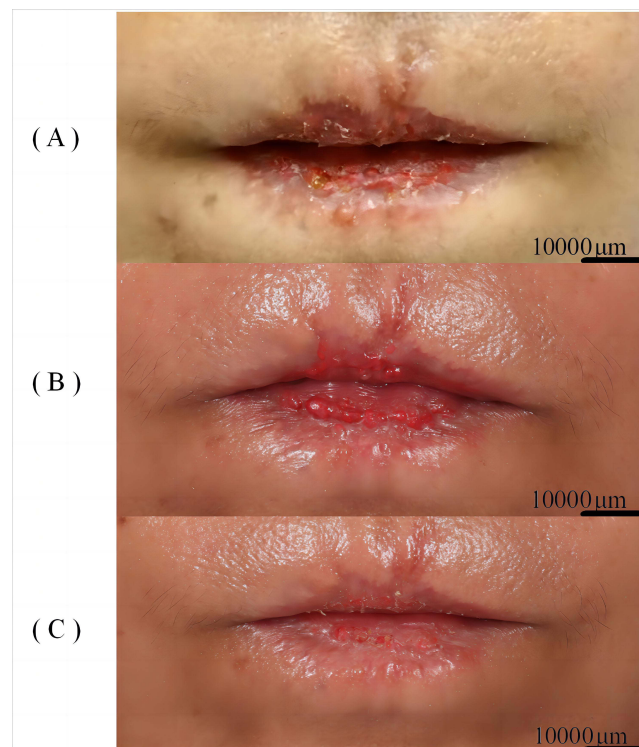
**Keywords:** lip tattoo, chronic cheilitis, Crisaborole, phosphodiesterase-4 inhibitor, laser therapy

## Introduction

As tattoo art gains increasing popularity, society's acceptance of tattoos is also growing. In particular, there is a notable market demand for facial cosmetic tattoos. However, various complications can arise following this procedure, with lip inflammation being one of the most common. The primary causes include mechanical irritation during the tattooing process, allergic reactions to components in the tattoo ink, and post-tattoo infections. Tattoo inks often contain a complex mixture of inorganic and organic pigments, solvents, additives, and contaminants, which can trigger adverse reactions in some individuals.<sup>1</sup> The most common tattoo pigments associated with allergic reactions are red, yellow, and orange, which frequently contain mercury sulfide (cinnabar), cadmium sulfide, and organic dyes.<sup>2</sup> Patients may exhibit symptoms such as redness, itching, swelling, and papules.<sup>3</sup> The frequency of chronic inflammatory reactions to tattoos is estimated to be around 1–5%.<sup>4,5</sup>

## Case Presentation

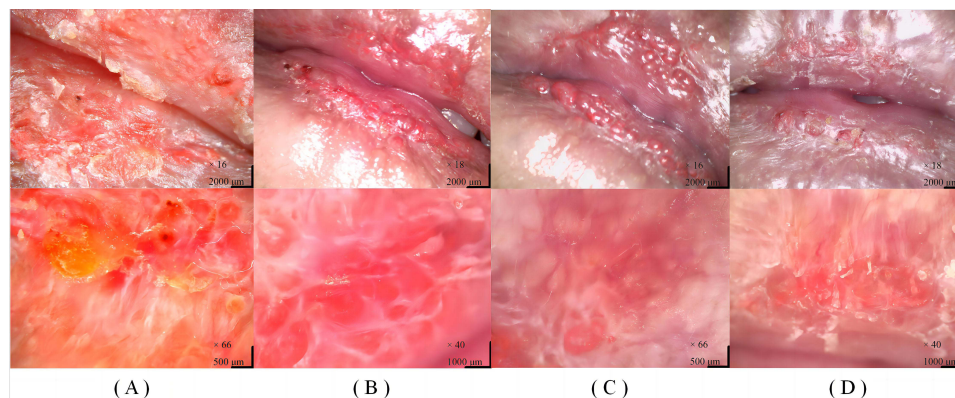
A 47-year-old Asian woman experienced recurrent lip swelling, purulent discharge, and scarring one year after receiving cosmetic lip tattoos. The tattoo ink primarily contained water, butanediol, isopropyl myristate, cyclopentasiloxane, pigments, methylparaben, and propylparaben. The patient had no significant past medical or family history. The symptoms first appeared 3 months post-tattooing and recurred every 1–2 months. Her primary care physician administered local corticosteroid injections (triamcinolone) to the affected site once a month for three months, but the patient reported no noticeable improvement.



**Figure 1** Various stages of treatment for the Case. (A) Baseline; (B) After two months of treatment with 2% Crisaborole Ointment; (C) After undergoing one session of Q-switched 532nm Nd:YAG laser treatment.

Physical examination revealed bright redness and swelling of both lips, accompanied by visible scarring. The affected area exhibited peeling skin and a small amount of yellow purulent discharge, limited to the tattooed region (Figure 1A). A bacterial culture of the purulent discharge was performed to rule out any secondary infection, which came back negative. Dermoscopy showed irregularly distributed white structures, distinct prominent branching vessels, white scales, yellow crusts, exudate, and, in some areas, gray-brown dot-like pigment deposition (Figure 2A). Despite the option of a skin biopsy, the patient opted against it. Considering the dermoscopic findings along with the medical history, the clinical diagnosis leaned towards chronic cheilitis with scarring secondary to an allergic reaction to the red tattoo pigment, likely mercury sulfide.

The use of Crisaborole for treatment was based on its anti-inflammatory properties as a PDE-4 inhibitor and its efficacy in managing other inflammatory skin conditions like atopic dermatitis.<sup>6</sup> The affected area was treated with topical application of 2% Crisaborole Ointment, applied twice daily. To mitigate potential medication-induced irritation, we advised the patient to



**Figure 2** Various stages of treatment for the Case. (A) Baseline; (B) After one month of treatment with 2% Crisaborole Ointment; (C) After two months of treatment with 2% Crisaborole Ointment; (D) After undergoing one session of Q-switched 532nm Nd:YAG laser treatment.

moisten the lips with saline-soaked gauze for 5 minutes before applying the Crisaborole Ointment, followed by the application of a fragrance-free, hypoallergenic lip moisturizer (Vaseline petroleum jelly). During the third-month follow-up, significant improvement was noted in the lesion area. Symptoms included noticeable reduction in lip swelling, disappearance of purulent discharge, considerable decrease in scaling, and no significant alteration in raised scarring. Dermoscopic examination revealed multiple red proliferative lesions with clearer boundaries, the presence of exogenous pigments, dot-like vessels, white reticular structures, and brown pigment deposits (Figure 2C).

To address the patient's cosmetic concerns, a single session of Q-switched 532nm Nd:YAG laser therapy (Revlite SI C10) was administered to eliminate residual tattoo pigment. Concurrently, the use of Crisaborole Ointment was temporarily halted. During the follow-up in the fourth month of treatment, further improvement was observed in the lesion area. Residual pigmentation was visibly eradicated, the raised scar tissue on the lips exhibited a tendency to flatten, and dermoscopy revealed multiple red proliferative lesions with clearer boundaries, presence of exogenous pigments, dot-like and linear vessels, scabs, white reticular structures, and brown pigment deposition (Figure 2D). The patient reported a substantial subjective improvement and is currently undergoing the second phase of laser treatment without recurrence. The treatment progress is depicted in (Figure 1A–C and 2A–D).

## Discussion

This case highlights the therapeutic challenge posed by chronic inflammatory reactions to cosmetic lip tattoos. The patient experienced an adverse reaction characterized by lip swelling, purulent discharge, and scarring, likely attributed to an allergic response to the red tattoo pigment, mercury sulfide. Mercury in tattoo inks has been linked to a range of complications including allergic contact dermatitis, lichenoid reactions, and pseudolymphoma.<sup>7</sup> Notably, previous treatment with local corticosteroid injections yielded unsatisfactory results, suggesting potential resistance to traditional therapies or the need for more personalized approaches.

The application of topical 2% Crisaborole Ointment demonstrated significant therapeutic effects in this case. Crisaborole, a PDE-4 inhibitor, primarily functions by modulating intracellular cAMP levels.<sup>8</sup> Increased cAMP within cells regulates various signaling pathways involved in inflammation and immune regulation. Chronic cheilitis often involves abnormal release of inflammatory mediators and cytokine overexpression, leading to localized inflammatory reactions and tissue damage. By inhibiting PDE-4 activity, Crisaborole elevates cAMP levels, suppressing the release of inflammatory mediators (eg, TNF- $\alpha$ , interleukins), reducing inflammatory cell migration, and mitigating the overall inflammatory response.<sup>9,10</sup> This results in a reduction of tissue inflammation, damage, and swelling associated with chronic cheilitis.

In tailoring this treatment approach, we considered the patient's sensitivity to medication irritation and achieved promising results by preemptively using saline compresses and a hypoallergenic lip moisturizer to mitigate potential irritation from the medication. Furthermore, a single session of Q-switched laser therapy significantly improved residual tattoo pigment and scar tissue, addressing the patient's aesthetic concerns. Ongoing observations during treatment demonstrated varying levels of efficacy at different stages, with the patient currently undergoing a second phase of laser therapy without recurrence, indicating a satisfactory and stable outcome.

## Conclusion

In conclusion, this case underscores the therapeutic challenge posed by chronic inflammatory diseases of the lips secondary to cosmetic tattoos. To our knowledge, this is the first reported successful case of Crisaborole treatment for chronic cheilitis caused by an allergic reaction to tattoo pigment. Our exploration of this treatment approach provides new insights for managing similar conditions, offering novel options for improving clinical symptoms. However, further research is needed to establish the long-term efficacy and safety of Crisaborole in this context.

## Ethics Approval and Consent for Publication

This case series has been performed in accordance with the principles stated in the Declaration of Helsinki. Written informed consent, provided by the Taylor & Francis group<sup>®</sup> for publication of this case report and including photography and medical information, were signed by the patients. Institutional approval was not required to publish the case details.

## Acknowledgments

There are no acknowledgments here.

## Funding

This study was supported by the National Natural Science Foundation of China (82073473).

## Disclosure

The authors have no conflicts of interest to declare in this work.

## References

1. Laux P, Tralau T, Tentschert J, et al. A medical-toxicological view of tattooing. *Lancet*. 2016;387(10016):395–402. doi:10.1016/S0140-6736(15)60215-X
2. Serup J. Technical and clinical complications of cosmetic tattooing. *Curr Probl Dermatol*. 2022;56:225–244.
3. Garcovich S, Carbone T, Avitabile S, et al. Cutaneous complications of tattoos. *Clin Dermatol*. 2012;30(5):609–613.
4. Wenzel S, Rittmann I, Landthaler M, et al. Adverse reactions after tattooing: review of the literature and comparison to results of a survey. *Dermatology*. 2013;226(2):138–147. doi:10.1159/000346943
5. Hutton Carlsen K, Serup J. Chronic tattoo reactions cause reduced quality of life equaling cumbersome skin diseases. *Curr Probl Dermatol*. 2015;48:71–75.
6. Paller AS, Tom WL, Lebwohl MG, et al. Efficacy and safety of crisaborole ointment, a novel, nonsteroidal phosphodiesterase 4 (PDE4) inhibitor for the topical treatment of atopic dermatitis (AD) in children and adults. *J Am Acad Dermatol*. 2016;75(3):494–503.e6. doi:10.1016/j.jaad.2016.05.046
7. Forte G, Petrucci F, Cristaudo A, et al. Market survey on toxic metals contained in tattoo inks. *Sci Total Environ*. 2009;407(23):5997–6002. doi:10.1016/j.scitotenv.2009.08.034
8. Ferrer L. Crisaborole in psoriasis: pathogenesis and clinical implications. *J Pharmacol Exp Ther*. 2022;380(1):100–104.
9. Pincelli C. PDE4 inhibition and inflammatory skin diseases. *Int J Mol Sci*. 2017;18(6):1310. doi:10.3390/ijms18061310
10. DiRuggiero M, Mancuso-Stewart E, DiRuggiero D, Zirwas M. New non-steroidal topical therapies for inflammatory dermatoses-part 3: roflumilast. *Skinmed*. 2023;21(4):264–268.

Journal of Inflammation Research

Dovepress

### Publish your work in this journal

The Journal of Inflammation Research is an international, peer-reviewed open-access journal that welcomes laboratory and clinical findings on the molecular basis, cell biology and pharmacology of inflammation including original research, reviews, symposium reports, hypothesis formation and commentaries on: acute/chronic inflammation; mediators of inflammation; cellular processes; molecular mechanisms; pharmacology and novel anti-inflammatory drugs; clinical conditions involving inflammation. The manuscript management system is completely online and includes a very quick and fair peer-review system. Visit <http://www.dovepress.com/testimonials.php> to read real quotes from published authors.

Submit your manuscript here: <https://www.dovepress.com/journal-of-inflammation-research-journal>