

# Visceral Leishmaniasis and Glomerulonephritis: A Case Report

Marwan Jabr Alwazzeah, Zaki Hajji Alhashimalsayed

Department of Internal Medicine, King Fahd Hospital of the University, Imam Abdulrahman Bin Faisal University, Saudi Arabia

## Abstract

Visceral leishmaniasis is an endemic in the southwestern region of Saudi Arabia, with a low incidence rate. Clinical presentations of visceral leishmaniasis include recurrent fever, substantial weight loss, hepatosplenomegaly and anemia. However, the clinical features may not be easily evident owing to the involvement of multiple organs. This, in turn, can cause difficulties in establishing the correct diagnosis, and subsequently, in managing the patient. Here, the authors report a case of a 42-year-old male from Jizan, southwestern Saudi Arabia, who presented with impaired renal function. After kidney biopsy, the patient was diagnosed with glomerulonephritis of unknown etiology and treated with mycophenolate and prednisone. After 3 months, the patient developed high fever with hepatomegaly and pancytopenia. Based on the investigations, a possible diagnosis of visceral leishmaniasis was considered. Accordingly, he was treated with liposomal amphotericin B, following which his condition improved significantly. This case report discusses the relationship between glomerulonephritis and visceral leishmaniasis and focuses on the potential consequences of glomerulonephritis management without investigating the etiology of the underlying diseases, especially in patients from tropical and subtropical areas.

**Keywords:** Glomerulonephritis, kala-azar, Saudi Arabia, visceral leishmaniasis

**Address for correspondence:** Dr. Marwan Jabr Alwazzeah, King Fahd Hospital of the University, Imam Abdulrahman Bin Faisal University, Dammam, Saudi Arabia.  
E-mail: mjalwazzeah@iau.edu.sa

## INTRODUCTION

Visceral leishmaniasis (VL), also called kala-azar, is a chronic infectious disease caused by the protozoan *Leishmania donovani*. It is an endemic in the tropical and subtropical regions. More than 20 leishmanial species are responsible for the following four main clinical syndromes: cutaneous leishmaniasis, mucocutaneous leishmaniasis, VL and post-kala-azar dermal leishmaniasis.<sup>[1]</sup> Sandflies of the genus *Phlebotomus* are the vectors. If left untreated, VL can be fatal in almost 100% of the cases.<sup>[2]</sup> In Saudi Arabia, according to the Ministry of Health records, the incidence of VL has decreased from 16 cases per 100,000

inhabitants in 1992 to only 2 cases per 100,000 inhabitants in 2000.<sup>[3]</sup> Notably, >70% of the VL cases in Saudi Arabia are recorded in Jizan, and the majority (>80%) of these patients are local inhabitants.<sup>[3]</sup>

Kidney involvement in VL is well-known and can manifest as glomerulonephritis, acute or chronic renal insufficiency. Here, the authors present the first case report from Saudi Arabia of VL in an adult patient with glomerulonephritis.

## CASE REPORT

A 42-year-old Saudi male from Jizan, with a comorbidity of hypertension and type 2 diabetes mellitus diagnosed

This is an open access journal, and articles are distributed under the terms of the Creative Commons Attribution-NonCommercial-ShareAlike 4.0 License, which allows others to remix, tweak, and build upon the work non-commercially, as long as appropriate credit is given and the new creations are licensed under the identical terms.

**For reprints contact:** reprints@medknow.com

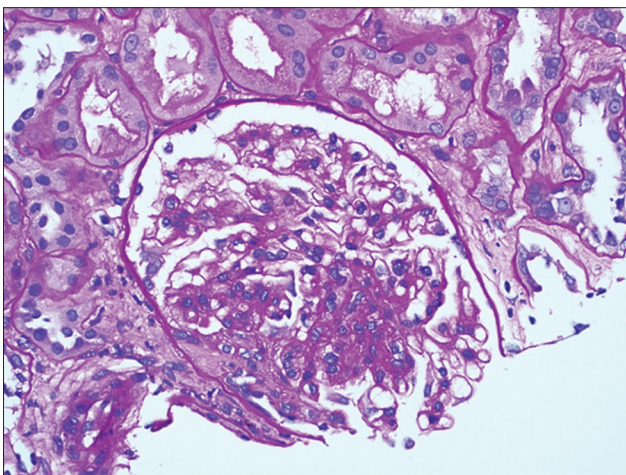
**How to cite this article:** Alwazzeah MJ, Alhashimalsayed ZH. Visceral leishmaniasis and glomerulonephritis: A case report. Saudi J Med Med Sci 2019;7:40-3.

Access this article online	
Quick Response Code:	Website: www.sjmms.net
	DOI: 10.4103/sjmms.sjmms_166_16

6 years prior (well controlled by oral antidiabetic agents: metformin 1000 mg twice daily and gliclazide 30 mg once daily), presented with impaired renal function and hematuria. After basic laboratory investigations, kidney biopsy was performed. Histological examination with light microscope revealed a global sclerosed glomeruli, minimal interstitial fibrosis and tubular atrophy [Figure 1]. A diagnosis of glomerulonephritis of unknown etiology was made and treatment with mycophenolate (1 g PO twice daily) and prednisone (20 mg PO once daily) was initiated.

After 3 months, the patient presented with a 3-week history of fever, abdominal pain and fatigue. The fever was subjective, intermittent, associated with chills and rigors, especially at night, and not relieved by paracetamol. The abdominal pain was intermittent, diffuse and colicky in nature and was associated with nausea and vomiting without blood (2–3 times/day). During these 3 weeks, the patient's appetite decreased, owing to which he lost 7 kg in weight. In addition, the patient reported a history of animal contact (goat and sheep), ingestion of raw goat milk and swimming in the valley water. There was no history of rash, cough, hemoptysis, jaundice, diarrhea, constipation, dysuria, change in urine color, arthralgia, visual disturbances, oral ulcers, genital rash, discharge or contact with tuberculosis patients.

On physical examination, the patient was found to be obese, sweating, not jaundiced or cyanosed. He was conscious, alert and oriented to time, place and person. His vital signs were as follows: body temperature, 38.6°C; pulse rate, 98 beats/min; respiratory rate, 24 breaths/min; blood pressure, 125/85 mmHg; and oxygen saturation, 100% on room air. He was pale, with normal jugular



**Figure 1:** Histopathology (light microscope) showing a globally sclerosed glomerulus, minimal interstitial fibrosis, tubular atrophy and no arteriolar hyalinosis or arterial sclerosis

venous pressure and no oral ulcers or thrush. Abdominal examination revealed mild epigastric tenderness and a palpable liver 4 cm below the costal margin with a 15-cm liver span. The rest of the examinations were within normal limits.

Laboratory investigations on admission revealed a white blood cell (WBC) count of 2.65/mcL (neutrophils, 72.1%; lymphocytes, 23.2%; monocytes, 4%; and eosinophils, 0.7%). Results of other hematological examinations were as follows: hemoglobin level, 8.8 g/L; erythrocyte sedimentation rate, 88 mm/h; platelet count, 87,000/mcL; and reticulocyte count, 1.28%. Level of ferritin was 1000 ng/mL, with a transferrin saturation of 11.22 mg/dL. Estimation of electrolytes showed sodium 138 mEq/L, potassium 3.2 mEq/L and bicarbonate 25 mmol/L. Liver function tests showed that total protein was 6.1 g/dL, albumin 3.2 g/dL, total bilirubin 1.2 mg/dL, alanine transaminase 71 IU/L, aspartate transaminase 42 IU/L, alkaline phosphatase 179 IU/L and gamma-glutamyl transferase 447 IU/L. International normalized ratio was 0.8. Renal function tests showed that blood urea nitrogen was 12 mg/dL and creatinine 2.15 mg/dL. Level of lactate dehydrogenase was 732 U/L and C-reactive protein 53 mg/L. Urine analysis showed 2–5 WBCs/high-power field and 10–25 red blood cells/high-power field with no nitrites. Sickling test and direct/indirect Coombs test were negative, and the stool test result was normal.

Chest X-ray and electrocardiogram were normal. Abdominal ultrasound showed an enlarged liver (16.2-cm liver span) and a mildly enlarged spleen (14 cm in length). Kidneys were normal in size, with a mild increase in the echogenicity of renal parenchyma, but no hydronephrosis or ascites.

The serological tests for viral hepatitis, human immunodeficiency virus, Epstein–Barr virus, cytomegalovirus, *Toxoplasma* and *Brucella* were negative. Rheumatoid factor, antinuclear antibody, antineutrophil cytoplasmic antibody, antiglomerular basement membrane antibody, anti-Sjögren's syndrome A and B antibodies and cryoglobulin were negative. Malaria smear and blood cultures were also negative.

The patient's condition continued to deteriorate and he developed continuous fever of up to 40.5°C. Repeated tests after 5 days revealed the following: WBC, 1.4/mcL; hemoglobin, 6.7 g/dL; platelet, 55,000/mcL; creatinine, 3.3 mg/dL; C-reactive protein, 151 mg/L; total bilirubin, 2.9 mg/dL; alkaline phosphatase, 460 IU/L; alanine aminotransferase, 80 IU/L; aspartate aminotransferase,

138 IU/L; gamma-glutamyl transferase, 651 IU/L; albumin, 2.5 g/dL; and lactate dehydrogenase, 1400 U/L.

Bone marrow aspirate showed mild hypocellular marrow with no evidence of dysplasia or malignancy. Bone marrow culture for *Brucella* was negative. Further, Leishman-Donovan bodies were not detected by light microscope. Polymerase-chain reaction test for the diagnosis of tuberculosis, serological tests for dengue fever and Q fever as well as  $\beta$ -D-Glucan and galactomannan antigen tests were all negative. Liver biopsy showed granulomatous hepatitis with extramedullary hematopoiesis. After 1 week of admission, the patient was treated empirically with broad-spectrum antibiotic (meropenem intravenously, 1 g every 8 h for 6 days); however, there was no improvement.

Additional serological testing using enzyme-linked immunosorbent assay (ELISA) revealed the presence of anti-*Leishmania* antibodies. Based on this, the patient was started on liposomal amphotericin B course as a treatment for VL (4 mg/kg intravenous on Days 1–5, 10, 17, 24, 31 and 38), despite the lack of a definitive diagnosis. After 1 week, the patient improved clinically, the fever subsided, the laboratory parameters began to improve and at the end of liposomal amphotericin B course, all tests returned to normal.

## DISCUSSION

VL is a chronic protozoal infection that is also known to affect kidneys, in which the range of clinical manifestations include glomerulonephritis.<sup>[4]</sup> On the other hand, immunosuppressive conditions can affect the clinical course of VL with a rapid progress and threatening sequelae.<sup>[5]</sup> In the case presented here, VL was a possible underlying etiology of glomerulonephritis, which was diagnosed 3 months before the febrile illness. Further, treating glomerulonephritis with immunosuppressant drugs may have resulted in progressing VL.

VL can present with varying clinical features, and the involvement of kidney is known to alter tubular and glomerular function, resulting in proteinuria, hematuria, acidification defect and urinary concentration abnormalities.<sup>[4]</sup> Renal involvement in VL can result in interstitial, glomerular and vascular damage;<sup>[6]</sup> interstitial nephritis;<sup>[6,7]</sup> glomerular sclerosis<sup>[8]</sup> and membranoproliferative glomerulonephritis,<sup>[4,9-11]</sup> which lead to nephritic syndrome, acute or chronic renal failure.<sup>[4]</sup> Direct invasion of the renal parenchyma by the parasite results in kidney damage, especially among immunocompromised patients.<sup>[6]</sup> Immune complex

deposition and T-cell adhesion molecules' activation have a pathogenic role in glomerulonephritis related to VL.<sup>[6]</sup> The patient in the current case report was originally from an area endemic for leishmaniasis. The authors recommend investigating the underlying causes of glomerulonephritis in such cases including the possible correlation between VL and glomerulonephritis.

Nephropathy is a well-known complication of diabetes, with different histologic changes such as membrane thickening or glomerular sclerosis.<sup>[12]</sup> In this case, the role of diabetes in developing the histopathological changes observed in the kidney biopsy should be addressed carefully as an underlying etiology of glomerulonephritis. On the other hand, longstanding diabetes affects the immune system and can increase the rate and severity of infections.<sup>[13]</sup>

VL is a parasitic infection that has been added to the growing list of opportunistic microbial infections<sup>[14]</sup> and is frequently reported in patients with HIV,<sup>[15-17]</sup> bone marrow transplant or in those undergoing solid-organ transplant including kidney.<sup>[18,19]</sup> CD4<sup>+</sup> T helper cells, interferon  $\gamma$ , dendritic cells and macrophages are key components of antileishmanial defense, and immunosuppressive therapy that interferes with those components can lead to the development of VL.<sup>[20]</sup> The role of immunosuppressive drugs that our patient received is clear in predisposing him to opportunistic infections.

In some cases, establishing a definitive diagnosis of VL can be difficult because of the numerous differential diagnosis and presence of other endemic infections. Nevertheless, a diagnosis can be made based on the laboratory findings of the affected tissue being positive for the parasite by light microscopic examination, culture or animal inoculation; detection of parasite DNA in tissue samples; or through immunodiagnosis by detection of the parasite antigen or antibodies or by an assay for *Leishmania*-specific cell-mediated immunity.<sup>[21]</sup> In our case, history of febrile illness and clinical findings were suggestive of VL. Further, the presence of pancytopenia and the absence of a definitive diagnosis for any viral, bacterial or fungal infection as well as for any active autoimmune disease or underlying malignancy also supported the possible diagnosis of VL. Although the Leishman-Donovan bodies were not detected in the patient's bone marrow samples, the authors did not rule out VL, as there are well-described instances in the literature where amastigotes were not demonstrable in the bone marrow.<sup>[22]</sup>

It should be noted that definitive diagnosis of VL cannot be made using serological tests such as ELISA because of

its inherent disadvantage of being positive in a significant proportion of healthy individuals and remaining positive for long periods after cure.<sup>[22]</sup> However, a positive serological test along with excellent response to amphotericin B liposomal course, which is a specific treatment for VL, would increase the probability of VL as the final diagnosis.

In conclusion, the authors believe that an etiological approach, rather than a syndromic approach, to newly diagnosed glomerulonephritis is crucial for avoiding mismanagement. Endemic infections can be an underlying cause of manifested renal disease. Investigations to rule out infectious causes, especially parasitic infections in endemic areas, such as schistosomiasis, malaria and leishmaniasis, are important in management of patients with glomerulonephritis.

### Financial support and sponsorship

Nil.

### Conflicts of interest

There are no conflicts of interest.

### REFERENCES

- Clementi A, Battaglia G, Floris M, Castellino P, Ronco C, Cruz DN, *et al.* Renal involvement in leishmaniasis: A review of the literature. *NDT Plus* 2011;4:147-52.
- World Health Organization. Manual on Case Management and Surveillance of the Leishmaniasis in the WHO European Region. Available from: [http://www.who.int/leishmaniasis/resources/EURO\\_WHO\\_Leish\\_manual\\_on\\_case\\_management\\_and\\_surveillance\\_9789289052511\\_2017.pdf](http://www.who.int/leishmaniasis/resources/EURO_WHO_Leish_manual_on_case_management_and_surveillance_9789289052511_2017.pdf). [Last accessed on 2018 May 03].
- Al-Jaser MH. Studies on the epidemiology of malaria and visceral leishmaniasis in Jizan area, Saudi Arabia. *J King Saud Univ Sci* 2006;19:9-19.
- da Silva Junior GB, Barros EJ, Daher ED. Kidney involvement in leishmaniasis – A review. *Braz J Infect Dis* 2014;18:434-40.
- van Griensven J, Carrillo E, López-Vélez R, Lynen L, Moreno J. Leishmaniasis in immunosuppressed individuals. *Clin Microbiol Infect* 2014;20:286-99.
- Ortiz M, Mon C, Herrero JC, Oliet A, Rodríguez I, Ortega O, *et al.* Glomerulonephritis and cryoglobulinemia: First manifestation of visceral leishmaniasis. *Clin Nephrol* 2015;83:370-7.
- Duarte MI, Silva MR, Goto H, Nicodemo EL, Amato Neto V. Interstitial nephritis in human kala-azar. *Trans R Soc Trop Med Hyg* 1983;77:531-7.
- Leblond V, Beaufile H, Ginsburg C, Bricaire F, Danis M, Deray G, *et al.* Collapsing focal segmental glomerulosclerosis associated with visceral leishmaniasis. *Nephrol Dial Transplant* 1994;9:1353.
- Suankratay C, Suwanpimolkul G, Wilde H, Siriyasatien P. Autochthonous visceral leishmaniasis in a human immunodeficiency virus (HIV)-infected patient: The first in Thailand and review of the literature. *Am J Trop Med Hyg* 2010;82:4-8.
- Enriquez R, Sirvent AE, Padilla S, Toro P, Sánchez M, Millán I, *et al.* Membranoproliferative glomerulonephritis due to visceral leishmaniasis in an HIV patient. *Am J Case Rep* 2015;16:8-11.
- Dutra M, Martinelli R, de Carvalho EM, Rodrigues LE, Brito E, Rocha H, *et al.* Renal involvement in visceral leishmaniasis. *Am J Kidney Dis* 1985;6:22-7.
- Adler S. Diabetic nephropathy: Linking histology, cell biology, and genetics. *Kidney Int* 2004;66:2095-106.
- Larkin JG, Frier BM, Ireland JT. Diabetes mellitus and infection. *Postgrad Med J* 1985;61:233-7.
- Badaró R, Carvalho EM, Rocha H, Queiroz AC, Jones TC. *Leishmania donovani*: An opportunistic microbe associated with progressive disease in three immunocompromised patients. *Lancet* 1986;1:647-9.
- Fernández-Guerrero ML, Aguado JM, Buzón L, Barros C, Montalbán C, Martín T, *et al.* Visceral leishmaniasis in immunocompromised hosts. *Am J Med* 1987;83:1098-102.
- Clevenbergh P, Okome MN, Benoit S, Bendini JC, De Salvador F, Elbeze M, *et al.* Acute renal failure as initial presentation of visceral leishmaniasis in an HIV-1-infected patient. *Scand J Infect Dis* 2002;34:546-7.
- Távora LG, Nogueira MB, Gomes ST. Visceral leishmaniasis/HIV co-infection in Northeast Brazil: Evaluation of outcome. *Braz J Infect Dis* 2015;19:651-6.
- Simon I, Wissing KM, Del Marmol V, Antinori S, Rimmelink M, Nilufer Broeders E, *et al.* Recurrent leishmaniasis in kidney transplant recipients: Report of 2 cases and systematic review of the literature. *Transpl Infect Dis* 2011;13:397-406.
- Dettwiler S, McKee T, Hadaya K, Chappuis F, van Delden C, Moll S, *et al.* Visceral leishmaniasis in a kidney transplant recipient: Parasitic interstitial nephritis, a cause of renal dysfunction. *Am J Transplant* 2010;10:1486-9.
- Bogdan C. Leishmaniasis in rheumatology, haematology and oncology: Epidemiological, immunological and clinical aspects and caveats. *Ann Rheum Dis* 2012;71 Suppl 2:i60-6.
- Sundar S, Rai M. Laboratory diagnosis of visceral leishmaniasis. *Clin Diagn Lab Immunol* 2002;9:951-8.
- Srivastava P, Dayama A, Mehrotra S, Sundar S. Diagnosis of visceral leishmaniasis. *Trans R Soc Trop Med Hyg* 2011;105:1-6.