



# Functional Complications of Patellar Instability Treatment with Medial Patellofemoral Ligament Reconstruction with the Medial Third of the Patellar Tendon with a Minimum 5-Year Follow-Up\*

## *Complicações funcionais do tratamento da instabilidade patelar com reconstrução do ligamento femoropatelar medial com terço medial do tendão patelar com acompanhamento mínimo de 5 anos*

Gilberto Luis Camanho<sup>1</sup> Riccardo Gomes Gobbi<sup>2</sup> Marta Halasz de Andrade<sup>3</sup>

<sup>1</sup>Department of Orthopedics and Traumatology, Faculdade de Medicina, Universidade de São Paulo, São Paulo, SP, Brazil

<sup>2</sup>Knee Group, Institute of Orthopedics and Traumatology, Hospital das Clínicas, Faculdade de Medicina, Universidade de São Paulo, São Paulo, SP, Brazil

<sup>3</sup>Instituto Ortopédico Camanho, São Paulo, SP, Brazil

Address for correspondence Riccardo Gomes Gobbi, PhD, Instituto de Ortopedia e Traumatologia, Hospital das Clínicas, Faculdade de Medicina, Universidade de São Paulo, Rua Ovídio Pires de Campos, 333, 3° andar, Cerqueira César, São Paulo, SP, 05403-010, Brazil (e-mail: r.gobbi@hc.fm.usp.br).

Rev Bras Ortop 2022;57(2):308–313.

### Abstract

**Objective** To evaluate major complications after a minimum of 5 years of follow-up after acute or recurrent patellar dislocation treated with medial patellofemoral ligament (MPFL) reconstruction with the medial third of the patellar tendon, with or without associated medialization of the tibial anterior tuberosity (TAT).

**Methods** A total of 50 patients were included, with a minimum follow-up of 5 years. The patients were evaluated regarding complications such as joint stiffness, recurrence of patellar dislocation, subjective instability reported by patients, and inability to return to the previous level of physical activity.

**Results** The mean follow-up was of  $8.9 \pm 2.6$  years, with a minimum of 6 and maximum of 15 years; 64% of the patients were women, with a mean age of  $27 \pm 11.2$  years old; 24% were submitted to TAT osteotomy for simultaneous medialization; and 46% were acute cases. Only 9 poor results (18%) were found, all resulting

### Keywords

- ▶ knee
- ▶ patellar dislocation
- ▶ joint instability
- ▶ ligaments
- ▶ recurrence

\* The present study was developed at the Institute of Orthopedics and Traumatology of the Hospital das Clínicas, Faculdade de Medicina da Universidade de São Paulo, São Paulo, SP, Brazil.

received  
May 25, 2020  
accepted  
November 3, 2020  
published online  
December 13, 2021

DOI <https://doi.org/10.1055/s-0041-1729570>.  
ISSN 0102-3616.

© 2021. Sociedade Brasileira de Ortopedia e Traumatologia. All rights reserved.

This is an open access article published by Thieme under the terms of the Creative Commons Attribution-NonDerivative-NonCommercial-License, permitting copying and reproduction so long as the original work is given appropriate credit. Contents may not be used for commercial purposes, or adapted, remixed, transformed or built upon. (<https://creativecommons.org/licenses/by-nc-nd/4.0/>)

Thieme Revinter Publicações Ltda., Rua do Matoso 170, Rio de Janeiro, RJ, CEP 20270-135, Brazil

from recurrence of dislocation (12%) and complaint of subjective instability (6%) at between 36 and 60 months of follow-up. No other complications occurred. Among the poor results, five occurred in cases of acute dislocation, and four in recurrent cases, and only one had undergone TAT osteotomy.

**Conclusion** Reconstruction of the MPFL with the medial third of the patellar tendon, associated or not with TAT medialization osteotomy, is an alternative in the treatment of acute or chronic patellar instability, with a failure rate of only 18% in at least 5 years of follow-up. In addition, it is safe treatment, that does not present other complications.

## Resumo

**Objetivo** Avaliar complicações maiores após um mínimo de 5 anos de acompanhamento após luxação aguda ou recidivante da patela tratada com reconstrução do ligamento femoropatelar medial (LFPM) com terço medial do tendão patelar, com ou sem medialização da tuberosidade anterior da tíbia (TAT) associada.

**Métodos** Um total de 50 pacientes foram incluídos, com acompanhamento mínimo de 5 anos. Os pacientes foram avaliados em relação à ocorrência de complicações como rigidez articular, recidiva de luxação patelar ou instabilidade subjetiva relatada pelos pacientes, e incapacidade de retorno ao nível prévio de atividades físicas.

**Resultados** O acompanhamento médio foi de  $8,9 \pm 2,6$  anos, com mínimo de 6 e máximo de 15 anos; 64% dos pacientes eram mulheres, com média de idade de  $27 \pm 11,2$  anos; 24% dos pacientes foram submetidos a osteotomia da TAT para medialização concomitantemente; e 46% eram casos agudos. Foram constatados apenas 9 maus resultados (18%), todos decorrentes de recidiva da luxação (12%) e de queixa de instabilidade subjetiva (6%), ocorridos entre 36 e 60 meses de acompanhamento. Não ocorreram outras complicações. Dentre os maus resultados, cinco ocorreram em casos de luxação aguda, e quatro em casos recidivantes, e apenas um havia sido submetido a osteotomia da TAT.

**Conclusão** A reconstrução do LFPM com terço medial do tendão patelar, associada ou não à osteotomia de medialização da TAT, é uma alternativa no tratamento da instabilidade patelar aguda ou crônica, com falha de apenas 18% em acompanhamento mínimo de 5 anos. Além disso, é um tratamento seguro, sem apresentar outras complicações.

## Palavras-chave

- ▶ joelho
- ▶ luxação patelar
- ▶ instabilidade articular
- ▶ ligamentos
- ▶ recidiva

## Introduction

Patellofemoral instability is a very challenging complaint in clinical practice. However, its major manifestations, acute and recurrent patellofemoral dislocation, are uncommon. Acute dislocation occurs in only between 2 and 3% of knee traumas, and failure of its recognition is one of the most frequent causes of diagnostic error in cases of acute knee injuries.<sup>1</sup>

Acute cases of patellofemoral dislocation traditionally received conservative treatment until the acquirement of knowledge of the medial patellofemoral ligament (MPFL), which culminated in an important change in treatment principles. Several authors suggest repair or reconstruction of this ligament in acute cases, avoiding recurrences of first-time dislocation that reach > 50%.<sup>2-5</sup>

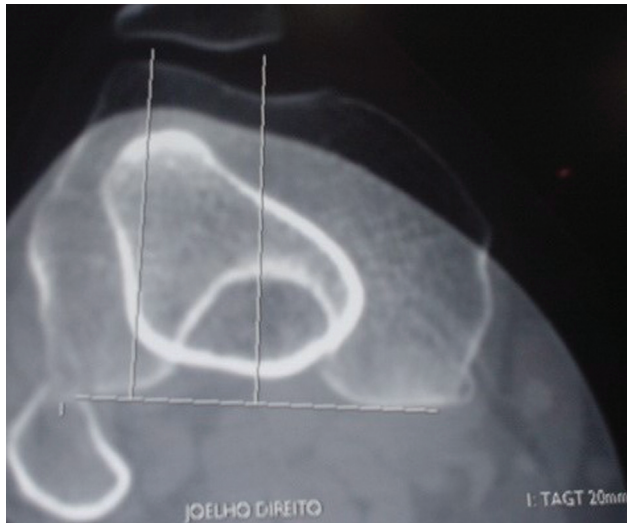
Predisposing factors have always been highly valued, especially in chronic cases, and the so-called "*à la carte menu*" dominated the therapeutic line. Today, after the knowledge and broad assimilation of the MPFL since the beginning of the 2000s, the reconstruction of the MPFL has assumed a fundamental role in the treatment of patellar instability cases.<sup>6</sup>

Our group recognized and studied the MPFL,<sup>7</sup> and initially started to repair it in acute and in some chronic cases.<sup>2</sup> Due to some repair failures, we began to reconstruct it in acute and chronic cases. That study culminated in the development of the technique using the medial third of the patellar tendon as a graft,<sup>8</sup> and its validation in acute cases compared with conservative treatment without any case of dislocation recurrence at 38 months of follow-up.<sup>3,9</sup>

The present study aims to describe major complications and late recurrences after a minimum of 5 years of follow-up in patients who, after acute or recurrent dislocation of the patella, had the MPFL reconstructed with the medial third of the patellar tendon, with or without associated medialization of the tibial anterior tuberosity (TAT).

## Methods

We included patients treated by the authors between 2005 and 2015 who presented with patellofemoral instability and were submitted to surgery to reconstruct the MPFL with a graft of the medial third of the patellar tendon, and with at least 5 years of follow-up. All patients followed the



**Fig. 1** Axial computed tomography slicing with 20 mm anterior tuberosity distance from the tibia to the trochlear groove measurement.

institutional rehabilitation protocol performed by the same team. The diagnosis of patellar instability was confirmed after history and suggestive clinical examination performed by a physician experienced in knee surgery, and by compatible imaging (radiography and magnetic resonance imaging [MRI]).

Dislocation was classified in the present study as acute when treated in the first 90 days of traumatic first-time dislocation, and chronic after this period or when it was recurrent ( $\geq 2$  episodes of complete patellar dislocation).

All patients, prior to surgery, were evaluated by radiography and computed tomography (CT) according to Dejour's precepts,<sup>10,11</sup> and also by MRI according to the experience of our group.<sup>12-15</sup> Patellar height, trochlear dysplasia, anatomical axis alignment, anterior tuberosity distance from the tibia to the trochlear groove (TAGT) and chondral lesions were evaluated. Only patients who did not have indication for patella lowering (Caton-Deschamps index  $>1.3$ ),

trochleoplasty (type B and D trochlear dysplasia with bump  $>5$ mm), surgical treatment of chondral injury or corrective axis osteotomies were included. As a procedure associated with the reconstruction of the MPFL, it was accepted only the inclusion of medialization of the TAT by Elmslie-Trillat<sup>16</sup> surgery in cases of TAGT  $\geq 20$  mm (**Figure 1**).

For the reconstruction of the MPFL, a 0.5 cm medial part of the patellar tendon was used, with tibial disinsertion and maintaining insertion in the patella, with subperiosteal detachment up to the proximal third of the patella in the anatomical position of the ligament.<sup>8,17</sup> The prepared graft is then fixed to the medial femoral condyle, at a point proximal and posterior to the medial epicondyle, between this and the tubercle of the adductors,<sup>17,18</sup> as shown in **Figure 2**.

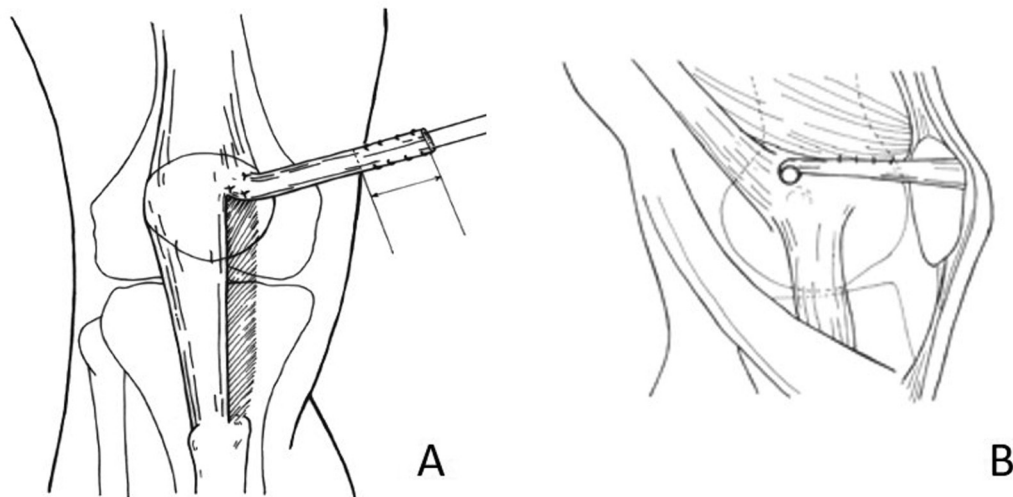
For patients with indication of the Elmslie-Trillat apud Gomes et al. technique,<sup>19</sup> the medialization of the TAT was enough to correct the TAGT for a value between 10 and 15 mm, and fixation with spongy screw. With the knee at 90° flexion, it was checked whether the patella was centered on the condyles and if the TAT was aligned with the trochlear groove to define the final position of the correction. The reconstruction of the MPFL followed the same steps described above **Figure 3**.

The patients were instructed to use an immobilizer for 1 week and crutches for 15 days after the procedure. Physical therapy began in the 1<sup>st</sup> postoperative days and lasted for 2 to 3 months. The goal was total gain of movement and recovery of muscle strength.

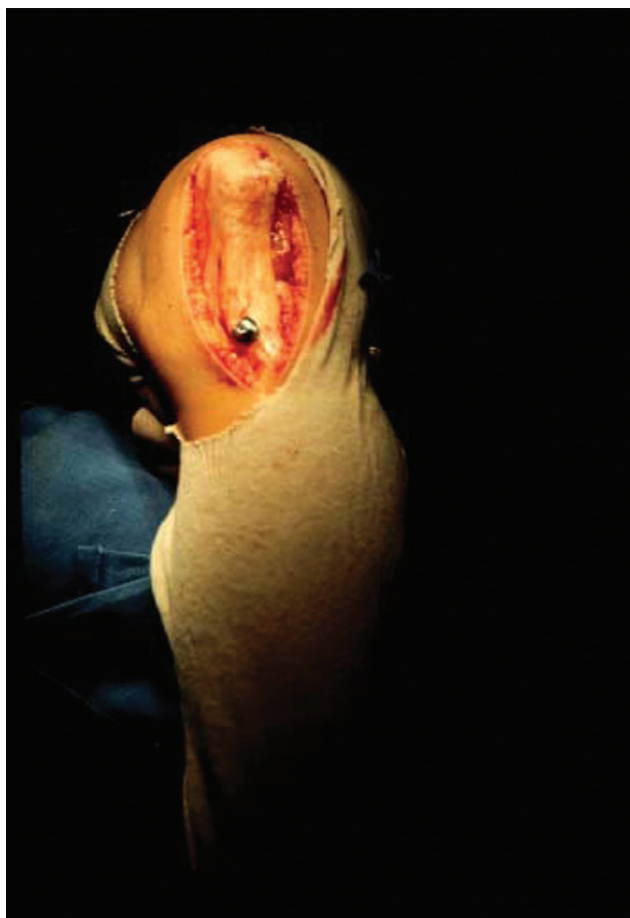The minimum follow-up was of 5 years. The occurrence of complications was determined in the last patient consultation, which defines the final follow-up time.

The patients were divided into two groups at the authors' discretion, according to the presence of the following major complications:

- Good result: return to the same level of physical activity prior to dislocation and absence of new dislocations or complaint of subjective instability;



**Fig. 2** A: Preparation of 0.5 cm medial of the patellar tendon until the transition between the proximal third and the middle of the patella. B: Fixation of the graft between the medial epicondyle and the tubercle of the adductors.



**Fig. 3** Tibial anterior tuberosity medialization fixed with a spongy screw (according to the Elmslie-Trillat technique).

- Poor result: inability to return to previous levels of physical activity, joint limitation (stiffness if loss >10° in knee range of motion), occurrence of new episodes of dislocation (recurrence) or subjective symptomatic instability reported by the patient.

**Results**

Fifty patients were included. From these, 23 (46%) were acute cases and 27 (54%) were chronic. Females were the most frequently affected, comprising 32 (64%) patients, with the right side being affected in 26 (52%) patients.

Most patients were < 30 years old, with a mean age of 27 years ± 11.2 years old, minimum of 14 and maximum of 58 years old, and with the following distribution:

- < 20 years old: 18 cases (36%);
- from 20 to 30 years old: 14 cases (28%);
- from 30 to 40 years old: 13 cases (26%);
- over 40 years old: 5 cases (10%).

In relation to follow-up time:

- between 5 and 10 years: 34 cases (68%);
- > 10 years: 16 cases (32%).

Predisposing factors (patella alta, dysplastic trochlea, patellar lateral inclination and valgus axis in vain) were

evaluated. Among the 23 patients with acute episodes, 15 (70%) had at least one predisposing factor. Patella alta (Caton-Deschamps between 1.2 and 1.3) was the most frequent, and was present in 8 patients. Among the 27 chronic cases, only 2 did not have a predisposing factor. The patella alta was the most frequent predisposing factor, and it was present in 13 patients. We did not have any patients with a valgus > 15°.

Regarding the medialization of the TAT, distal realignment was performed in 5 (21.7%) acute cases and in 7 (26%) chronic cases.

The overall sample presented 41 good results (82%) and 9 poor results (18%). Young patients (< 30 years old) had 78% of the poor results, with 3 cases of poor results in patients < 20 years old (16.7% of the age group), 4 between 20 and 30 years old (28.6% of the age group), and only 2 in patients > 30 years old (11% of the age group).

Regarding the time of surgery, 5 (55%) of the poor results were in patients with acute dislocation (21.7% of these), against 4 (45%) chronic cases (14.8% of these).

The main criterion of poor outcome was the occurrence of a new episode of dislocation (6 of the 9 cases; 67%), all occurring between the 3<sup>rd</sup> and 5<sup>th</sup> year of follow-up. Of these, 3 patients presented with acute cases, which is equivalent to 50% of the recurrences of instability in the sample. The other three cases with poor results consisted of complaints of subjective instability, without manifestation of complete dislocation. Among the 12 patients submitted to distal realignment, only 1 chronic case (8% of them) presented poor results due to a new dislocation. There was no case of stiffness or of inability to return to previous activities other than recurrence of instability.

The data are summarized in ►Table 1, and cases are separated into good and poor results in ►Table 2.

**Table 1** Summary of the series

GENDER	Male	18 (36%)
	Female	32 (64%)
SIDE	Right	26 (52%)
	Left	24 (48%)
AGE		27 ± 11.2 years old min-max 14–58 years old
FOLLOW UP		8.9 ± 2.6 years min-max 6–15 years
ATT OSTEOTOMY		12 (24%)
INSTABILITY TYPE	Acute	23 (46%)
	Chronic	27 (54%)
RESULT	Good	41 (82%)
	Poor	9 (18%)
POOR RESULT REASON	Relapse	6 (67% of the poor, 12% of the total)
	Subjective instability	3 (33% of the poor, 6% of the total)

Abbreviation: ATT, anterior tibial tuberosity.

**Table 2** Data separated by good and poor results

		Good result (n = 41)	Poor result (n = 9)
GENDER	Male	14 (34%)	4 (44%)
	Female	27 (66%)	5 (56%)
SIDE	Right	22 (54%)	4 (44%)
	Left	19 (46%)	5 (56%)
AGE (years old)		27.2 ± 11.3	26.1 ± 11.1
MONITORING (years)		8.8 ± 2.5	8.9 ± 3
ATT OSTEOTOMY (n = 12)		11 (92% of osteotomies)	1 (8% of osteotomies)
INSTABILITY TYPE	Acute	18 (44%)	5 (56%)
	Chronic	23 (56%)	4 (44%)
POOR RESULT REASON			New dislocation: 6 (67%); Subjective instability: 3 (33%)

Abbreviation: ATT, anterior tibial tuberosity.

## Discussion

The main importance of the present study is to describe the complications of acute and chronic patients with patellofemoral dislocation, treated by reconstruction of the MPFL with the medial third of the patellar tendon, after a minimum of 5 years of follow-up.

The discussion regarding the surgical or conservative indication for acute patellar dislocation was extensive in previous studies of the group, in which we demonstrated percentages of failure > between 35 and 50% in up to 2 years in patients who had their dislocations treated conservatively.<sup>2,3</sup> Similarly, Maenpää et al.<sup>20</sup> show percentages > 50% of dislocation recurrence in 100 patients treated conservatively after a mean of 13 years of follow-up, a much higher rate than the surgical failures that occurred in the present series (18%), with an average follow-up of 9 years.

Predisposing factors are very prevalent in patients with patellar instability.<sup>10</sup> From the 23 patients with acute symptoms, 15 had predisposing factors, 8 of which were cases of patella alta. From the 27 chronic cases, 25 had some predisposing factor, 13 with a patella alta. No cases of distalization were included, and none of the patients had a Caton-Deschamps index > 1.3.

Distal realignment in 12 patients did not bring any adverse problems. A slightly higher percentage of chronic cases underwent distal realignment. We believe that this fact was expected, since cases that develop recurrent/chronic instability tend to have a more dysplastic anatomical profile.<sup>10</sup>

The distribution regarding gender, side and age was similar to the samples previously studied by the group, being representative of the population with patellar instability.

The results found reaffirm our practice of indicating the reconstruction of the MPFL, associated or not with distal realignment, as effective in the treatment of patellar dislocation, whether acute or recurrent. The results of the reconstruction of the MPFL in the treatment of acute dislocations with the described technique have already been published by our group, with absence of episodes of dislocation after

38 months of follow-up.<sup>3</sup> Similar findings are found in several studies of acute dislocations, already included in meta-analyses.<sup>5</sup> The occurrence of recurrence of instability after this period (all of our cases occurred after 36 months), draws attention to the fact that the result of the treatment of patellar instability should be evaluated in the long term, because patients present varying degrees of dysplasia, often borderline without indication of correction, but maintain a higher risk of instability than the normal population. In this sense, patients with patellar instability deserve attention for a much longer period than a patient undergoing anterior cruciate ligament reconstruction, for example.

Regarding the treatment of chronic/recurrent instabilities, few comparative studies are found, and most of the data come from case series. Vavalle et al.<sup>21</sup> published 16 cases of MPFL reconstruction with good results after 38 months of follow-up in patients with chronic patellofemoral dislocation. The authors used the quadriceps tendon as a graft for reconstruction. There were no cases of new dislocations in the reported series.<sup>21</sup> Slenker et al.<sup>22</sup> studied 35 patients with chronic patellofemoral instability with episodes of dislocation, treated by repair of the MPFL, made with allograft in 23 cases and with flexor tendons tendon in 12 cases. They obtained good results after a mean follow-up of 21 months, with improvement of the Kujala index from 49 preoperatively to 89.5 in the postoperative period.<sup>22</sup> A recent systematic review included only five studies of recurrent instability, concluding only that the reconstruction of the MPFL presents higher clinical scores in relation to medial plication surgery.<sup>23</sup>

We did not perform a numerical evaluation of functional scores of the results, using quantitative methods, such as the study by Kujala et al.<sup>24</sup> This evaluation has already been published in other studies, in comparison with surgical and conservative treatment methods; the results were much better in patients who underwent surgical treatment for repair or MPFL reconstruction. Our previous studies showed a Kujala mean of 89 points after 3 years of follow-up, which is very similar to the rest of the literature and other techniques and grafts.<sup>25</sup> The functionality of the patients remained in

the following years, except in those who suffered recurrence of instability. We should highlight that patients with recurrent patellofemoral instability, in general, are not dedicated to high-level sports practice due to the limitation caused by the disease, therefore the operations returned these patients to their activity prior to the dislocations, but without instability, in most cases. The objective here is to describe, in a longer follow-up time, the occurrence of important failures such as recurrence of dislocation. The need for long-term follow-up is evident due to the occurrence of relapses occurring later.

Another limitation of the present study is that it does not evaluate the evolution of patellofemoral joint degeneration. Long-term studies are needed to verify the occurrence of osteoarthritis in these patients, defining the risk of each corrective procedure and each uncorrected anatomical alteration evolving to degeneration.

## Conclusion

Reconstruction of the MPFL with the medial third of the patellar tendon, associated or not with ATT medialization osteotomy, is an alternative in the treatment of acute or chronic patellar instability, with a failure rate of only 18% in at least 5 years of follow-up. In addition, it is a safe treatment, which does not present other complications.

### Financial Support

There was no financial support from public, commercial, or non-profit sources.

### Conflict of Interests

The authors have no conflict of interests to declare.

## References

- 1 Stefancin JJ, Parker RD. First-time traumatic patellar dislocation: a systematic review. *Clin Orthop Relat Res* 2007;455(455):93–101
- 2 Camanho GL, Viegas AdeC, Bitar AC, Demange MK, Hernandez AJ. Conservative versus surgical treatment for repair of the medial patellofemoral ligament in acute dislocations of the patella. *Arthroscopy* 2009;25(06):620–625
- 3 Bitar AC, Demange MK, D'Elia CO, Camanho GL. Traumatic patellar dislocation: nonoperative treatment compared with MPFL reconstruction using patellar tendon. *Am J Sports Med* 2012;40(01):114–122
- 4 Sillanpää PJ, Mattila VM, Mäenpää H, Kiuru M, Visuri T, Pihlajamäki H. Treatment with and without initial stabilizing surgery for primary traumatic patellar dislocation. A prospective randomized study. *J Bone Joint Surg Am* 2009;91(02):263–273
- 5 Pagliuzzi G, Napoli F, Previtali D, Filardo G, Zaffagnini S, Candrian C. A Meta-analysis of Surgical Versus Nonsurgical Treatment of Primary Patella Dislocation. *Arthroscopy* 2019;35(08):2469–2481
- 6 Arendt EA, Dejour D. Patella instability: building bridges across the ocean a historic review. *Knee Surg Sports Traumatol Arthrosc* 2013;21(02):279–293
- 7 GL Camanho, Viegas AC. Anatomical and arthroscopic study of the medial patellofemoral ligament. *Acta Ortop Bras* 2003;11(03):145–149
- 8 Camanho GL, Bitar AC, Hernandez AJ, Olivi R. Medial patellofemoral ligament reconstruction: a novel technique using the patellar ligament. *Arthroscopy* 2007;23(01):108.e1–108.e4
- 9 Bitar AC, D'Elia CO, Demange MK, Viegas AC, Camanho GL. Randomized prospective study on traumatic patellar dislocation: conservative treatment versus reconstruction of the medial patellofemoral ligament using the patellar tendon, with a minimum of two years of follow-up. *Rev Bras Ortop* 2015;46(06):675–683
- 10 Dejour H, Walch G, Nine-Josserand L, Guier C. Factors of patellar instability: an anatomic radiographic study. *Knee Surg Sports Traumatol Arthrosc* 1994;2(01):19–26
- 11 Gobbi RG, Demange MK, de Ávila LFR, et al. Patellar tracking after isolated medial patellofemoral ligament reconstruction: dynamic evaluation using computed tomography. *Knee Surg Sports Traumatol Arthrosc* 2017;25(10):3197–3205
- 12 Gobbi RG, Hinckel BB, Teixeira PRL, et al. The Vastus Medialis Insertion Is More Proximal and Medial in Patients With Patellar Instability: A Magnetic Resonance Imaging Case-Control Study. *Orthop J Sports Med* 2019;7(12):2325967119880846
- 13 Hinckel BB, Gobbi RG, Kihara Filho EN, et al. Why are bone and soft tissue measurements of the TT-TG distance on MRI different in patients with patellar instability? *Knee Surg Sports Traumatol Arthrosc* 2017;25(10):3053–3060
- 14 Hinckel BB, Gobbi RG, Kihara Filho EN, Demange MK, Pécora JR, Camanho GL. Patellar Tendon-Trochlear Groove Angle Measurement: A New Method for Patellofemoral Rotational Analyses. *Orthop J Sports Med* 2015;3(09):2325967115601031
- 15 Hinckel BB, Gobbi RG, Filho EN, et al. Are the osseous and tendinous-cartilaginous tibial tuberosity-trochlear groove distances the same on CT and MRI? *Skeletal Radiol* 2015;44(08):1085–1093
- 16 Trillat AD, Dejour H, Couette A. Diagnostic et traitement des subluxations récidivantes de la rotule. *Rev Chir Orthop Repar Appar Mot* 1964;50:813–824
- 17 Hinckel BB, Gobbi RG, Demange MK, et al. Medial Patellofemoral Ligament, Medial Patellotibial Ligament, and Medial Patellomeniscal Ligament: Anatomic, Histologic, Radiographic, and Biomechanical Study. *Arthroscopy* 2017;33(10):1862–1873
- 18 Gobbi RG, Pereira CA, Sadigursky D, et al. Evaluation of the isometry of different points of the patella and femur for medial patellofemoral ligament reconstruction. *Clin Biomech (Bristol, Avon)* 2016;38(01):8–12
- 19 Gomes JL, Sanhudo JA, Marczyk LR, Guerra M, Essaca PM. Long-term evaluation of patellofemoral instability treated by the Elmslie-Trillat technique. *Rev Bras Ortop* 1996;31(07):595–599
- 20 Mäenpää H, Lehto MU. Patellar dislocation. The long-term results of nonoperative management in 100 patients. *Am J Sports Med* 1997;25(02):213–217
- 21 Vavalle G, Capozzi M. Isolated reconstruction of the medial patellofemoral ligament with autologous quadriceps tendon. *J Orthop Traumatol* 2016;17(02):155–162
- 22 Slenker NR, Tucker BS, Pepe MD, Marchetto PA, Cohen SB. Short-/intermediate-term outcomes after medial patellofemoral ligament reconstruction in the treatment of chronic lateral patellofemoral instability. *Phys Sportsmed* 2013;41(02):26–33
- 23 Lee DY, Park YJ, Song SY, Hwang SC, Park JS, Kang DG. Which Technique Is Better for Treating Patellar Dislocation? A Systematic Review and Meta-analysis. *Arthroscopy* 2018;34(11):3082–3093. e1
- 24 Kujala UM, Jaakkola LH, Koskinen SK, Taimela S, Hurme M, Nelimarkka O. Scoring of patellofemoral disorders. *Arthroscopy* 1993;9(02):159–163
- 25 Buckens CF, Saris DB. Reconstruction of the medial patellofemoral ligament for treatment of patellofemoral instability: a systematic review. *Am J Sports Med* 2010;38(01):181–188