



## Bilateral optic disc pits in a pediatric patient with Cobb syndrome

Bethlehem Mekonnen<sup>a</sup>, Quintin Richardson<sup>a</sup>, Jonah M. Bhisitkul<sup>a</sup>, Mohammad Diab<sup>b</sup>, Nailyn Rasool<sup>a,\*</sup>

<sup>a</sup> Department of Ophthalmology, University of California San Francisco, San Francisco, CA, USA

<sup>b</sup> Department of Orthopedic Surgery, University of California San Francisco, San Francisco, CA, USA

### ARTICLE INFO

#### Keywords:

Optic disc pit  
Cobb syndrome  
Spectral-domain optical coherence tomography  
Arteriovenous malformation  
Congenital optic disc anomaly  
Cavitary disc anomaly  
Scoliosis

### ABSTRACT

**Purpose:** To describe a patient with Cobb Syndrome, a rare congenital disorder characterized by cutaneous and spinal arteriovenous malformations, who was found to have bilateral optic nerve pits.

**Observations:** A 15-year-old boy diagnosed with Cobb Syndrome, manifesting as a large cutaneous port-wine stain associated with an underlying left paraspinous arteriovenous malformation resulting in severe scoliosis, presented for a screening ophthalmological exam. The patient had no visual symptoms. On examination, his visual acuity was 20/20 in each eye; however, bilateral optic disc pits were discovered on biomicroscopy and confirmed by spectral-domain optical coherence tomography.

**Conclusion and importance:** The unusual finding of bilateral optic disc pits in this rare congenital neurocutaneous disorder represents the first report of ophthalmic abnormalities in association with Cobb syndrome. Patients with Cobb Syndrome may be considered for screening ophthalmological exam for the detection of subclinical optic nerve abnormalities.

### 1. Introduction

Cobb syndrome, or cutaneomeningospinal angiomatosis, is a rare congenital condition characterized by cutaneous vascular lesions associated with dermatomal spinal arteriovenous malformations (AVMs) or other vascular anomalies.<sup>1</sup> Although not thought to be an inherited neurocutaneous condition, the prevalence, pathophysiology, genetics, diagnostic criteria, management and prognosis of the disease remain poorly described.<sup>2</sup> Patients can present at any age, but typically present in late childhood, with three reported cases in infancy.<sup>3,7,21,22</sup> The vascular cutaneous lesions, which can be segmental in distribution, typically take the form of port-wine angiomas (nevus flammeus), and are brought to medical attention due to cosmetic concerns or due to acute bleeding with trauma.<sup>1,4,5</sup> Of greater concern is that the underlying paraspinous AVMs may result in hemiparesis or quadraparesis due to ischemia, hemorrhage, spinal cord compression or vascular steal syndrome.<sup>1,4,6</sup> The vascular malformations can also result in spinal deformities resulting in scoliosis and growth impairment. Treatment of Cobb syndrome can involve embolization, neurosurgical intervention, radiotherapy, or medical and supportive treatments to address the neurologic sequelae.<sup>4</sup>

Given the segmental cutaneous vascular anomalies associated with CNS vascular anomalies, Cobb syndrome is considered to be among

various segmental vascular neurocutaneous phacomatoses such as Sturge-Weber syndrome, PHACE syndrome, and craniofacial metamerism syndrome.<sup>5–8</sup> The shared pathogenesis of these conditions is thought to be a somatic mutation early in development either in the neural crest or mesoderm before migration, resulting in multiple arterio-venolymphatic malformations of parts or all tissues of the same somatomeic distribution.<sup>9–11</sup> The spinal vascular anomalies associated with Cobb syndrome tend to be high-flow AVMs. The cutaneous and soft tissue vascular lesions, on the other hand, are often secondary to low-flow vascular tumors such as angiomas.<sup>12</sup>

Optic disc pits (ODPs) are oval, white or gray depressions of the optic disc and in broad terms are a cavitary anomaly of the optic nerve.<sup>13</sup> Optic pits are relatively rare with an incidence of 1 in 11,000 and are unilateral in about 85% of cases. The pathogenesis of optic pits is not well understood. Some have thought that they are a form fruste of optic nerve colobomas. Others point to impaired differentiation of the peripapillary sclera from the primary mesenchyme.<sup>14</sup> Although the exact genetic basis of optic nerve pits has not yet been established, PAX2 and PAX6 genes are expressed in the developing optic nerve. Mutations in these genes are associated with a number of congenital optic disc anomalies.<sup>15</sup> Unlike optic nerve colobomas, ODPs are not known to be associated with other systemic or central nervous system malformations, though rare exceptions exist.<sup>13,16</sup> Serous macular

\* Corresponding author. Department of Ophthalmology, University of California San Francisco, 10 Koret Way, San Francisco, CA, 94143, USA.

E-mail address: [nailyn.rasool@ucsf.edu](mailto:nailyn.rasool@ucsf.edu) (N. Rasool).

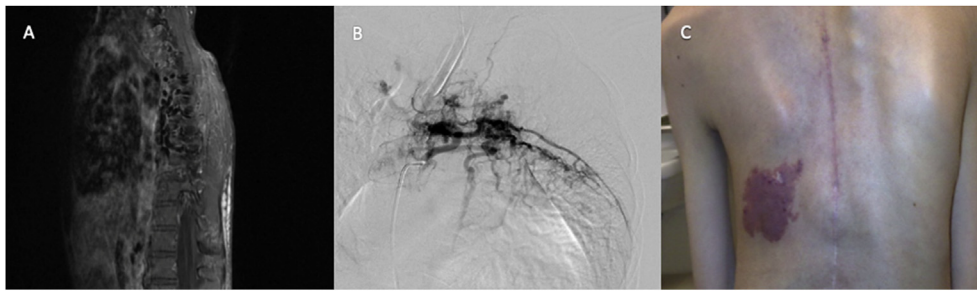
<https://doi.org/10.1016/j.ajoc.2020.100749>

Received 3 January 2020; Received in revised form 10 May 2020; Accepted 14 May 2020

Available online 18 May 2020

2451-9936/© 2020 Published by Elsevier Inc. This is an open access article under the CC BY-NC-ND license

(<http://creativecommons.org/licenses/by-nc-nd/4.0/>).



**Fig. 1.** Vascular lesions in Cobb syndrome. (A) T1-weighted magnetic resonance imaging of the spine demonstrating the flow voids of an arteriovenous malformation (AVM) in the left paraspinous soft tissue from T5-T9. (B) Conventional angiography of the AVM at T5. (C) The left posterior thoracic area shows a large “port-wine stain” cutaneous vascular malformation (the adjacent vertical midline scar is from previous spinal surgery).

detachments develop in 25–75% of eyes with optic pits, typically in the third and fourth decade of life, which can lead to loss of vision.<sup>13</sup>

In our review of the literature, there are no reports associating Cobb syndrome to any ocular findings.

### 1.1. Case Report

A 15-year-old boy was seen in the eye clinic for baseline screening and evaluation recommended while on treatment with Trametinib, a MEK inhibitor, which has been associated with ophthalmic side effects including central serous retinopathy, retinal pigment epithelial detachment, and uveitis.<sup>17</sup> The patient was diagnosed with Cobb syndrome at age 7 having a large, violaceous cutaneous lesion involving the left mid-back area, along with extensive metameric arteriovenous malformations of the thoracic spine (Fig. 1). He initially presented for medical attention at age 7 with back pain attributed to an acute episode of intra-lesional bleeding of the spinal AVM associated with consumptive coagulopathy, an unusual feature in Cobb syndrome. Spinal MRI revealed a large segmental soft tissue AVM from T5-T9 (Fig. 1). Percutaneous embolization was performed a year after diagnosis to decrease venous hypertension in order to prevent neurologic compromise.

The patient presented with severe thoracic scoliosis (> 70°) in the first decade of life, with significant growth remaining. The paraspinous AVMs precluded anterior vertebral tethering. He was managed with posterior growing rods, including index implantation and periodic lengthening, over 7 years until maturity. His course since diagnosis was complicated by chylothorax requiring independent medical and surgical treatment, as well as spontaneous myelopathy of indeterminate cause which was managed with support with residua of left lower limb paresis and spasticity. Once sufficiently mature, he was placed in traction due to the severity of the scoliosis, following which he underwent definitive posterior spinal instrumentation and fusion.

His medical history is otherwise notable for asthma and failure to thrive due to poor caloric intake, requiring a gastrostomy-tube placement to supplement his oral intake. Medical care has included Trametinib, a MEK-inhibitor, following biopsy results taken from his cutaneous lesion that showed activating KRAS mutation. Such somatic mutation has previously been described in brain AVMs with response to MEK-inhibitory therapy.<sup>18</sup>

On general examination, the patient appeared thin but well nourished. He was alert and cooperative. He displayed severe kyphoscoliosis and used a wheelchair for long distances.

On ophthalmic examination, visual acuity was 20/20 in each eye. The pupils were normal with no relative afferent pupillary defect. Visual fields were full to confrontational testing. He had normal ocular alignment and motility, without nystagmus. Intraocular pressure was normal in each eye, and he had a normal anterior segment exam. Dilated fundus exam revealed a gray optic pit lesion of the left optic disc (Fig. 2D), while the right optic disc appeared normal (Fig. 2A). Peripapillary pigment rings at the temporal edge of both optic nerve heads were appreciated, a finding commonly noted with optic nerve pits.<sup>13</sup> Otherwise there was no optic nerve pallor or hypoplasia. The macula

was normal in each eye, as were the vasculature and peripheral retina.

On SD-OCT (Spectralis, Heidelberg Engineering) optic disc pits were evident in both eyes, although more prominent in the left eye, with deeply excavated disc contours together with hyporeflective cavities and thin irregular septate partitions within the substance of the nerve head (Fig. 2C and D). The peripapillary retina demonstrated limited herniation into the pits without notable irregularity or schisis. The macular OCT was normal in each eye with good foveal contours and no serous subretinal fluid. No treatment was indicated, and an annual ophthalmologic exam was recommended.

## 2. Discussion

The confluence in this patient of a rare ophthalmologic finding – bilateral optic disc pits – with an even rarer congenital syndrome suggests that there could be a unifying disease process, and that ODP may be the first ocular finding to be added to the list of neurologic associations in Cobb syndrome. Although there is limited knowledge of the embryologic pathogenesis of Cobb syndrome, it is thought to originate from an error in neural crest migration that gives rise to arterial metameric vascular lesions.<sup>9</sup> Other segmental neurocutaneous syndromes have been associated with optic nerve anomalies. Optic nerve hypoplasia in patients with PHACE syndrome is well recognized,<sup>19</sup> and colobomatous optic nerve defects have been reported in Sturge-Weber syndrome.<sup>20</sup> Such associations of optic nerve abnormalities with phacomatoses demonstrates that there may be a common pathogenesis during development that unifies the vascular system and optic nerve development. Against this, however, the patient's bilateral optic disc abnormalities are difficult to reconcile with the lateralized anomalies typically seen in Cobb syndrome, although the patient's optic disc anomaly was more prominent ipsilateral to his spinal vascular lesion.

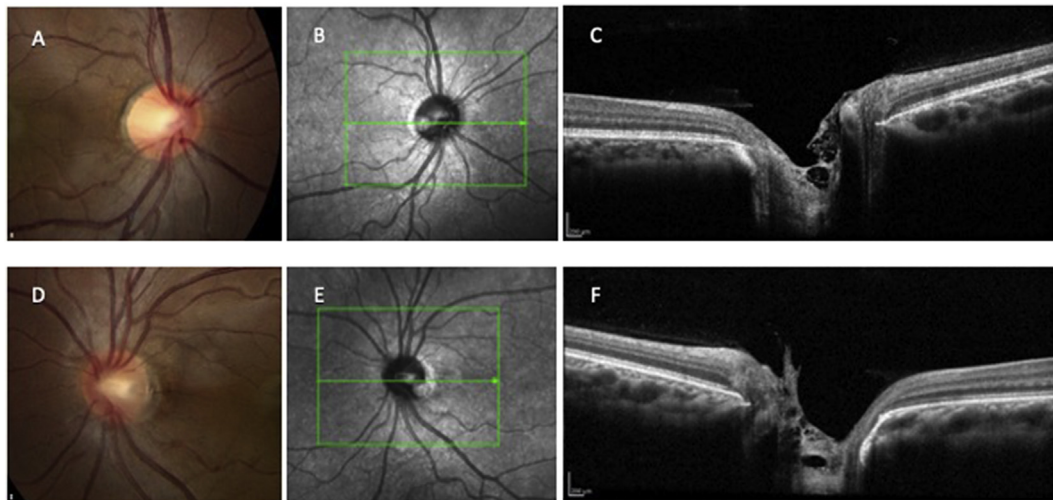
The confirmation of ODP as another neurologic manifestation of Cobb syndrome will require support with additional patient cases. Since ODPs are often asymptomatic, particularly at the young age at which Cobb syndrome is typically diagnosed, it would be useful to routinely screen these patients annually with a complete ophthalmologic examination, including optic nerve OCT and, if possible, a baseline formal visual field. Early detection of visually asymptomatic optic pits has clinical relevance, as patient education and ongoing ophthalmologic monitoring can allow prompt recognition and treatment of the onset of serous maculopathy, the main sight-threatening complication of optic disc pits.

### Patient consent

Written informed consent was obtained for this study.

### Funding

No funding or grant support



**Fig. 2.** Optic disc pits in Cobb syndrome. Disc photos show the greyish pit at the temporal edge of the left optic nerve head (D). Near-infrared scanning laser images indicate the optic pits in each eye as bright lesions on the temporal disc (B, E). SD-OCT shows the optic pit in each eye (C, F) with disc excavation and hyporeflective cavities.

### Authorship

All authors attest that they meet the current ICMJE criteria for Authorship.

### Declaration of competing interest

The following authors have no financial disclosures: BM, QR, JB, MD, NR.

### Acknowledgements

None.

### References

- Pal P, Ray S, Chakraborty S, Dey S, Talukdar A. Cobb syndrome: a rare cause of paraplegia. *Ann Neurosci*. 2015;22(3):191–193.
- Papalini PE, Papalini FR. Cervicothoracic cutaneomeningospinal angiomatosis in adults (Cobb's syndrome): a case report of acute quadriplegia. *Surg Neurol Int*. 2017;8:147.
- Niimi Y, Uchiyama N, Elijevich L, Berenstein A. Spinal arteriovenous metamerism syndrome: clinical manifestations and endovascular management. *AJNR Am J Neuroradiol*. 2013;34(2):457–463.
- Clark MT, Brooks EL, Chong W, Pappas C, Fahey M. Cobb syndrome: a case report and systematic review of the literature. *Pediatr Neurol*. 2008;39(6):423–425.
- Maramattom BV, Cohen-Gadol AA, Wijidicks EF, Kallmes D. Segmental cutaneous hemangioma and spinal arteriovenous malformation (Cobb syndrome). Case report and historical perspective. *J Neurosurg Spine*. 2005;3(3):249–252.
- Abdel Razek AA. Vascular neurocutaneous disorders: neurospinal and craniofacial imaging findings. *Jpn J Radiol*. 2014;32(9):519–528.
- Jagla M, Szymonska I, Kruczek P. Sonographic findings in a neonate with Cobb syndrome. *J Clin Ultrasound*. 2013;41(4):258–260.
- Mercer RD, Rothner AD, Cook SA, Alfidi RJ. The Cobb syndrome: association with hereditary cutaneous hemangiomas. *Cleve Clin Q*. 1978;45(2):237–240.
- Krings T, Geibprasert S, Luo CB, Bhattacharya JJ, Alvarez H, Lasjaunias P. Segmental neurovascular syndromes in children. *Neuroimaging Clin*. 2007;17(2):245–258.
- Choi IS. Spinal arteriovenous metamerism syndrome: angioarchitecture and their prognosis. *AJNR Am J Neuroradiol*. 2013;34(2):464–465.
- Shim JH, Lee DW, Cho BK. A case of Cobb syndrome associated with lymphangioma circumscriptum. *Dermatology*. 1996;193(1):45–47.
- Johnson WD, Petrie MM. Variety of spinal vascular pathology seen in adult Cobb syndrome. *J Neurosurg Spine*. 2009;10(5):430–435.
- Brodsky MC. Congenital optic disk anomalies. *Surv Ophthalmol*. 1994;39(2):89–112.
- Ohno-Matsui K, Hirakata A, Inoue M, Akiba M, Ishibashi T. Evaluation of congenital optic disc pits and optic disc colobomas by swept-source optical coherence tomography. *Invest Ophthalmol Vis Sci*. 2013;54(12):7769–7778.
- Azuma N, Yamaguchi Y, Handa H, et al. Mutations of the PAX6 gene detected in patients with a variety of optic-nerve malformations. *Am J Hum Genet*. 2003;72(6):1565–1570.
- Golnik KC. Cavitory anomalies of the optic disc: neurologic significance. *Curr Neurol Neurosci Rep*. 2008;8(5):409–413.
- Duncan KE, Chang LY, Patronas M. MEK inhibitors: a new class of chemotherapeutic agents with ocular toxicity. *Eye*. 2015;29(8):1003–1012.
- Nikolaev SI, Fish JE, Radovanovic I. Somatic activating KRAS mutations in arteriovenous malformations of the brain. *N Engl J Med*. 2018;378(16):1561–1562.
- Frieden IJ, Reese V, Cohen D. PHACE syndrome. The association of posterior fossa brain malformations, hemangiomas, arterial anomalies, coarctation of the aorta and cardiac defects, and eye abnormalities. *Arch Dermatol*. 1996;132(3):307–311.
- Sinawat S, Auvichayapat N, Auvichayapat P, Yospaiboon Y, Sinawat S. 12-year retrospective study of Sturge-Weber syndrome and literature review. *J Med Assoc Thai*. 2014;97(7):742–750.
- Soeda A, Sakai N, Iihara K, Nagata I. Cobb syndrome in an infant: treatment with endovascular embolization and corticosteroid therapy: case report. *Neurosurgery*. 2003;52:711–715.
- Brant AJ, James HE, Tung H. Cutaneomeningospinal angiomatosis (Cobb syndrome) with tethered cord. *Pediatr Neurosurg*. 1999;30:93.