



Role of Endoscopic Vacuum Therapy as a Treatment for Anastomosis Leak after Esophageal Cancer Surgery

Dong Kyu Lee, M.D., Yang Won Min, M.D., Ph.D.

Department of Medicine, Samsung Medical Center, Sungkyunkwan University School of Medicine, Seoul, Korea

ARTICLE INFO

Received May 13, 2020

Revised May 21, 2020

Accepted July 3, 2020

Corresponding author

Yang Won Min

Tel 82-2-3410-3409

Fax 82-2-3410-6983

E-mail yangwonee@gmail.com

ORCID

https://orcid.org/0000-0001-7471-1305

[†]This article was presented at the 6th Esophageal Cancer Symposium (lecture on November 16th, 2019, Samsung Medical Center, Seoul, Korea).

Esophageal anastomotic leak is the most common and serious complication following esophagectomy. However, the standard treatment for anastomotic leaks remains unclear. Recently, endoscopic vacuum therapy has become an important non-surgical alternative treatment method for patients with esophageal anastomotic leak. This treatment involves the endoscopic placement of a sponge connected to a nasogastric tube into the defect cavity or lumen. Subsequently, continuous negative pressure is delivered to the cavity through the tube. Several studies have reported a treatment success rate of 80% to 100%. In this study, we review the mechanism of action, the method of performing the procedure, its safety and efficacy, and prognostic factors for failure of endoscopic vacuum therapy in the management of patients with anastomotic leak, and on this basis attempted to confirm the possibility of establishing a standardized treatment protocol using endoscopic vacuum therapy.

Keywords: Anastomotic leak, Negative-pressure wound therapy, Esophagectomy, Endoscopy, Vacuum

Introduction

Esophagectomy with a small bowel anastomosis has been used to treat many esophageal diseases, including cancer [1]. Various anastomotic complications can occur following esophagectomy, of which esophageal anastomotic leak (EAL) is the most common, yet serious complication. The leak rate is 3% to 25% [2-6]. Nonetheless, the optimal treatment for EAL remains unclear.

In patients who are stable enough for nonsurgical therapy (Clavien-Dindo classification III/ IV) [7], the placement of fully or partially covered self-expanding metal stents (SEMS) has become the standard endoscopic therapy for anastomotic leakage in recent years. In dedicated series, the placement of SEMS achieved clinical success rates (healing of anastomosis) of 80% to 85% [8-11]. However, coverage of the defect through SEMS insertion is sometimes difficult. In addition, SEMS treatment poses the potential risks of increasing the defect size and stent migration [1].

Endoscopic vacuum therapy (EVT), also known as E-Vac

therapy, EndoVac therapy, and endoscopic negative-pressure therapy, is an innovative endoscopic treatment for treating anastomotic leakage [12]. The first experience of applying EVT in the esophagus was published as a case report in 2008 [13]. In 2 patients, EAL was successfully treated by EVT. Subsequently, EVT has been increasingly often used for intrathoracic leakage, especially in cases of post-operative anastomotic leakage, and several studies have reported a treatment success rate of 80% to 100% (Fig. 1). In addition, EVT was found to be more effective for esophageal leaks than SEMS in limited cohorts [1,8,14]. However, insufficient prospective and large-scale retrospective studies have been conducted for EVT to be considered the standard treatment.

In this article, we analyzed the mechanism of action, the method of performing the procedure, its safety and efficacy, and prognostic factors of EVT in the management of patients with EAL and attempted to confirm the possibility of establishing a standardized treatment using EVT.



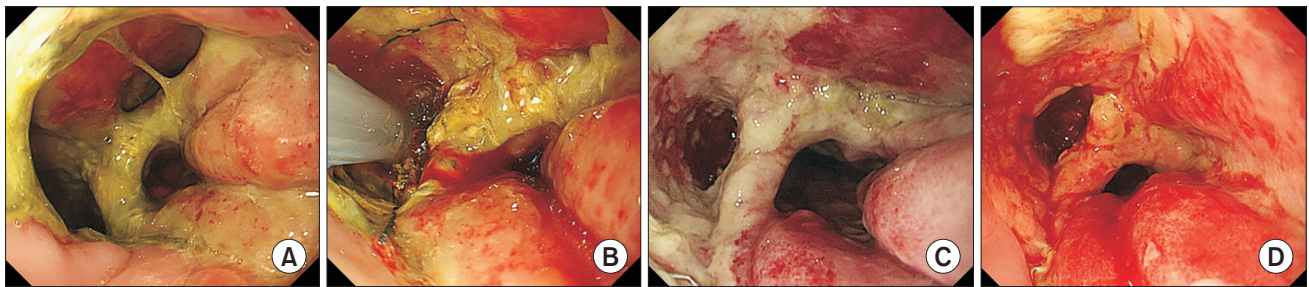


Fig. 1. A male patient was diagnosed with a postoperative anastomotic leak 8 days after an Ivor-Lewis operation for esophageal cancer. (A) Two large openings of the leak were noticed at the anastomosis. (B) A polyurethane sponge sutured to the tip of a nasogastric tube was inserted into the larger leak. (C) The cavity size decreased after 5 days of EVT. (D) The cavity size decreased further, with granulation tissue formation, and the fistula closed after 9 days of EVT. The patient did not require additional EVT. EVT, endoscopic vacuum therapy.

Procedure of endoscopic vacuum therapy

Mechanisms and effect

Several mechanisms are involved in the healing effect of EVT, including changes in perfusion, macrodeformation, microdeformation, exudate control, and bacterial control [15].

Macrodeformation and microdeformation

Macrodeformation occurs when suction is applied to the sponge, which results in deformational forces being exerted on the defect edges, drawing the edges together [15-17]. In addition, the continuous negative pressure delivered by EVT counteracts the spillover of esophageal and gastric contents by means of respiration and negative intrathoracic pressure, leading to the collapse of the leakage cavity [14,18]. Microdeformation refers to the mechanical changes that occur on a microscopic scale when suction is applied [16]. The mechanical strain causes a deformation of the cytoskeleton, which initiates signaling cascades leading to the release of growth factors that promote cell proliferation and migration, increasing the expression of extracellular matrix components and contractile elements that are necessary for healing [15,16].

Changes in perfusion

EVT treatment results in increased micro-vessel density. EVT also causes temporary hypoperfusion in the defect edges, resulting in localized expression of hypoxia-inducible factor 1 α with concomitant modulation of vascular endothelial growth factor expression, leading to an increase in angiogenesis [16,19-21]. Studies have showed that a negative pressure of 125 mm Hg significantly increased

the blood vessel density, which reached a maximum of 200% in comparison to the vessel density prior to treatment [22].

Exudate control

Wound healing has been observed to improve following fluid removal. Although the exact mechanism behind this improvement in healing is unclear, proposed theories include local alterations in the blood flow and elimination of harmful substances [19]. Moreover, the forces of compression acting on the microvasculature are reduced due to the removal of fluid, thereby resulting in increased blood flow and perfusion of the tissue [15,16].

Bacterial clearance

A high bacterial load may disturb the process of defect healing; however, the evidence regarding the role of EVT in decreasing bacterial contamination is controversial [16,19]. A randomized study reported that EVT had a positive effect on wound healing due to a significant decrease in the bacterial load compared with non-vacuum-treated wounds [16,23]. However, other studies have also shown either an increase or no change in the bacterial load using EVT [24,25].

Advantages of the procedure

According to Schorsch et al. [12], EVT enables efficient closure and drainage of esophageal defects. The luminal sub-atmospheric pressure communicated through the open-pore polyurethane sponge seals the defect and drains the extra-luminal septic focus [12]. It counteracts the physiological negative thoracic pressure, thereby preventing further contamination and mediastinitis [12,14]. Thus, in principle, it can be used for wounds that have been detect-

ed early and for clean wounds to prevent contamination and extra-luminal inflammation. Additionally, it is applicable at advanced stages of esophageal leakage. Moreover, vacuum drainage placement is practicable along the entire length of the esophagus. Using an appropriate variant, a broad range of possible defect sizes and para-esophageal wound cavities can be adequately treated [12].

Brangewitz et al. [14] reported the benefits of EVT in comparison to stent insertion therapy. First, SEMs placement ideally requires fluoroscopy; therefore, transfer of the patient to the endoscopy or radiology room may be necessary, which can be difficult to accomplish with these patients, who are often critically ill [14]. In contrast, EVT can be performed in the intensive care unit. Second, no guidelines exist concerning the duration of treatment with SEMs [14]. As the stent mesh interferes with inspection of the wound cavity, it is difficult to define the optimal time for stent removal. Furthermore, the radial force of SEMs could restrict the approximation of wound margins, thereby impairing healing [14]. In contrast, EVT allows for regular inspection and tension-free healing of the leak. Another notable problem is the development of strictures after stent removal. In comparison with patients who underwent SEMs treatment, a statistically significantly lower stricture rate was observed in those treated with EVT. The rigid oral opening of the stents can cause circular esophageal ulcerations, which might explain the high stricture rate in the stent cohort [14]. Subsequently, anastomotic stricture can sometimes also develop during EVT in addition to the healing of the leak. At that time, subsequent stent insertion would be beneficial.

Method of endoscopic vacuum therapy

(1) The cavity is evaluated to choose the correct sponge size, which can be estimated based on the size and shape of the leakage cavity. After these steps, the endoscope is removed, and the sponge system is prepared [16,26,27].

(2) A nasogastric tube (NGT) is inserted through the nose and brought out through the mouth. The distal part of the tube with side holes should be removed [1].

(3) The sponge is cut to the appropriate size and positioned at the tip of the NGT, after which the sponge is secured using either silk ties or permanent sutures [16,26,27].

(4) The custom sponge made using a polyurethane foam is cut to size based on the size of the defect. The sponge should be smaller than the wound cavity to promote the collapse and subsequent closure of the fistula [1].

(5) After grasping the distal tube using forceps or a

snare, the sponge is delivered to the anastomosis. Due to the size of the system and the endoscope, introduction into the upper esophageal sphincter can be difficult, and careful attention should be paid to avoid trauma during insertion [26,27]. For ease of grasping, a short suture loop should be made at the distal part of the tube.

(6) The sponge can be inserted in the wound cavity using endoscopic forceps or by pushing via manipulation of the distal tip of the endoscope [1].

(7) After tube placement, a continuous negative pressure of 100 mm Hg generated by a vacuum pump is delivered to the cavity through the tube. The sponge must be changed every 4–7 days according to the changes in the size and shape of the lesion. EVT is completed when the opening closes completely or the leakage cavity is well sealed off [1].

Efficacy of endoscopic vacuum therapy

Several previous studies have shown high success rates with EVT in EAL. Min et al. [1] analyzed 20 patients treated with EVT who had EAL following esophagectomy for cancer. In their study, the median duration of EVT treatment was 14.5 days and a median of 5 interventions were performed in each patient. The median admission duration was 49 days. During the median follow-up of 213.5 days, 19 patients (95.0%) were successfully treated, and 1 patient (5.0%) who could not be treated with EVT died [1]. Schorsch et al. [12], reported success in 32 of 35 (91.4%) cases for all-cause esophageal defects and 20 of 21 (95.2%) successful cases for post-esophagectomy or gastrectomy anastomotic leak [12]. Laukoetter et al. [28] reported success in 49 of 52 (94.2%) cases of EVT treatment for all-cause esophageal defects and in 36 of 39 (92.3%) cases of post-esophagectomy or gastrectomy anastomotic leak [28]. Furthermore, Bludau et al. [13] analyzed 14 patients who had esophageal defects treated with E-Vac. Notably, 2 patients had spontaneous defects, 4 patients had iatrogenic defects, and 8 patients had postoperative esophageal defects [13]. Complete closure of the esophageal defect was achieved in 12 (86%) of the 14 patients. Seven of the 8 EAL patients (87.5%) patients were treated with EVT [13].

EVT treatment had significantly higher success rates than SEMs for postoperative anastomotic leaks in several previous studies [1,8,14,29]. In a German retrospective study, the outcomes of patients who were treated with a stent or EVT for intrathoracic leak were compared. The overall closure rate was significantly higher in the EVT group than in the SEMs group. EVT was successful in 27 of 32 patients (84.4%). In addition, fewer strictures devel-

oped in the EVT group than in the SEMS group. EVT is an effective endoscopic treatment option for intrathoracic leaks and showed higher effectiveness than SEMS placement in this cohort [14].

Recently, a German retrospective study analyzed 45 patients with anastomotic leaks following esophagectomy who received either SEMS or EVT. Notably, 30 patients received SEMS placement and 15 underwent EVT. Seven patients in the SEMS group were switched to EVT and 4 to surgery. According to the initial therapy, the success rate was higher in the EVT group than in the SEMS group (EVT, 93.3%; SEMS, 63.3%; $p=0.038$). When classified by final therapy, the success rate was also higher in the EVT group than in the SEMS group, but with marginal statistical significance (EVT, 86.4%; SEMS, 60.9%; $p=0.091$). No significant difference was observed in length of hospital stay, duration of therapy, and mortality between the study groups [8]. Therefore, EVT was more effective than SEMS for treating intrathoracic anastomotic leaks in that study. In a comparative study involving 62 patients who developed an anastomotic leak following esophagectomy, EVT showed better outcomes than stent placement and surgery [1,30].

Although the effects of EVT have not been evaluated by a randomized controlled study, the above studies suggest that the clinical outcomes of patients who receive EVT for anastomotic leaks may be good.

Safety of endoscopic vacuum therapy

In general, EVT is a safe procedure with a low rate of adverse events. The most frequent side effects are sponge dislocation, minor bleeding after sponge exchange due to ingrowth of granulation tissue into the sponge, and anastomotic strictures [13].

A prospective study involving 52 patients with upper gastrointestinal defects treated with EVT reported a 4.1% rate of minor adverse events, including sponge dislocation and minor bleeding after sponge removal [16]. The sponge dislocation occurred when the leakage was already small and EVT was performed intra-luminally due to swallowing and coughing. Minor bleeding was usually self-limited and more frequent sponge exchanges could potentially mitigate this risk [16,28].

Min et al. [1] reported that 7 patients (35.0%) developed anastomotic stenosis following EVT. In all stricture cases, the patients had dysphagia and the diagnoses were made through endoscopy or esophagography. All the strictures were relieved with several sessions of balloon dilation [1].

Notably, several studies also reported post-interventional strictures. The stricture rates after EVT treatment were as follows: Laukoetter et al. [28] reported a rate of 7.7% (4 of 52 cases), Brangewitz et al. [14] reported a rate of 9.4% (3 of 32 cases), and Schorsch et al. [12] reported a rate of 4.2% (1 of 24 cases).

A major concern for EVT in the esophagus is the risk of major bleeding, due to the risk of fistula development between the cavity and the aorta (or aortic branches), as well as the possibility of formation and rupture of a pseudoaneurysm involving the vessels or heart chambers due to the ongoing inflammatory process of EVT [31]. Laukoetter et al. [28] reported that 2 patients died due to major bleeding related to EVT. These patients suffered from a late anastomotic insufficiency after distal esophagectomy, and died due to fatal hemorrhage during EVT [28]. One patient died of acute hemorrhage, and cardiac infarction was found to be the cause of death; however, the autopsy also found that the treated insufficiency cavity was in close proximity to a pseudoaneurysm of the right atrium. The other patient died due to a fulminant and non-manageable hemorrhage during the third scheduled endoscopic change of the sponge in the endoscopy unit [28]. In that case, the authors believed that a descending aortic rupture occurred.

In a case series including 5 patients who were successfully treated with EVT, 2 anastomotic strictures were reported. In both cases, dilation with bougies were performed. One of these patients had 2 dilations without adverse events. The other patient experienced severe bleeding after dilation and eventually died, with cause of death on autopsy being identified as an aorto-esophageal fistula leading to hemorrhagic shock [16,32]. On the basis of these major bleeding reports, if massive bleeding occurs during treatment, EVT should be stopped and computed tomography angiography must be performed to direct possible management.

Prognostic factors of endoscopic vacuum therapy

Prognostic factors for the failure of SEMS treatment have been reported in several previous studies. In Sweden, a randomized controlled trial reported that the detection of esophagotracheal fistula, the time interval between diagnosis of esophageal defect and positioning of the stent, distal esophageal defects (i.e., a defect straddling the gastro-esophageal junction), and cardiovascular comorbidities were prognostic factors for SEMS treatment failure [2]. However, scant studies have addressed predictive factors of

EVT failure in patients with EAL.

Brangewitz et al. [14] performed a multivariate analysis of clinical factors affecting the closure of esophageal intrathoracic leakages treated by EVT or stent insertion. Early timing of therapy, the presence of underlying malignant disease, and EVT were associated with the closure of esophageal intrathoracic leaks. Min et al. [1] investigated the factors associated with treatment failure and treatment duration of EVT in 20 esophageal cancer patients who had experienced anastomotic leak after esophagectomy. They reported that neoadjuvant treatment and a large fistula opening were associated with longer EVT treatment. The 20 patients were divided into 2 groups according to the duration of hospitalization (<21 days and ≥21 days of treatment). Twelve patients (60.0%) were treated for <21 days and 8 patients (40.0%) were treated for ≥21 days. The longer EVT treatment group had a larger number of patients who received neoadjuvant treatment (87.5% versus 25.0%, $p=0.02$) and a larger median size of the fistula opening (2.0 cm versus 1.0 cm, $p=0.05$) [1].

Conclusion

In conclusion, EVT is a safe and effective treatment procedure for the management of postoperative anastomotic leaks following esophagectomy. However, a longer duration of treatment is required for patients who receive neoadjuvant treatment and have large leakage openings. Development of an EVT kit and procedural standardization could accelerate the use of EVT for patients who may benefit from a standard procedure in the future.

Conflict of interest

No potential conflict of interest relevant to this article was reported.

ORCID

Dong Kyu Lee: <https://orcid.org/0000-0002-2353-3905>

Yang Won Min: <https://orcid.org/0000-0001-7471-1305>

References

1. Min YW, Kim T, Lee H, et al. *Endoscopic vacuum therapy for postoperative esophageal leak*. BMC Surg 2019;19:37.
2. Persson S, Elbe P, Rouvelas I, et al. *Predictors for failure of stent treatment for benign esophageal perforations: a single center 10-year experience*. World J Gastroenterol 2014;20:10613-9.
3. Sarella AI, Tolan DJ, Harris K, Dexter SP, Sue-Ling HM. *Anastomotic leakage after esophagectomy for cancer: a mortality-free experience*. J Am Coll Surg 2008;206:516-23.
4. Turkyilmaz A, Eroglu A, Aydin Y, Tekinbas C, Muharrem Erol M, Karaoglanoglu N. *The management of esophagogastric anastomotic leak after esophagectomy for esophageal carcinoma*. Dis Esophagus 2009;22:119-26.
5. Urschel JD. *Esophagogastrostomy anastomotic leaks complicating esophagectomy: a review*. Am J Surg 1995;169:634-40.
6. Whooley BP, Law S, Alexandrou A, Murthy SC, Wong J. *Critical appraisal of the significance of intrathoracic anastomotic leakage after esophagectomy for cancer*. Am J Surg 2001;181:198-203.
7. Clavien PA, Barkun J, de Oliveira ML, et al. *The Clavien-Dindo classification of surgical complications: five-year experience*. Ann Surg 2009;250:187-96.
8. Mennigen R, Harting C, Lindner K, et al. *Comparison of endoscopic vacuum therapy versus stent for anastomotic leak after esophagectomy*. J Gastrointest Surg 2015;19:1229-35.
9. van Boeckel PG, Sijbring A, Vleggaar FP, Siersema PD. *Systematic review: temporary stent placement for benign rupture or anastomotic leak of the oesophagus*. Aliment Pharmacol Ther 2011;33:1292-301.
10. Tuebergen D, Rijcken E, Mennigen R, Hopkins AM, Senninger N, Bruewer M. *Treatment of thoracic esophageal anastomotic leaks and esophageal perforations with endoluminal stents: efficacy and current limitations*. J Gastrointest Surg 2008;12:1168-76.
11. Dasari BV, Neely D, Kennedy A, et al. *The role of esophageal stents in the management of esophageal anastomotic leaks and benign esophageal perforations*. Ann Surg 2014;259:852-60.
12. Schorsch T, Muller C, Loske G. *Endoscopic vacuum therapy of anastomotic leakage and iatrogenic perforation in the esophagus*. Surg Endosc 2013;27:2040-5.
13. Bludau M, Holscher AH, Herbold T, et al. *Management of upper intestinal leaks using an endoscopic vacuum-assisted closure system (E-VAC)*. Surg Endosc 2014;28:896-901.
14. Brangewitz M, Voigtlander T, Helfritz FA, et al. *Endoscopic closure of esophageal intrathoracic leaks: stent versus endoscopic vacuum-assisted closure, a retrospective analysis*. Endoscopy 2013;45:433-8.
15. Panayi AC, Leavitt T, Orgill DP. *Evidence based review of negative pressure wound therapy*. World J Dermatol 2017;6:1-16.
16. De Moura DT, de Moura BF, Manfredi MA, et al. *Role of endoscopic vacuum therapy in the management of gastrointestinal transmural defects*. World J Gastrointest Endosc 2019;11:329-44.
17. Saxena V, Hwang CW, Huang S, Eichbaum Q, Ingber D, Orgill DP. *Vacuum-assisted closure: microdeformations of wounds and cell proliferation*. Plast Reconstr Surg 2004;114:1086-96.
18. Persson S, Rouvelas I, Irino T, Lundell L. *Outcomes following the main treatment options in patients with a leaking esophagus: a systematic literature review*. Dis Esophagus 2017;30:1-10.

19. Lalezari S, Lee CJ, Borovikova AA, et al. *Deconstructing negative pressure wound therapy*. *Int Wound J* 2017;14:649-57.
20. Erba P, Ogawa R, Ackermann M, et al. *Angiogenesis in wounds treated by microdeformational wound therapy*. *Ann Surg* 2011;253:402-9.
21. Greene AK, Puder M, Roy R, et al. *Microdeformational wound therapy: effects on angiogenesis and matrix metalloproteinases in chronic wounds of 3 debilitated patients*. *Ann Plast Surg* 2006;56:418-22.
22. Malsiner CC, Schmitz M, Horch RE, Keller AK, Leffler M. *Vessel transformation in chronic wounds under topical negative pressure therapy: an immunohistochemical analysis*. *Int Wound J* 2015;12:501-9.
23. Moues CM, Vos MC, van den Bemd GJ, Stijnen T, Hovius SE. *Bacterial load in relation to vacuum-assisted closure wound therapy: a prospective randomized trial*. *Wound Repair Regen* 2004;12:11-7.
24. Braakenburg A, Obdeijn MC, Feitz R, van Rooij IA, van Griethuysen AJ, Klinkenbijnl JH. *The clinical efficacy and cost effectiveness of the vacuum-assisted closure technique in the management of acute and chronic wounds: a randomized controlled trial*. *Plast Reconstr Surg* 2006;118:390-7.
25. Patmo AS, Krijnen P, Tuinebreijer WE, Breederveld RS. *The effect of vacuum-assisted closure on the bacterial load and type of bacteria: a systematic review*. *Adv Wound Care (New Rochelle)* 2014;3:383-9.
26. Loske G, Muller CT. *Tips and tricks for endoscopic negative pressure therapy*. *Chirurg* 2019;90(Suppl 1):7-14.
27. Leeds SG, Mencia M, Ontiveros E, Ward MA. *Endoluminal vacuum therapy: how I do it*. *J Gastrointest Surg* 2019;23:1037-43.
28. Laukoetter MG, Mennigen R, Neumann PA, et al. *Successful closure of defects in the upper gastrointestinal tract by endoscopic vacuum therapy (EVT): a prospective cohort study*. *Surg Endosc* 2017;31:2687-96.
29. Hwang JJ, Jeong YS, Park YS, et al. *Comparison of endoscopic vacuum therapy and endoscopic stent implantation with self-expandable metal stent in treating postsurgical gastroesophageal leakage*. *Medicine (Baltimore)* 2016;95:e3416.
30. Schniewind B, Schafmayer C, Voehrs G, et al. *Endoscopic endoluminal vacuum therapy is superior to other regimens in managing anastomotic leakage after esophagectomy: a comparative retrospective study*. *Surg Endosc* 2013;27:3883-90.
31. Virgilio E, Ceci D, Cavallini M. *Surgical endoscopic vacuum-assisted closure therapy (EVAC) in treating anastomotic leakages after major resective surgery of esophageal and gastric cancer*. *Anticancer Res* 2018;38:5581-7.
32. Ahrens M, Schulte T, Egberts J, et al. *Drainage of esophageal leakage using endoscopic vacuum therapy: a prospective pilot study*. *Endoscopy* 2010;42:693-8.