

CASE REPORT

Incidental cerebral aneurysm after takotsubo cardiomyopathy: A case report

Tânia Amaro¹  | Taynara Sgarbi² | Raísa Vieira³ | Rafael Reis Santos⁴ | Priscila Matos³ | Adilson Oliveira^{5,6} 

¹Cardiology Department, Clínica Girassol, Luanda, Angola

²Universidade de Franca–UNIFRAN, Franca, Brazil

³Faculdade de Medicina da Universidade Estácio de Sá Campos Citta América, Rio de Janeiro, Brazil

⁴Faculdade de Medicina da Universidade Federal do Pará, Belém, Brazil

⁵Centro Neurociência, Clínica Girassol, Luanda, Angola

⁶Centro de Estudos Avançados em Formação e Educação Médica–CEDUMED, –FMUAN, Luanda, Angola

Correspondence

Tânia Amaro, Cardiology Department, Clínica Girassol, Avenida Comandante Gika, 255, Luanda, Angola.

Email: taniamaro22@gmail.com

Abstract

Takotsubo syndrome (TS) is an acute heart disease that mimics the typical features of acute coronary syndrome (ACS). TS is generally reported after subarachnoid hemorrhage (SAH) due to a ruptured aneurysm, and has an incidence rate of 0.8 (17%). Here, we report a rare case of TS with unruptured intracranial aneurysm. A 54-year-old woman had a history of systemic arterial hypertension and migraine. She went to a secondary hospital 2 h after sudden-onset chest pain, which irradiated to the left upper limb and back. The initial electrocardiogram (ECG) was normal but showed a troponin curve, which led us to suspect acute non-ST elevation myocardial infarction. Serial ECG showed dynamic changes in ST-segment elevation in DIII, AvF, V5, and V6. Emergency cardiac catheterisation was performed and did not show any obstructive lesions. However, ventriculography revealed hypokinesia of the inferoapical wall. During hospitalization, the patient had a severe refractory headache. Computed tomography (CT) and CT angiography were performed, which identified “mirror” saccular aneurysms. A supraclinoid internal carotid artery aneurysm was embolized with two stents. The patient’s condition progressed satisfactorily. The association between takotsubo syndrome and aneurysmal SAH with some populations has already been reported. Due to this prior knowledge, and severe headache, it was necessary to perform screening for SAH and the discovery of an unruptured aneurysm in this case report. The present case report differs from most reported cases of takotsubo syndrome described in the literature because it presents unruptured mirror aneurysms, while most cases are diagnosed after intracranial hemorrhage.

KEYWORDS

brain aneurysm, neurogenic stress, stunned neurogenic myocardium, takotsubo syndrome

This is an open access article under the terms of the [Creative Commons Attribution-NonCommercial](https://creativecommons.org/licenses/by-nc/4.0/) License, which permits use, distribution and reproduction in any medium, provided the original work is properly cited and is not used for commercial purposes.

© 2023 The Authors. *Clinical Case Reports* published by John Wiley & Sons Ltd.

1 | INTRODUCTION

Takotsubo syndrome is an acute heart disease that mimics the typical features of acute coronary syndrome (ACS).¹ Although takotsubo syndrome has an uncertain prevalence in the general population, in women with suspected ACS, the prevalence is estimated to be around 5%–6%.² The annual incidence is very low and is approximately 0.02%.^{3,4}

Unlike ACS, TS is reversible and the heart often heals within four to eight changes weeks. The syndrome is characterized by transient systolic and diastolic left ventricular dysfunction with wall motion abnormalities.^{5,6} This condition, which was first described by Dote et al. in Japan in 1990,^{3,4} usually affects postmenopausal women who have experienced some physical or psychological stress. However, it can also occur in the absence of these triggers.^{1,7}

The pathogenesis of this disorder is not well understood. Postulated mechanisms include microvascular

dysfunction, coronary artery spasm, and the most accepted is the effect of plasma catecholamine levels and sympathetic innervation in cardiac myocytes.¹ Some authors suggested that stress hormones such as epinephrine, norepinephrine, and cortisol in presence of a stress potentiates and regulate the actions of catecholamines on the cardiac tissue and induce transient cardiac contractility dysfunction.⁸

The prevalence of saccular aneurysms in the general population is estimated at 3.2%. Approximately 20%–30% of cases present in the form of multiple aneurysms.⁹ Intracranial aneurysms are generally diagnosed after episodes of subarachnoid hemorrhage (SAH), which causes a high rate of morbidity and mortality.¹⁰ Rupture of an aneurysm is believed to be responsible for 0.4%–0.6% of all aneurysm deaths, and approximately 10% of patients die before arriving at the hospital.¹¹

Takotsubo syndrome is generally reported to have an incidence of 0.8%–17% in patients with SAH caused by ruptured aneurysm.¹² However, this case report is relevant

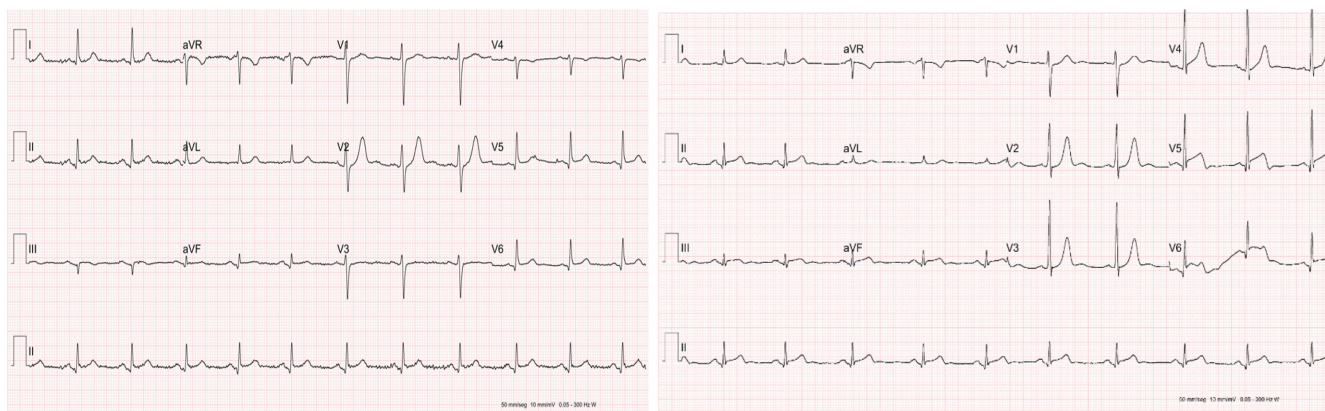


FIGURE 1 Dynamic electrocardiogram change with ST elevation of DIII, AvF, V5 and V6.

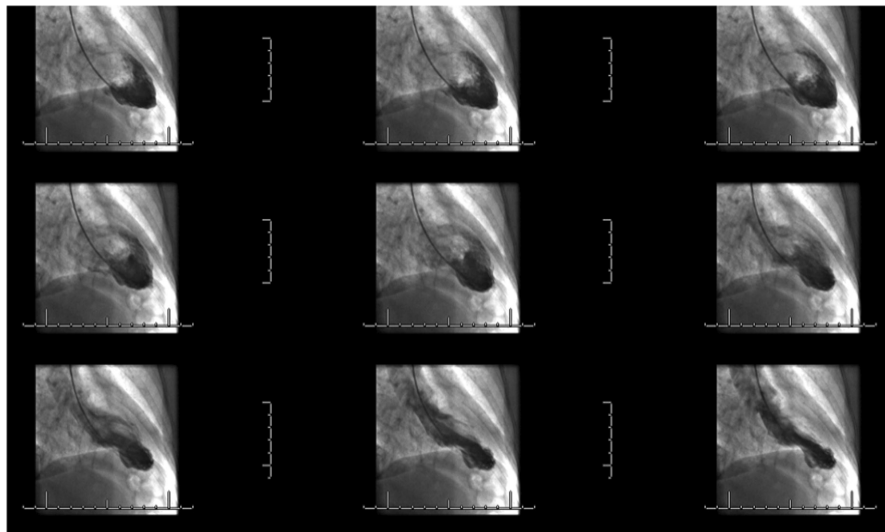


FIGURE 2 Ventriculography showing hypokinesia in the inferoapical wall of the heart.

for the clinical and pathophysiological observation of the possible association between aneurysms of the internal carotid arteries (ICA) and TS, with the latter being able to serve as an alert for possible aneurysms and thus allow for intervention prior to disruption.

2 | CASE PRESENTATION

A 54-year-old female had a history of systemic arterial hypertension and migraine. She had previously been treated with atenolol 25 mg once daily and hydrochlorothiazide 25 mg once daily. She sought medical care at a secondary hospital due to chest pain, which began suddenly 2 h before admission and had irradiated to the left upper limb and back. The initial electrocardiogram (EKG) was normal but showed a troponin curve 33.38, 26.42, 13.82 ng/L (<0.4 ng/L), which led to the hypothesis of non-ST elevation myocardial infarction, Killip I. Loading doses of acetylsalicylic acid (ASA) 300 mg, clopidogrel 300 mg, enoxaparin 60 mg, and nitroglycerin were administered intravenously due to persistent pain. The patient was later transferred to a tertiary hospital. Upon admission she was lucid, oriented in time and space, and pain-free, with the use of nitroglycerin 8 mL/h. Her blood pressure was 128/74 mmHg, mean blood pressure was 92 mmHg, and heart rate was 78 bpm. Serial EKG showed dynamic changes with ST-segment elevation in DIII, AvF, V5, and V6 (Figure 1). Therefore, urgent cardiac catheterisation was performed, but it did not reveal any obstructive lesions. However, ventriculography

revealed hypokinesia in the inferoapical wall (Figure 2), which supported the hypothesis of takotsubo syndrome. During hospitalization, the patient experienced a severe refractory headache. Computed tomography (CT) of the head was performed under suspicion of SAH, and the examination results were normal. Subsequently, CT angiography (angio CT) of the head was performed to rule out a rupture of the aneurism. The angio CT identified “mirror” saccular aneurysms in the ophthalmic segment of the ICAs. The largest aneurysm was on the right, and in superior orientation the lesion measured 5×4 mm with a neck of 3 mm (Figure 3). The patient was subsequently transferred from the cardiology unit to the intensive care unit and underwent lumbar puncture. Clear and colorless cerebral spinal fluid was observed after centrifugation, which confirmed the absence of SAH. The patient was diagnosed with unruptured aneurysm and underwent embolization of a supraclinoid ICA aneurysm using two stents to contain the metal coil. This procedure had no complications. The patient progressed satisfactorily and was discharged with a recommendation for outpatient follow-up in the general cardiology department. She was treated with enalapril, atenolol, atorvastatin, and ASA/clopidogrel.

3 | DISCUSSION

The association between takotsubo syndrome and aneurysmal SAH in some populations has previously been reported. Therefore, it was necessary to perform screening

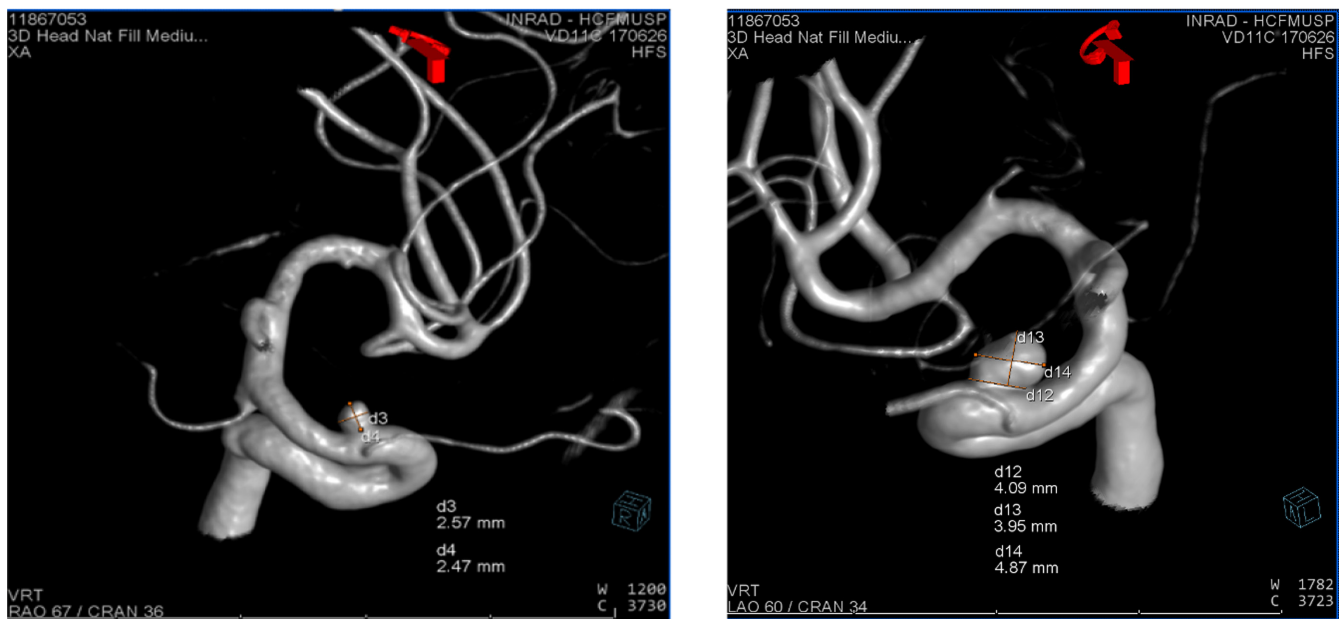


FIGURE 3 Cranial computed tomography angiography, which identified “mirror” saccular aneurysms in the ophthalmic segment of the internal carotid arteries.

for SAH and the discovery of an unruptured aneurysm in this case report.^{13,14}

To the best of our knowledge, this is the first report of takotsubo syndrome and unruptured cerebral aneurysm. Therefore, we believe that patients with a diagnosis of takotsubo syndrome need heightened vigilance and in particular cases should undergo an angio CT scan for cerebral aneurysm, due to the known risk of rupture. Early diagnosis of aneurysms is possible, and acting in a preventive manner with rapid institution of prerule treatment reduces morbidity and mortality. The present case report differs from most cases of takotsubo syndrome described in the literature since it presents unruptured mirror aneurysms, while most cases are diagnosed after intracranial hemorrhage. Takotsubo cardiomyopathy may be pathophysiologically linked to cerebral aneurysm and an early investigation in cases of high clinical suspicion, should be considered with Angio CT to reduce morbidity and mortality as a preventive protocol.

AUTHOR CONTRIBUTIONS

Tânia Amaro: Conceptualization; methodology; writing – review and editing. **Taynara Sgarbi:** Investigation; writing – original draft. **Raísa Vieira:** Investigation; writing – original draft. **Rafael Reis Santos:** Investigation; writing – original draft. **Priscila Matos:** Methodology; writing – original draft. **Adilson Oliveira:** Supervision; validation.

FUNDING INFORMATION

None.

CONFLICT OF INTEREST STATEMENT

The authors declare that they have no conflict of interest.

DATA AVAILABILITY STATEMENT

Data available on request due to privacy/ethical restrictions

CONSENT

The authors confirm that written consent for submission and publication of this case report, including images and associated text, was obtained from the patient in line with the COPE guidance.

ORCID

Tânia Amaro  <https://orcid.org/0000-0002-3300-8215>

Adilson Oliveira  <https://orcid.org/0000-0002-2876-6521>

REFERENCES

1. YHassan S, Tornvall P. Epidemiology, pathogenesis, and management of takotsubo syndrome. *Clin Auton Res*. 2018;28:53-65.
2. Ghadri JR, Wittstein IS, Prasad A, et al. International expert consensus document on takotsubo syndrome (part I): clinical characteristics, diagnostic criteria, and pathophysiology. *Eur Heart J*. 2018;39:2032-2046.
3. Hinkelbein J, Mey C, Brinker G, Pfister R, Bottiger BW. Takotsubo cardiomyopathy associated with repetitive anaesthesia in a female patient. *BMC Anesthesiol*. 2015;15:39.
4. Donohue D, Movahed MR. Clinical characteristics, demographics, and prognosis of transient left ventricular apical ballooning syndrome. *Heart Fail Rev*. 2005;10:311-316.
5. Mirijello A, D'Errico MM, Curci S, et al. Takotsubo syndrome and inflammatory bowel disease: does a link exist? *Dig Dis*. 2020;38:204-210.
6. Dote K, Sato H, Tateishi H, Uchida T, Ishihara M. Myocardial stunning due to simultaneous multivessel coronary spasms: a review of five cases. *J Cardiol*. 1991;21:203-214.
7. Ghadri JR, Wittstein IS, Prasad A, et al. International expert consensus document on takotsubo syndrome (part II): diagnostic workup, outcome, and management. *Eur Heart J*. 2018;39:2047-2062.
8. Trisha SBM, Hilal Khan MBBCBAO, et al. Takotsubo syndrome: pathophysiology, emerging concepts and clinical implications. *Circulation*. 2022;145(13):1002-1019. doi:10.1161/CIRCULATIONAHA.121.055854
9. Stehbens W. Aneurysms and anatomical variation of cerebral arteries. *Arch Pathol*. 1963;75:45-64.
10. Raps EC, Rogers JD, Galetta SL, et al. The clinical spectrum of unruptured intracranial aneurysms. *Arch Neurol*. 1993;50:265-268.
11. Van der Kamp LT, Rinkel GJE, Verbaan D, et al. Risk of rupture after intracranial aneurysm growth. *JAMA Neurol*. 2021;78:1228-1235.
12. Mutoh T, Mutoh T, Taki Y, Ishikawa T. Takotsubo cardiomyopathy as a neurocardiogenic injury after subarachnoid hemorrhage: hemodynamics and fluid management. In: Kirali K, ed. *Cardiomyopathies - Types and Treatments [Internet]*. IntechOpen; 2017 Available from: <https://www.intechopen.com/chapters/52169>
13. Abd TT, Hayek S, Cheng JW, Samuels OB, Wittstein IS, Lerakis S. Incidence and clinical characteristics of takotsubo cardiomyopathy post-aneurysmal subarachnoid hemorrhage. *Int J Cardiol*. 2014;176:1362-1364.
14. Elgendy AY, Elgendy IY, Mansoor H, Mahmoud AN. Clinical presentations and outcomes of takotsubo syndrome in the setting of subarachnoid hemorrhage: a systematic review and meta-analysis. *Eur Heart J Acute Cardiovasc Care*. 2018;7:236-245.

How to cite this article: Amaro T, Sgarbi T, Vieira R, Santos RR, Matos P, Oliveira A. Incidental cerebral aneurysm after takotsubo cardiomyopathy: A case report. *Clin Case Rep*. 2023;11:e7998. doi:10.1002/ccr3.7998