

Total Gynecomastia Removal with Layered Closure: A Study of 567 Cases

Robert C. Caridi, MD

Background: Conventional teaching dictates subtotal removal of gynecomastia tissue to ensure a cosmetically acceptable result. Modern-day concerns regarding gynecomastia treatment include continued “puffy nipples,” possible recurrence, and compromised aesthetic results resulting from incomplete tissue removal. The author practiced complete tissue removal with a layered closure technique to optimize the cosmetic result while addressing treatment complications.

Methods: A single surgeon treated 567 patients using a standard four-step approach with complete tissue removal. A retrospective chart review was performed to assess complications and reason for surgical revision.

Results: All revision procedures were for postoperative scar tissue accumulation. No revisions for complaints of contour depression, recurrence, or continued puffy nipples were noted. No necrosis of the nipple-areola complex or skin was noted.

Conclusions: Complete removal of gynecomastia tissue was not only possible but also essential to achieve optimal cosmetic results. The layered closure technique is a useful adjunctive treatment after gynecomastia total tissue removal. (*Plast Reconstr Surg Glob Open* 2022;10:e4256; doi: [10.1097/GOX.0000000000004256](https://doi.org/10.1097/GOX.0000000000004256); Published online 13 April 2022.)

INTRODUCTION

It is widely accepted that some gynecomastia tissue should remain under the nipple-areola complex (NAC) after treatment (subtotal glandular resection) to minimize complications, such as contour irregularity, NAC depression, NAC distortion, and vascular compromise with possible necrosis.¹⁻⁴ However, this approach is pursued even though leaving this tissue under the NAC can cause the undesirable appearance of “puffy nipples” and widened areolas while also increasing the possibility of recurrence and a compromised aesthetic result. Thus, a contradiction exists between potential NAC deformities caused by total gynecomastia tissue removal under the areola and the necessary removal of this tissue to produce the desired smaller, flatter NACs; minimize recurrence; and optimize chest masculinization. Accordingly, the objective of this study was to determine if complete removal of gynecomastia tissue without NAC deformity is achievable using an adjunctive layered closure technique

that utilizes superficial fascial layers of the chest to reconstitute subcutaneous volume to support the NAC. The primary metrics of analysis were surgical assessments of the patient cohort and requests for NAC revision for depression deformity.

METHODS

This study was based on 567 consecutive patients who had undergone surgery by a single surgeon over the course of 2 years (January 2018–December 2019). Cases requiring skin removal treatment were excluded from this study. All cases were treated according to the standard approach of the author, which included (1) tumescent infiltration of the affected zones; (2) ultrasound-assisted liposuction (UAL) of the gynecomastia tissue; (3) vacuum-assisted, cannula-based liposuction; and (4) tissue removal through a partial periareolar incision. [See Video 1 (online), which shows the intraoperative four-step approach used in each study case]. The author did not treat any patient using liposuction alone. All patients require additional removal of gynecomastia tissue, particularly the most impactful tissue immediately beneath the NAC. The layered closure technique was developed during the course of this study and was applied progressively (see Results section).

From the Austin Gynecomastia Center, Westlake Plastic Surgery, Austin, Tex.

Received for publication January 12, 2022; accepted February 15, 2022.

Copyright © 2022 The Author. Published by Wolters Kluwer Health, Inc. on behalf of The American Society of Plastic Surgeons. This is an open-access article distributed under the terms of the [Creative Commons Attribution-Non Commercial-No Derivatives License 4.0 \(CCBY-NC-ND\)](https://creativecommons.org/licenses/by-nc-nd/4.0/), where it is permissible to download and share the work provided it is properly cited. The work cannot be changed in any way or used commercially without permission from the journal.

DOI: [10.1097/GOX.0000000000004256](https://doi.org/10.1097/GOX.0000000000004256)

Disclosure: The author has no financial interest in relation to the content of this article.

Related Digital Media are available in the full-text version of the article on www.PRSGlobalOpen.com.

A retrospective chart review was performed 1 year following the study time frame to examine the frequency of, and reasons for, surgical revisions. The specific categories included depression of the NAC, scar formation, seroma, hematoma, skin necrosis, and recurrence. The diagnosis of gynecomastia was made by visual assessment of enlarged areola, puffy nipples, and female-like breasts. All patients were treated in an American Association for Accreditation of Ambulatory Surgery Facilities outpatient, office-based operative facility. A zone assessment of the patient was performed according to the Gynecomastia Zone Classification System (Fig. 1).⁵ Ninety percent of cases were managed with general anesthesia, whereas local anesthesia was performed on patients with small gynecomastia masses localized to zone 1.

The extent of the actual gynecomastia tissue was marked by circular perimeters centered on each nipple, while additional fullness in the affected zones was marked for comprehensive masculinized chest contouring. A stab incision was made in the axillary hair-bearing region, and the standard tumescent solution was infiltrated. A skin protector was placed on the stab incision, and the UAL instrument was directed at, and limited to, the gynecomastia tissue, using 80% power for an average time of 8 minutes (range 4–15 min).

Standard liposuction was then used to remove the UAL effluent in zone 1, with additional treatment provided to the surrounding affected zones, as necessary. A 2-cm incision was made at the inferior areola border, and a “top down” (removal of all tissue between the subareolar dermis and the prepectoral fascia) approach to gynecomastia tissue removal was performed using Stevens scissors and finger dissection for en bloc tissue removal, with additional piecemeal tissue removal as needed. A 4-mm mastectomy flap was created anteriorly with a perimeter layer of prepectoral subcutaneous tissue posteriorly. Absorbable sutures were then used to approximate the tissue layers to reconstitute a layer of supporting subcutaneous fat and fascia beneath each NAC. [See Video 2 (online), which shows the intraoperative use of the layered closure.] Feathering liposuction and piecemeal reduction

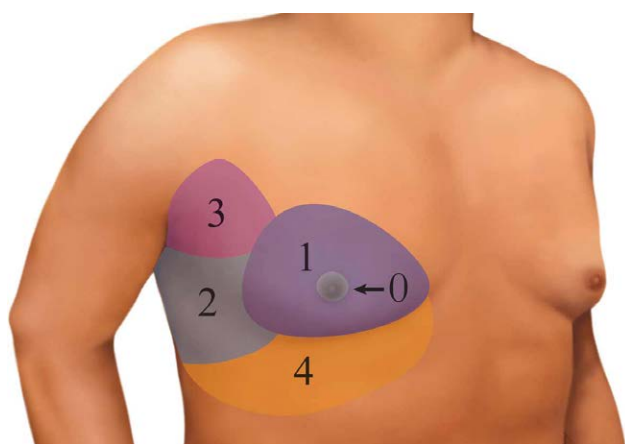


Fig. 1. Oblique view of the male chest illustrating the zone classification system.

Takeaways

Question: Can all gross gynecomastia tissue be removed with satisfactory cosmetic results? Current standard of care suggests leaving behind gynecomastia tissue to avoid a cosmetic deformity.

Findings: A large patient cohort had complete removal of gynecomastia tissue in addition to reconstitution of an underlying layer of subcutaneous tissue. There were no instances of remaining tissue, contour depression or continued puffy nipples.

Meaning: Complete removal of gynecomastia tissue is possible and preferable in the treatment of gynecomastia.

of the peripheral tissue were performed to produce a smooth contour. No drains were used. The skin incision was closed using absorbable suture material. Appropriate dressings and garments were used. The average surgery time was 55 minutes.

RESULTS

Among the 567 cases reviewed in this study, 380 (67%) were treated using the layered closure technique. The technique was developed during the period in which the patients were treated and was incorporated with greater frequency over time (61% in 2018 and 78% in 2019). Currently, all cases are managed surgically with a layered closure. Table 1 summarizes patient and treatment characteristics. The mean age of patients was 31 years (median, 29 years; range, 15–59 years) with a body mass index of 26.5 kg per m² (median 25.8 kg/m²; range, 18.3–37.1 kg/m²). The mean VASER time per side of chest was 10.16 minutes

Table 1. Summary of Patient and Treatment Characteristics

Characteristic	Total (%)
No. patients	567
2018	285
2019	282
Age at treatment, y	
Mean	31
Median	29
Range	15–59
BMI, kg/m ²	
Mean	26.5
Median	25.8
Range	18.3–37.1
VASER time, min*	
Mean	10.16
Median	9.09
Range	3.05–23.18
Mass excised, g	
Mean	31
Median	20
Range	1–228
Complications	33 (5.8)
Seroma	13 (2.3)
Hematoma	11 (1.9)
Scar adherence revision	9 (1.6)
Depression of the NAC	0
Infection	0
Skin necrosis	0
Recurrence	0
Nipple protrusion/puffy nipple	0

*Time treated per chest side.

(median, 9.09 minutes; range, 3.05 to 23.18 minutes) with the mean excised gynecomastia mass size of 31 g (median, 20; range, 1–228 g). The total complication rate was 5.8%. Notable complications included seroma in 13 cases (2.3%) and hematoma in 11 cases (1.9%). No infections were observed. Patients' requests for surgical revision occurred in nine cases (1.6%). All surgical revisions were performed due to the posttreatment accumulation of scar tissue, appreciated as palpable masses in zone I. No cases of depression at the NAC, gynecomastia recurrence, necrosis of the skin, or continued presence of puffy nipples occurred.

DISCUSSION

Central to the condition of gynecomastia are the patient complaints of feminized breasts and the abnormal protrusion of the NAC (ie, "puffy nipples," as they are currently described). These appearances result from the gynecomastia tissue and specifically, the expansion and herniation of the areola caused by the tissue immediately beneath the NAC. A common complaint after gynecomastia treatment is persistent chest fullness and puffy nipples from incomplete gynecomastia tissue removal. Thus, the goals of gynecomastia treatment are the complete removal of the gynecomastia tissue (especially subareolar), optimal contouring of the aesthetic zones of the chest, and reconstitution of tissue beneath each NAC. The final result should include an even layer of subcutaneous tissue without depressions or contour asymmetries and a masculine chest appearance with enhanced definition.^{3,6}

The historical treatment of gynecomastia involved sharp excision subcutaneous mastectomies that entailed high rates of complications and resulted in low rates of patient satisfaction.^{2,7} The addition of adjunctive liposuction in the late 1970s resulted in a vastly improved contour and higher patient satisfaction.^{2,8–10} The subsequent use of UAL in the treatment of gynecomastia resulted in further refinement.^{11–13} Third generation UAL was used on all patients in this study. Improved outcomes, growth in the experience of surgeons, and availability of internet resources have led, in turn, to greater patient expectations and concerns regarding the procedural results. Patients expect complete tissue removal to reduce the risk of recurrence and persistence of posttreatment puffy nipples, and to ensure the optimal aesthetic result. The author aimed to achieve complete gynecomastia tissue removal with optimal aesthetic results.

The gold standard treatment for gynecomastia is surgery involving liposuction and tissue removal. Used individually, liposuction or tissue removal produces compromised results and patient dissatisfaction. As an exception, bodybuilders with little or no body fat require only a glandular mass removal.^{14–16} Currently, there is no accepted standard approach for gynecomastia treatment, and results continue to be inconsistent. Reliable studies regarding treatment outcomes and satisfaction were of poor quality and included a limited number of patients.^{2,11}

Layered Closure

Gynecomastia tissue is identified on physical examination as a well-defined, firmer mass, centered at the NAC. It is rarely "rubbery," as it is often described in

clinical definitions. The perimeter of the mass is easily discerned and marked preoperatively. Complete removal of the gynecomastia tissue creates a significant tissue void between the subareolar space and the underlying pectoral fascia. Untreated, this defect may result in distortion of the NAC (ie, "donut" or crater deformity) as well as scar adherence between the NAC and muscle. The author was able to recognize and mobilize adjacent normal tissue to reconstitute a layer of subcutaneous tissue, filling the void and supporting the NAC (Figs. 2–7). This surgical maneuver was elegantly described in an undeveloped form by Jerome Webster in 1945 as the joining of "adipose tissue" after gynecomastia removal to "form a uniformly thick layer over the pectoral fascia [so] the nipple must not be allowed to adhere directly to the pectoral fascia, nor must there be a concavity in the mammary region."^{17,18}

The layered closure procedure used in this study was more complicated and robust than simply joining fatty tissue. Anatomic studies have demonstrated that the male chest has several layers of superficial fascia (ie, the anterior and posterior lamellar fascia). These structures are analogs of Camper's and Scarpa's fascia¹⁹ (Fig. 8). [See Video 3 (online), which shows the dissection and anatomical view of the superficial fascia layers of the chest.] Hyperplastic gynecomastia tissue, which is embryological in origin, is found immediately beneath the nipple. As this tissue responds to sex hormones, it significantly enlarges and distorts the tissue layers. The result is a well circumscribed and easily palpated mass of varying size and tissue composition, centered at the NAC, and radiating peripherally (ie, the gynecomastia condition).

The tissue layers of the chest are mobile and retract significantly after gynecomastia mass removal. Because of the anatomy of the inframammary fold, the tissue layer with the bilamellar fascia component retracts primarily in the cephalic direction and to a lesser extent caudally. After mass removal, it is not uncommon to reconstitute a gap of up to 6 cm using layered closure. The chest's subcutaneous thickness increases toward the periphery.²⁰ The pectoral fascial layers and accompanying fat are receptive

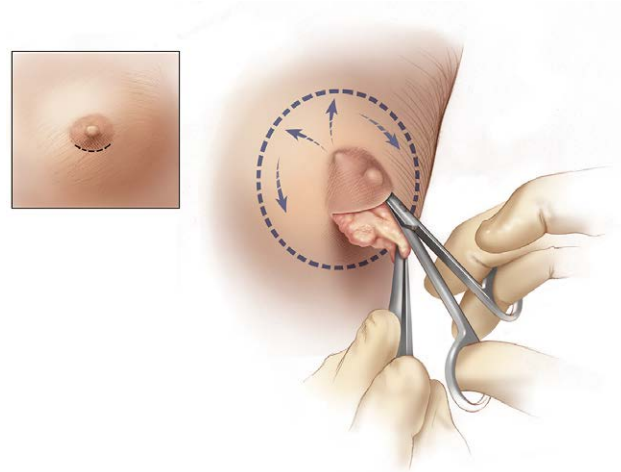


Fig. 2. Subdermal dissection beneath the NAC with periareolar approach.

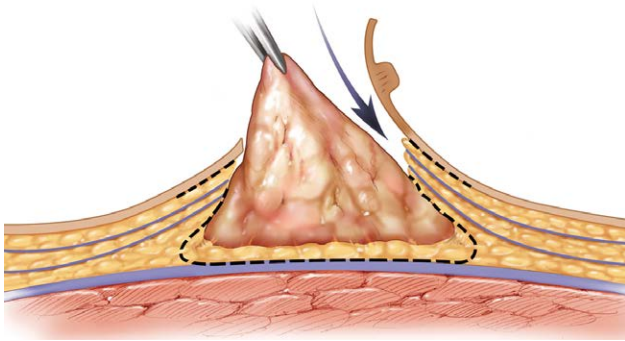


Fig. 3. Complete removal of well-circumscribed gynecomastia tissue.

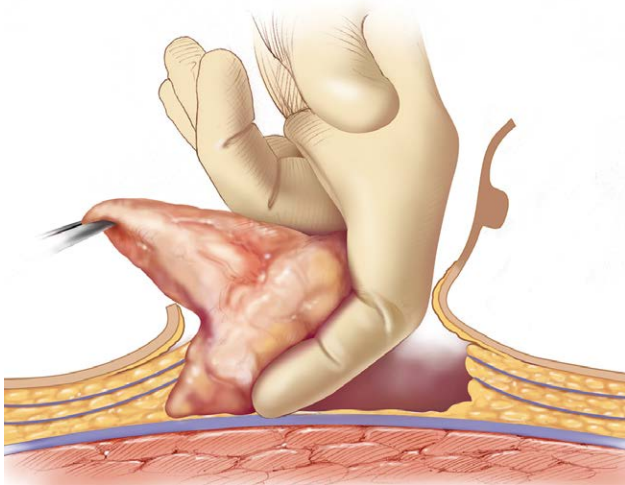


Fig. 4. En bloc gynecomastia removal aided by finger dissection.

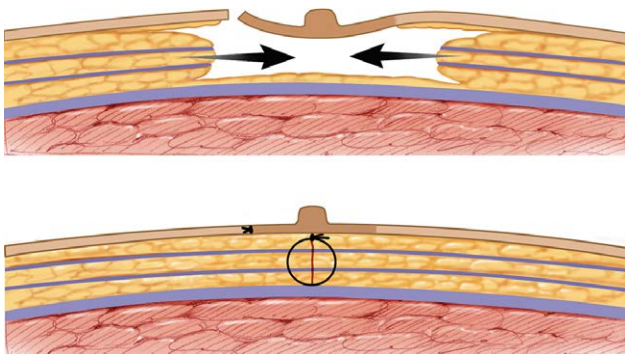


Fig. 5. Layered closure with dead space elimination and NAC support.

to suture techniques, allowing reconstitution with tension. To avoid depression at the NAC, the author removed all gynecomastia tissue and reconstituted a new layer of adjacent subcutaneous tissue using several 2-0 absorbable sutures. [See Video 2 (online), which shows the intraoperative use of the layered closure.] UAL was used to treat gynecomastia tissue in zone 1, whereas standard liposuction was used in all other treatment areas. UAL is more effective in the treatment of dense, gynecomastia tissue

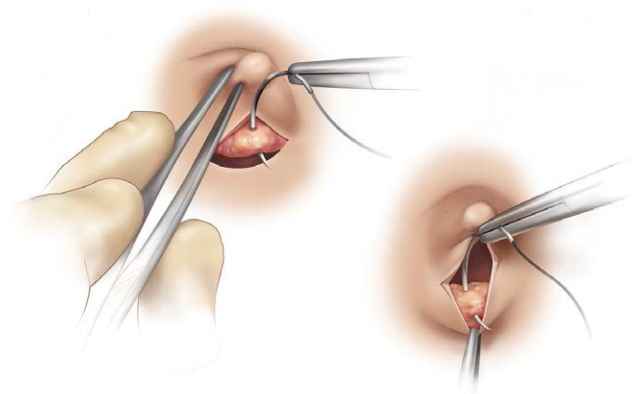


Fig. 6. Superior and inferior layered closure approximation.

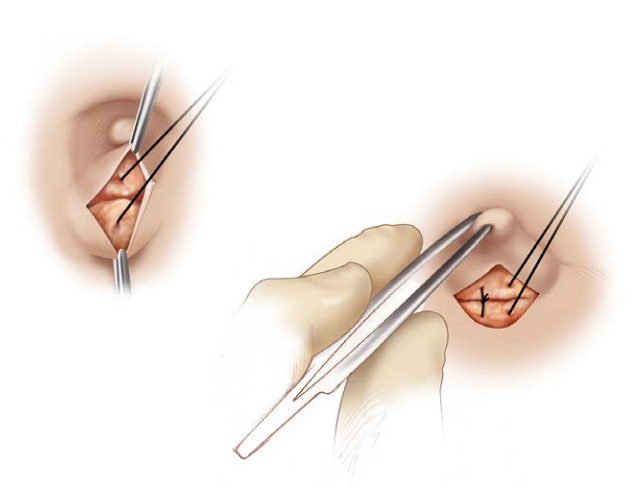


Fig. 7. Reconstitution of underlying subcutaneous tissue.

than suction-assisted lipoplasty.^{11,12,21} UAL is ineffective in the removal of dense fibroglandular tissue beneath the NAC, which requires surgical removal.^{12,22} UAL treatment of gynecomastia tissue provides effective hemostasis, reduces surgeon fatigue, enhances tissue shrinkage, and facilitates separation of gynecomastia tissue from normal tissue, expediting subsequent mass removal. Furthermore, the use of electrocautery, special instruments, or retractors is not necessary.

Unlike female nipple-sparing mastectomies, creating quality mastectomy flaps based on aesthetic or vascular concerns was not the focus of treatment. Mastectomy flaps are often less than 4-mm thick; thinner mastectomy flaps are associated with greater retraction and optimal muscular definition (ie, the treatment endpoint). UAL was not used for skin retraction enhancement.^{11,21} Clinically, flap retraction is overwhelmingly dependent on inherent skin elasticity and minimally impacted by skin tightening modalities. Skin elasticity is the single most important feature for predicting satisfactory results.

In the study cohort, there were no cases of skin or nipple-areola necrosis, a potential mastectomy complication associated with the complete removal of subareolar tissue. This is relevant because UAL is associated with a thermal

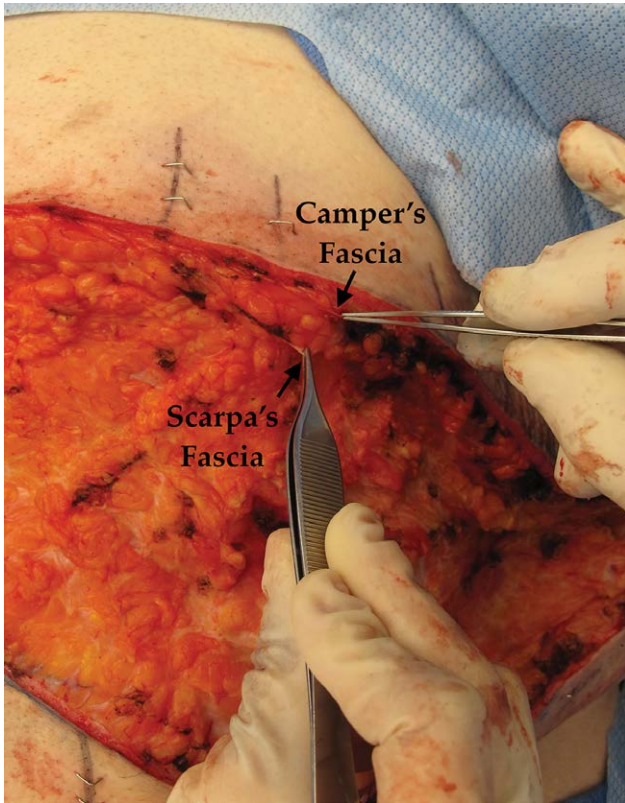


Fig. 8. Intraoperative view, in a nonstandard, excisional gynecomastia case, of the two superficial fascial layers used in the layered closure: Camper's fascia (upper arrow) and Scarpa's fascia (lower arrow).

energy byproduct that is detrimental to vascularity. The author has observed nipple-areola necrosis and, more commonly, superficial epidermolysis of the NAC and the loss of the distal nipple. By comparison, nipple-sparing mastectomy in the female breast has rates of vascular compromise ranging from 1% to 8%.²⁰ The author is unaware of studies comparing male and female mastectomies.

Enlarged areolas are a common complaint associated with gynecomastia. The treatment provided in this study resulted in smaller, darker areolas because the total tissue removal, with subdermal dissection and thinner flaps, promoted greater skin retraction.²³ A surgical reduction in areolar size concurrent with total subareolar tissue removal is not recommended; it is rarely needed, risks vascular compromise, and is often associated with poor scarring. Secondary treatment is optional, but is not often requested, as NAC retraction improves significantly over time.

There is a concern regarding gynecomastia recurrence, the frequency of which is unknown.¹⁶ The author has not experienced recurrence in cases involving the complete removal of gynecomastia tissue, even though some residual hormonally sensitive tissue theoretically remained. Suspected recurrence results from incomplete tissue removal (ie, undertreatment) or scar tissue development (ie, healing complications). With regard to gynecomastia treatment results, "better" may not be an acceptable goal, considering the active online gynecomastia community that shares information in community forums. The

complete removal of gynecomastia tissue provides patients with the optimal chest contour, peace of mind, and the least risk of recurrence, even if they continue to use hormones and supplements implicated in gynecomastia.

Determining which patient is a candidate for nonskin removal versus skin removal treatment is based on clinical judgment. An algorithm for the treatment of gynecomastia is suggested (Fig. 9). Although gynecomastia size and the degree of ptosis are important features to assess, inherent skin elasticity is of paramount significance and profoundly impacts results, often obviating the need for skin removal with associated complexity and scarring. Owing to our limited ability to assess skin elasticity objectively, experience is essential for proper patient selection. Patients with an extreme weight loss history, very ptotic chest tissue, stretch marks, thin skin, and poor skin elasticity on examination are more likely to be skin removal candidates. In addition, the procedure can be staged, if necessary. The author does not recommend the use of Wise or vertical skin excision patterns, as these were designed for the female breast to create projection and a female shape. An incision pattern following the inframammary fold, with lateral chest

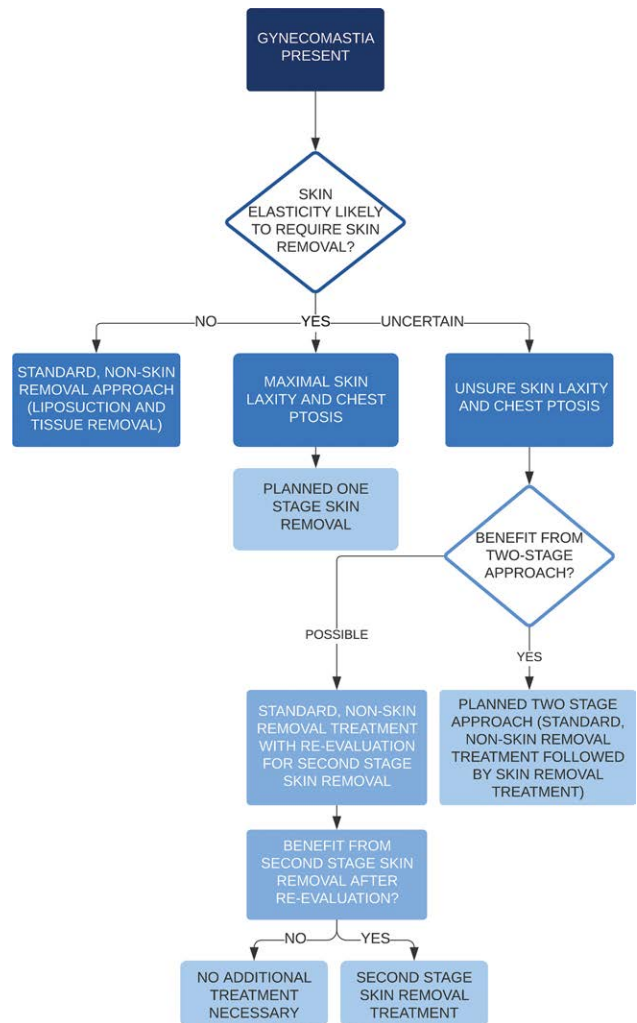


Fig. 9. Algorithm for the treatment of gynecomastia.

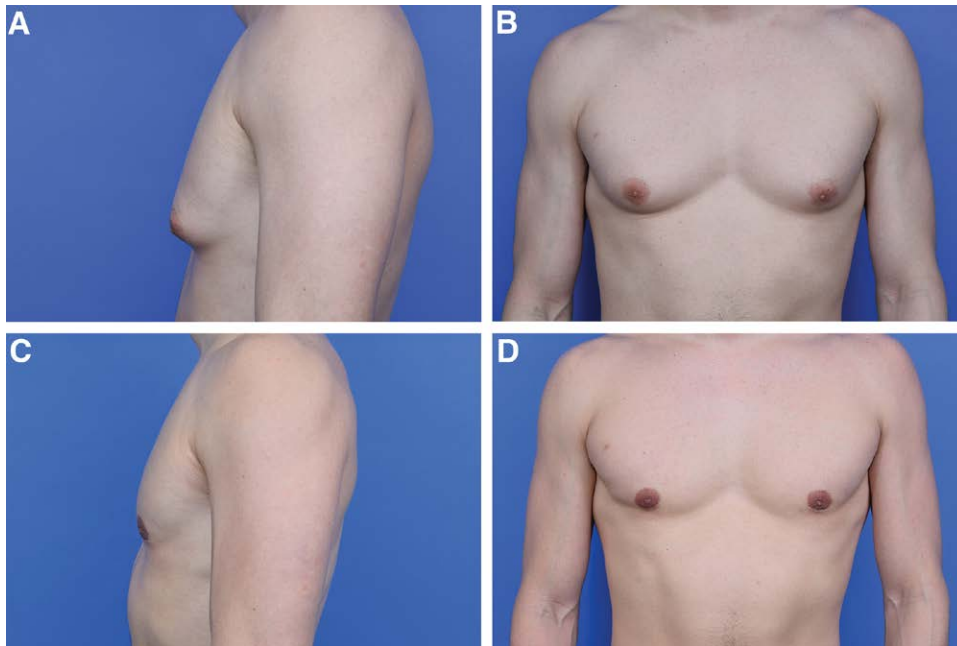


Fig. 10. Patient number 347 presenting with zone 1 gynecomastia seen before and after treatment. A, Preoperative lateral view. B, Preoperative frontal view. C, postoperative lateral view. D, postoperative frontal view.

extensions as needed and free nipple grafting is ideal. This is similar to the successful mastectomy approach in gender-affirming surgery.^{24–27}

No revision for depression of the NAC was identified in early patients in the study who did not undergo layered closure treatment. In these cases, the author performed a more aggressive mastectomy with thinner mastectomy flaps more closely matching the thinner NAC to avoid depression. This approach placed the patient at a higher risk for skin and NAC vascular compromise and contour irregularities from overtreatment. The layered closure technique fills the void immediately beneath the NAC after mass removal, allowing the surgeon to maintain a thicker, higher quality peripheral mastectomy flap, and a smooth chest contour (Figs. 10–13).

In this study, no surgical revisions were needed to correct depressions, scar adherence, saucer or “donut” deformities. The most common indication for revision was scar tissue accumulation during the postoperative period, commonly misunderstood as gynecomastia recurrence. It should be noted that the results from treatment as performed are immediate, with scar tissue formation appearing as new growth in the weeks to early months following treatment. Scar tissue formation may be related to the presence of residual fluids in the tissue (ie, blood or seroma), dead space created by the mass removal, the use of UAL,¹¹ a large underlying active pectoralis muscle, a genetic propensity for excess scarring, and other factors. Seroma and hematoma are closely associated with scar formation after gynecomastia treatment, most likely due to an excessive inflammatory response. To avoid this complication, patients are instructed to manage their recovery actively with compression garments, limited activity,

and manual or mechanical massage techniques. They are also advised to minimize the intake of fluids, particularly alcohol. Additionally, local injections of steroids are performed as necessary to mitigate scar tissue formation. The complication rates from this study are comparable to previously published rates, indicating that the technique used is acceptable for the treatment of gynecomastia.^{1–3,6,11}

LIMITATIONS

The limitations of this study are related to its retrospective design and the lack of standardization and randomization, despite the large cohort size. There was no objective analysis of the aesthetic results, which makes the results less dependable. There were no validated outcome assessment questionnaires specifically for gynecomastia

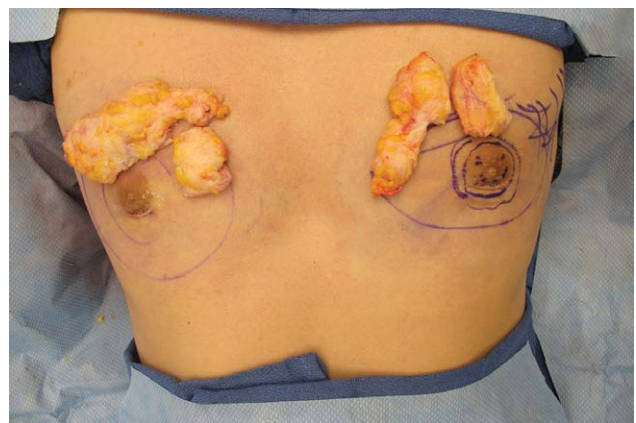


Fig. 11. Intraoperative tissue specimen from patient number 347 seen in Figure 10.

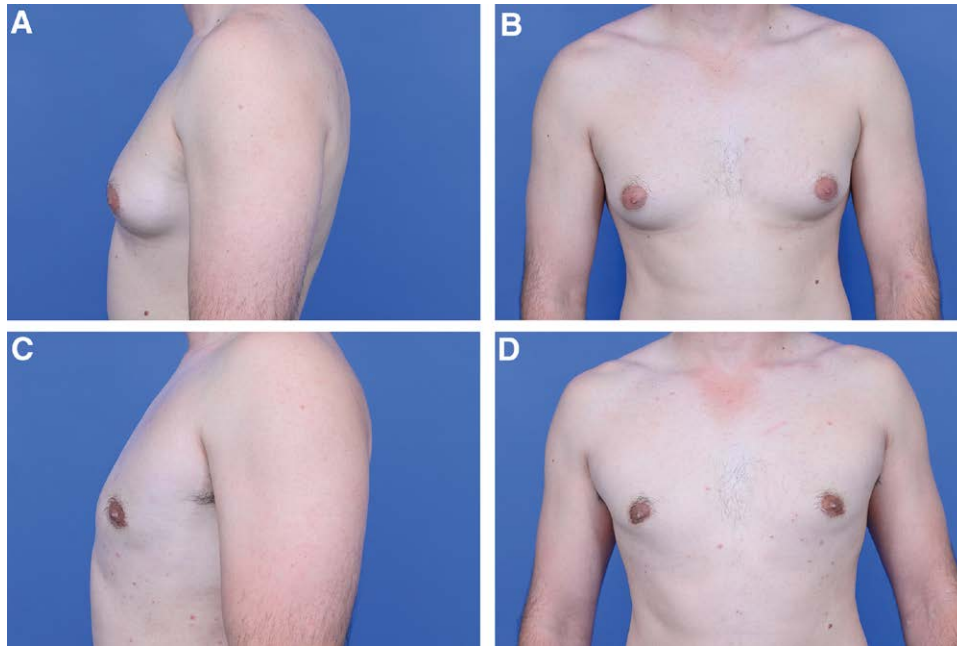


Fig. 12. Patient number 283 presenting with zone 1 gynecomastia seen before and after treatment. A, preoperative lateral view. B, preoperative frontal view. C, postoperative lateral view. D, postoperative frontal view.

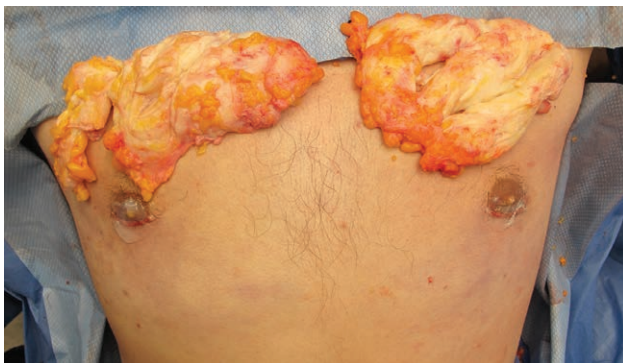

Fig. 13. Intraoperative tissue specimen from patient number 283 seen in Figure 12.

available for this study. Anecdotally, patient satisfaction was high in the group as determined by the postoperative follow-up notes, online reviews, general feedback, and the surgeon's assessment.

Comparing the results from different gynecomastia studies is speculative, at best. Gynecomastia literature tends to be dominated by small, nonrandomized, retrospective studies that present poor quality control and a high risk of bias. Considering the treatment's popularity and the underappreciated consequences of gynecomastia, higher quality studies are needed to make evidence-based recommendations.²⁸ The conclusions reached in this article have been confirmed in the subsequent 657 patients following closure of the study.

CONCLUSIONS

Total gynecomastia tissue removal is safe, effective, and is an acceptable treatment goal. The layered closure

technique may prove to be a useful adjunctive treatment for this condition. Additional experience and quality studies are needed to confirm the cosmetic benefits and safety of complete tissue removal.

Robert Caridi, MD

4407 Bee Cave Road, Suite 303
Austin, TX 78746

E-mail: rcaridi@westlakeplasticsurgery.com

REFERENCES

1. Morselli PG, Morellini A. Breast reshaping in gynecomastia by the "pull-through technique": considerations after 15 years. *Eur J Plast Surg.* 2012;35:365–371.
2. Courtiss EH. Gynecomastia: analysis of 159 patients and current recommendations for treatment. *Plast Reconstr Surg.* 1987;79:740–753.
3. Hammond DC. Surgical correction of gynecomastia. *Plast Reconstr Surg.* 2009;124:61e–68e.
4. Simon BE, Hoffman S, Kahn S. Classification and surgical correction of gynecomastia. *Plast Reconstr Surg.* 1973;51:48–52.
5. Caridi RC. Defining the aesthetic units of the male chest and how they relate to gynecomastia based on 635 patients. *Plast Reconstr Surg.* 2018;142:904–907.
6. Huang TT, Hidalgo JE, Lewis SR. A circumareolar approach in surgical management of gynecomastia. *Plast Reconstr Surg.* 1982;69:35–40.
7. Illouz YG. Body contouring by lipolysis: a 5-year experience with over 3000 cases. *Plast Reconstr Surg.* 1983;72:591–597.
8. Teimourian B, Perlman R. Surgery for gynecomastia. *Aesthetic Plast Surg.* 1983;7:155–157.
9. Ersek RA, Schaefer III M, Beckham PH, Salisbury MA. Gynecomastia: A clinical review. *Aesthet Surg J.* 2000;20:381–386.
10. Rohrich RJ, Ha RY, Kenkel JM, et al. Classification and management of gynecomastia: defining the role of ultrasound-assisted liposuction. *Plast Reconstr Surg.* 2003;111:909–23; discussion 924.

11. Hammond DC, Arnold JF, Simon AM, et al. Combined use of ultrasonic liposuction with the pull-through technique for the treatment of gynecomastia. *Plast Reconstr Surg.* 2003;112:891–5; discussion 896.
12. Bailey SH, Guenther D, Constantine F, et al. Gynecomastia management: an evolution and refinement in technique at UT Southwestern Medical Center. *Plast Reconstr Surg Glob Open.* 2016;4:e734.
13. Aiache AE. Surgical treatment of gynecomastia in the body builder. *Plast Reconstr Surg.* 1989;83:61–66.
14. Blau M, Hazani R, Hekmat D. Anatomy of the gynecomastia tissue and its clinical significance. *Plast Reconstr Surg Glob Open.* 2016;4:e854.
15. Babigian A, Silverman RT. Management of gynecomastia due to use of anabolic steroids in bodybuilders. *Plast Reconstr Surg.* 2001;107:240–242.
16. Webster JP. Mastectomy for gynecomastia through a semicircular intra-areolar incision. *Ann Surg.* 1946;124:557–575.
17. Von kessel F, Pickrell KL, Huger WE, et al. Surgical treatment of gynecomastia: an analysis of 275 cases. *Ann Surg.* 1963;157:142–151.
18. Rehnke RD, Groening RM, Van Buskirk ER, et al. Anatomy of the superficial fascia system of the breast: a comprehensive theory of breast fascial anatomy. *Plast Reconstr Surg.* 2018;142:1135–1144.
19. Salibian AA, Frey JD, Choi M, et al. Optimizing the mastectomy flap to improve aesthetic outcomes. *Aesthet Surg J.* 2020;40(Suppl 2):S1–S12.
20. Nagy MW, Vanek PF Jr. A multicenter, prospective, randomized, single-blind, controlled clinical trial comparing VASER-assisted Lipoplasty and suction-assisted lipoplasty. *Plast Reconstr Surg.* 2012;129:681e–689e.
21. Petty PM, Solomon M, Buchel EW, et al. Gynecomastia: evolving paradigm of management and comparison of techniques. *Plast Reconstr Surg.* 2010;125:1301–1308.
22. Lista F, Ahmad J. Power-assisted liposuction and the pull-through technique for the treatment of gynecomastia. *Plast Reconstr Surg.* 2008;121:740–747.
23. Pfeiler PP, Luketina R, Dastagir K, et al. Expected reduction of the nipple areolar complex over time after treatment of gynecomastia with ultrasound-assisted liposuction mastectomy compared to subcutaneous mastectomy alone. *Aesth Plast Surg.* 2021;45:431–437.
24. Monstrey S, Selvaggi G, Ceulemans P, et al. Chest-wall contouring surgery in female-to-male transsexuals: a new algorithm. *Plast Reconstr Surg.* 2008;121:849–859.
25. McEvenue G, Xu FZ, Cai R, et al. Female-to-male gender affirming top surgery: a single surgeon's 15-year retrospective review and treatment algorithm. *Aesthet Surg J.* 2017;38:49–57.
26. Frey JD, Yu JZ, Poudrier G, et al. Modified nipple flap with free areolar graft for component nipple-areola complex construction: outcomes with a novel technique for chest wall reconstruction in transgender men. *Plast Reconstr Surg.* 2018;142:331–336.
27. Salibian AA, Gonzalez E, Frey JD, et al. Tips and tricks in gender-affirming mastectomy. *Plast Reconstr Surg.* 2021;147:1288–1296.
28. American Society of Plastic Surgeons. 2019 Plastic Surgery Statistics Report. 2019:13. Available at <https://www.plasticsurgery.org/documents/News/Statistics/2019/plastic-surgery-statistics-full-report-2019.pdf>.