

Received: 2020.08.18

Accepted: 2020.12.29

Available online: 2021.01.23

Published: 2021.03.04

Successful Treatment with Percutaneous Balloon Kyphoplasty for Syndrome of Inappropriate Secretion of Antidiuretic Hormone Associated with Vertebral Compression Fracture: A Case Report

Authors' Contribution:

Study Design A
Data Collection B
Statistical Analysis C
Data Interpretation D
Manuscript Preparation E
Literature Search F
Funds Collection G

ABCDEF **Toshihide Izumida**
A **Ryusho Sangen**
AEF **Daisuke Usuda**
DEF **Yuji Kasamaki**

Division of Community Medicine, Kanazawa Medical University Himi Municipal Hospital, Himi, Toyama, Japan

Corresponding Author: Yuji Kasamaki, e-mail: kasamaki@kanazawa-med.ac.jp

Conflict of interest: None declared

Patient: Female, 72-year-old
Final Diagnosis: Syndrome of inappropriate antidiuretic hormone secretion (SIADH)
Symptoms: Agitation • nausea • pain
Medication: —
Clinical Procedure: —
Specialty: Endocrinology and Metabolic

Objective: Unusual or unexpected effect of treatment


Background: The etiology of syndrome of inappropriate antidiuretic hormone secretion (SIADH) is highly variable. With little evidence, much of the guidance and recommendations available for management are based on clinical judgement. Although percutaneous balloon kyphoplasty can effectively relieve the severe pain associated with osteoporotic vertebral compression fractures that do not respond to conventional treatments, the effect of balloon kyphoplasty on SIADH associated with vertebral compression fracture remains unknown.

Case Report: A 72-year-old woman was admitted to our hospital due to severe pain associated with lumbar compression fracture and pain-related SIADH. Since her pain could not be relieved by analgesics, she underwent percutaneous balloon kyphoplasty, a minimally invasive procedure intended to relieve pain. After the surgery, the patient's pain almost completely disappeared and her sodium level was gradually corrected within 3 days without any adverse events.

Conclusions: Percutaneous balloon kyphoplasty is a novel treatment option for SIADH associated with vertebral compression fracture. In the case presented here, it rapidly reduced pain and disability and also improved severe pain-associated SIADH without adverse effects. It may offer an alternative to pain regimens consisting of drugs, such as duloxetine, pregabalin, and opioids, that may exacerbate SIADH and hyponatremia. This case suggests treatment for new-onset or worsening hyponatremia in patients with vertebral compression fracture.

Keywords: Fractures, Compression • Inappropriate ADH Syndrome • Perioperative Care

Full-text PDF: <https://www.amjcaserep.com/abstract/index/idArt/928055>



1383



—



2



15



Background

Hyponatremia is a common electrolyte disturbance in clinical practice, and syndrome of inappropriate antidiuretic hormone secretion (SIADH) is the most frequent condition underlying hyponatremia [1]. SIADH is characterized by abnormal release of antidiuretic hormone (ADH) or enhanced action of ADH on the kidney. The causative factors of SIADH include a wide variety of symptoms, diseases, and drugs [2]. There are a variety of management approaches for SIADH in clinical practice, but the evidence supporting their use is limited [3]. Percutaneous balloon kyphoplasty can effectively relieve severe pain associated with osteoporotic vertebral compression fractures that do not respond to conventional treatments, and it may help decrease the physical consequences related to fracture [4,5]. However, the effect of balloon kyphoplasty on SIADH associated with vertebral compression fracture remains unknown.

We report a case of SIADH associated with lumbar compression fracture in a patient who subsequently underwent percutaneous balloon kyphoplasty. We discuss the pathogenesis of SIADH in our case, as well as the perioperative management and treatment strategy for hyponatremia in SIADH associated with lumbar compression fracture.

Case Report

A 72-year-old woman was transferred to our hospital for the evaluation and treatment of severe lower back pain and radiating pain in the left leg. Although no significant traumatic event occurred, she experienced severe and worsening back pain and leg pain for 1 week before her transfer. Upon arrival, the patient rated her pain as 10/10 on a visual analog scale (VAS), where 0 indicated “no pain” and 10 indicated “worst

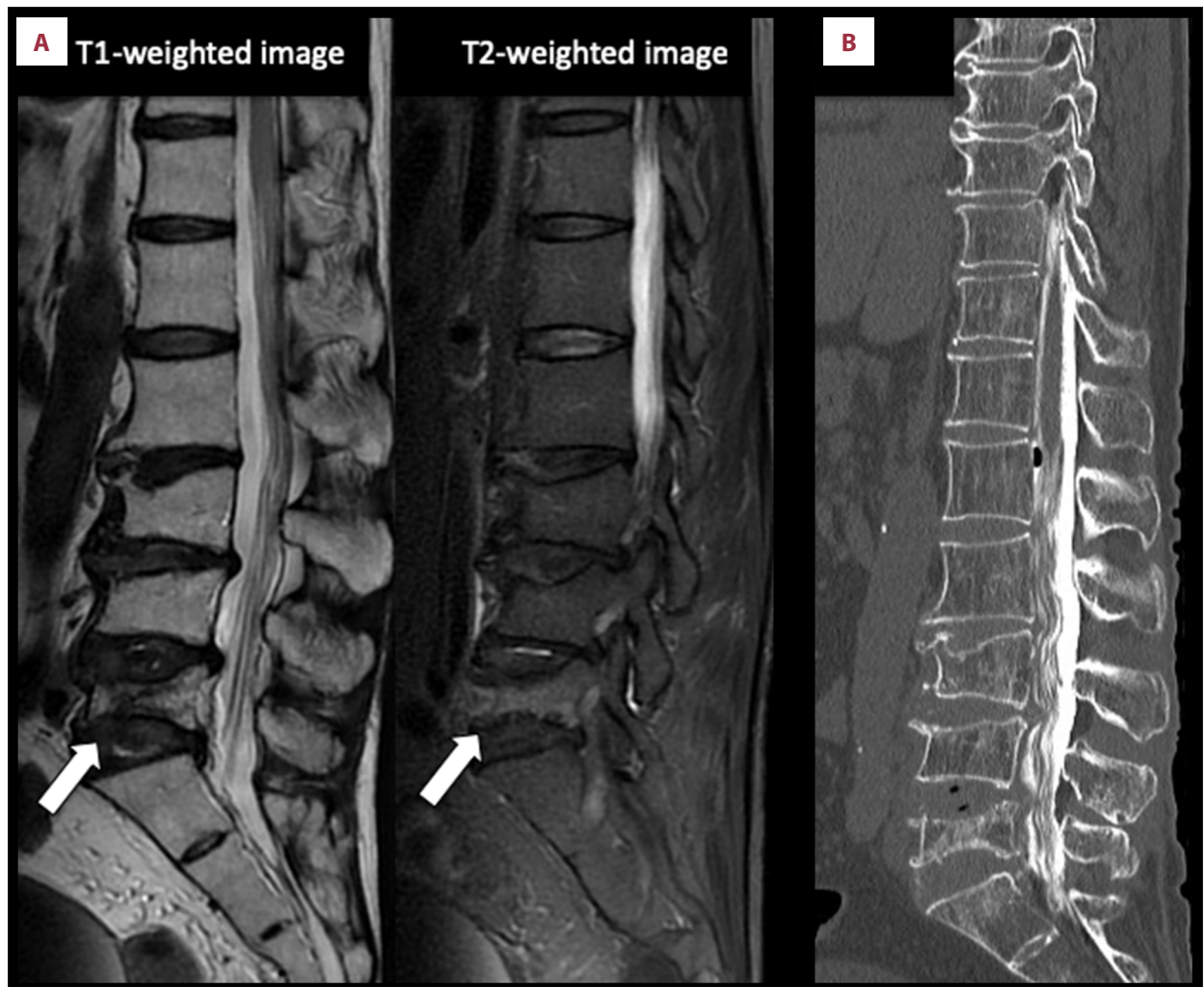


Figure 1. (A) Sagittal lumbar magnetic resonance image displaying a fracture with associated edema on L5. The arrow indicates the fracture. (B) Sagittal computed tomography myelography did not show compressive lesions pressing against the nerve roots and spinal cord.

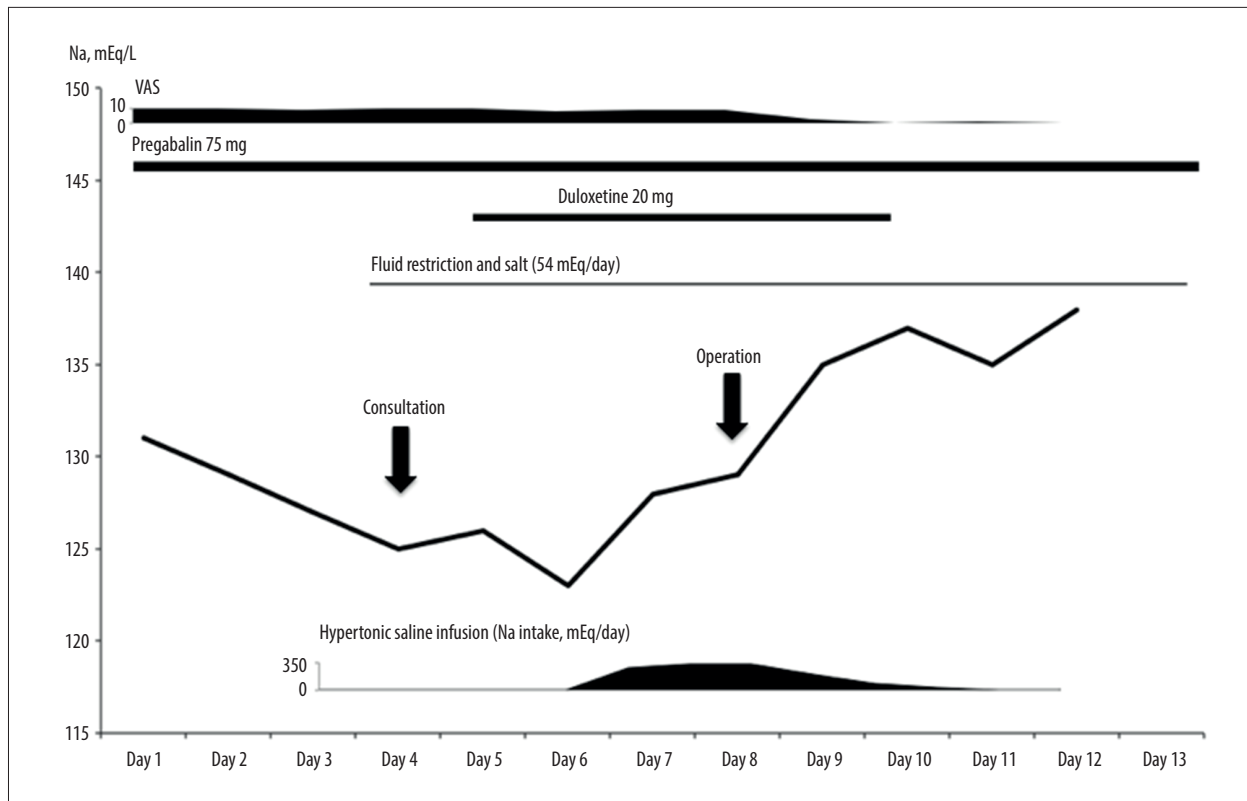


Figure 2. Clinical course of our patient. The image shows the change in serum sodium level in relation to the administration of pregabalin and duloxetine. Hyponatremia gradually resolved after pain relief surgery. VAS – visual analog scale.

pain.” She described her pain as stabbing, and it was exacerbated by movement of the axial spine. She experienced pain radiating toward the left lower extremity, but she had no problems with bowel and bladder function. Magnetic resonance imaging of the spine showed low intensity in a T1-weighted image and high intensity in a T2-weighted image at L5 (Figure 1A). Computed tomography myelography did not show compressive lesions pressing against the nerve roots or spinal cord (Figure 1B). An L5 osteoporotic vertebral compression fracture was diagnosed. The patient’s medical history was significant for type 2 diabetes mellitus and hypertension, but otherwise, she had no remarkable history. Her medications included metformin, angiotensin II receptor blockers, and Ca-channel blocker, but not any diuretics. On the fourth day of admission, a preoperative evaluation was conducted to determine whether pain relief surgery could be safely performed. The patient’s vital signs were as follows: height, 155.0 cm; weight, 47.0 kg without recent changes; temperature, 36.7°C; blood pressure, 116/65 mmHg; and pulse, 80 beats/min, with a regular sinus rhythm. Physical examination was also performed, and the findings were as follows. Her skin was moist, the heart sounds were normal with no murmurs, the lungs were clear without rales, and the lower extremities showed no signs of edema. Neurological examination findings were normal. The patient rated her pain as 9-10/10 on VAS. Clinical

chemistry showed moderate hyponatremia (Na 125 mEq/L), hypo-osmolality (262 mOsm/kg), and hyperglycemia (fasting glucose, 176 mg/dL). Endocrine studies showed elevated ADH (1.6 pg/mL) and normal thyroid and adrenal gland function. Urinary sodium concentration was increased (56 mEq/L), and urinary osmolality was 410 mOsm/kg. Chest X-ray, electrocardiogram, and chest computed tomography findings upon admission were normal. The patient exhibited hyponatremia, plasma hypo-osmolality, inappropriate urinary concentration at some level of plasma hypo-osmolality, elevated urinary sodium excretion, and absence of other potential causes of plasma hypo-osmolality, which indicated SIADH. Pregabalin for severe pain was initially suspected as the cause of SIADH. As the patient’s pain remained uncontrolled, pregabalin treatment was continued. Figure 2 shows the patient’s clinical course. The patient was initially instructed to restrict water intake (750 mL/d) and take salt tablets (54 mEq/d). However, the sodium level decreased after duloxetine was added to the patient’s treatment for severe pain. The patient’s pain was slightly relieved after addition of duloxetine, but she still rated it as 8-9/10 on VAS. As the patient refused opioids, duloxetine was continued. On the sixth day, she had nausea and mild agitation possibly due to increased intracranial pressure, and hypertonic saline infusion was started to treat her worsening hyponatremia. On the eighth day, she underwent percutaneous balloon

kyphoplasty, a minimally invasive procedure intended to relieve pain. Postoperative rapid diuresis did not occur, and the sodium level was gradually corrected within 3 days. On the 10th day, the patient's pain was rated as 0-2/10 on VAS. After pain relief surgery, hyponatremia and other findings improved spontaneously (Figure 2). On the 11th day, duloxetine was discontinued. The sodium level during a 6-month follow-up was within the normal range, although the patient continued to take only pregabalin.

Discussion

SIADH is a clinical syndrome of euvoletic hyponatremia [6]. Our patient showed hyponatremia, plasma hypo-osmolality, inappropriate urinary concentration at some level of plasma hypo-osmolality, elevated urinary sodium excretion, and normal function of the thyroid and adrenal glands, which indicated SIADH [7].

Our case encompasses 2 main concerns. The first involves the pathogenesis of SIADH. ADH plays an important part in the development of SIADH. Abnormal release of ADH or enhanced action of ADH on the kidney induces SIADH. In our case, plasma ADH concentrations were measured with a radioimmunoassay kit (YAMASA Shoyu Corporation, Choshi, Japan) using a primary rabbit polyclonal antibody (interassay coefficient of variation [CV], 2.3-6.7%; intra-assay CV, 4.0-8.0%) and ADH was detectable in the setting of plasma hypo-osmolality, which suggested relative ADH elevation [8]. Given that hyponatremia in our patient worsened after treatment with duloxetine and pregabalin, yet it spontaneously resolved after pain relief surgery despite the patient continuing to take the medications, severe pain may stimulate ADH secretion. However, duloxetine and pregabalin may induce or worsen hyponatremia, more so in presence of predisposing factors like advanced age and pain. We cannot elucidate the mechanisms underlying the development of SIADH in the present case; however, the stimulation of hypothalamus, which is one of the pain modulation sites, might affect ADH secretion [9]. ADH secretion may also be increased by duloxetine through the stimulation of the serotonin and norepinephrine receptors in the hypothalamus [10,11]. Pregabalin-induced SIADH has rarely been reported, and the pathogenesis remains unknown [12]. However, measurement of ADH may be clinically of little value because plasma ADH is elevated in both hypovolemic and hypervolemic hyponatremia, and it might be difficult to measure accurately because of the difficulty of handling, storing, and assaying samples [6].

The second concern is the treatment strategy for SIADH associated with vertebral compressive fractures. Various treatment approaches for SIADH have been recommended in different countries and organizations, yet they lack strong evidence in support of their use [13]. Common treatment options include fluid restriction, the management of the underlying disorder, and the discontinuation of the offending medication, but some patients with SIADH require other options. Percutaneous balloon kyphoplasty may be a novel treatment option for SIADH associated with vertebral compression fracture. It not only rapidly reduced pain and disability in the current case but also improved severe pain-associated SIADH without adverse effects [3,4]. Percutaneous balloon kyphoplasty may offer an alternative to pain regimens consisting of drugs that may further worsen SIADH and hyponatremia.

Our experience centered on the perioperative management of a patient with SIADH-related hyponatremia who underwent pain relief surgery. A recent cohort study showed that preoperative hyponatremia was a prognostic marker for morbidity and mortality, but the effectiveness and safety of the intervention for preoperative hyponatremia have not yet been established [14]. However, a dynamic change in sodium level may increase the risk for several adverse outcomes such as postoperative pneumonia, renal failure, and central pontine myelinolysis [15]. Therefore, we carefully monitored the patient's sodium level to avoid overcorrection after surgery. Postoperative rapid diuresis did not occur, and the sodium level was gradually corrected within 3 days. SIADH induced by severe pain slowly resolved after pain relief surgery. This phenomenon might reflect the pathogenesis of SIADH induced by pain, which can stimulate ADH secretion. This case could help clinicians treat new-onset or worsening hyponatremia in patients with a vertebral compression fracture.

Conclusions

We report a case of SIADH associated with lumbar compression fracture in a patient who underwent balloon kyphoplasty for pain relief. In case of SIADH associated with a vertebral compression fracture, percutaneous balloon kyphoplasty might offer an alternative to pain regimens consisting of drugs that may further worsen SIADH and hyponatremia.

Conflict of Interests

None.

References:

1. Bartter FC, Schwartz WB. The syndrome of inappropriate secretion of antidiuretic hormone. *Am J Med*, 1967;42:790-806
2. Ellison DH, Berl T. The syndrome of inappropriate antidiuresis. *N Engl J Med*, 2007;356:2064-72
3. Lee JJ, Kilonzo K, Nistico A, Yeates K. Management of hyponatremia. *CMAJ*, 2014;186:E281-86
4. Garfin SR, Yuan HA, Reiley MA. New technologies in spine: Kyphoplasty and vertebroplasty for the treatment of painful osteoporotic compression fractures. *Spine (Phila Pa 1976)*, 2001;26:1511-15
5. Zhao G, Liu X, Li F. Balloon kyphoplasty versus percutaneous vertebroplasty for treatment of osteoporotic vertebral compression fractures (OVCFs). *Osteoporos Int*, 2016;27:2823-34
6. Cuesta M, Thompson CJ. The syndrome of inappropriate antidiuresis (SIAD). *Best Pract Res Clin Endocrinol Metab*, 2016;30:175-87
7. Verbalis JG, Goldsmith SR, Greenberg A, et al. Diagnosis, evaluation, and treatment of hyponatremia: Expert panel recommendations. *Am J Med*, 2013;126(10 Suppl. 1):S1-42
8. Tanaka S, Urakami M, Mizuno H, Togashi K. [Development of a RIA kit "YAMASA" for measuring plasma ADH concentrations.] *Igaku To Yakugaku*, 2015;72:1379-88 [in Japanese]
9. Dafny N, Dong WQ, Prieto-Gomez C, et al. Lateral hypothalamus: Site involved in pain modulation. *Neuroscience*, 1996;70:449-60
10. Kirby D, Harrigan S, Ames D. Hyponatraemia in elderly psychiatric patients treated with selective serotonin reuptake inhibitors and venlafaxine: A retrospective controlled study in an inpatient unit. *Int J Geriatr Psychiatry*, 2002;17:231-37
11. Iovino M, Steardo L. Effect of substances influencing brain serotonergic transmission on plasma vasopressin levels in the rat. *Eur J Pharmacol*, 1985;113:99-103
12. Jung YJ, Lee DY, Kim HW, et al. A case report of syndrome of inappropriate antidiuretic hormone induced by pregabalin. *Electrolyte Blood Press*, 2016;14:31-34
13. Verbalis JG, Grossman A, Höybye C, Runkle I. Review and analysis of differing regulatory indications and expert panel guidelines for the treatment of hyponatremia. *Curr Med Res Opin*, 2014;30:1201-7
14. Leung AA, McAlister FA, Rogers SO Jr, et al. Preoperative hyponatremia and perioperative complications. *Arch Intern Med*, 2012;172:1474-81
15. Feinstein AJ, Davis J, Gonzalez L, et al. Hyponatremia and perioperative complications in patients with head and neck squamous cell carcinoma. *Head Neck*, 2016;38:E1370-74