

Moderate hemoptysis caused by Hughes-Stovin syndrome

Sahar El Aoud, Faten Frikha, Mouna Snoussi, Zouhir Bahloul

Department of Internal Medicine, Hedi Chaker Hospital, Sfax, Tunisia

Abstract

Hughes and Stovin first reported a syndrome consisting of multiple pulmonary artery aneurysms and venous thrombosis in 1959. Here, we encountered a 42-year old woman who had hemoptysis revealing a Hughes-Stovin syndrome. Helical computed tomography showed multiple pulmonary artery aneurysms with pulmonary thromboembolism. The patient was treated with steroid therapy, cyclophosphamide and anticoagulation with a good response.

Introduction

Hughes-Stovin syndrome (HSS) is an exceedingly rare disorder of unknown etiology. It is characterized by the combination of multiple pulmonary artery aneurysms (PAA) and deep venous thrombosis often involving the vena cava.^{1,3} Many investigators consider it as an incomplete form of Behçet disease (BD). PAA sometimes results in hemoptysis and/or hemoptum. We present a case of a 42-year old woman having hemoptysis with multiple pulmonary artery aneurysms, unusual pulmonary arterial embolism, and oral ulcers.

Case Report

A 42-year old woman, with previously healthy status, was admitted to our internal department for fever, weakness, dyspnea and iterative hemoptoic sputums. Her fever began 2 months previously and showed an irregular pattern, not responsive to antipyretic medications. Minor hemoptysis began and increased gradually in 1 week's duration before her hospitalization. She denied taking any drug that might predispose to bleeding. She had been suffering from oral aphthous ulcers for 5 years ago. There was no history of genital ulcerations, arthralgias, skin rash, or ocular disease suggestive of BD.

The patient was febrile. She had a blood pressure of 130/80 mmHg, a pulse of 120 beats/min and a respiratory rate of 18

breaths/min. Physical examination revealed also oral aphthous ulceration but no genital scars due to healed ulcers. Ophthalmological exam was normal. There were no suggestive signs for deep venous thrombosis.

Breath sounds were diminished over the left anterior and lateral areas of the chest, auscultation revealed inspiratory crackles. The pathergy test was negative.

Laboratory analysis showed a white blood cells count at 31,000 cells/mL with 85% neutrophils, a hemoglobin value at 10.8 g/dL, and a platelet count at 570,000 cells/mL. The erythrocyte sedimentation rate was over 111 mm/hour and the C-reactive protein was at 30 mg/L. Creatinine, electrolyte levels, liver tests, and coagulation studies were within normal range. An arterial blood gas determination performed showed a PaO₂ of 111 mmHg, PaCO₂ of 53 mmHg, and a pH of 7.34.

The admission chest radiograph demonstrated bilateral opacities with different diameter sizes in the lower lobes.

A contrast enhanced computed tomography (CT) of the thorax disclosed multiple pulmonary aneurysms with mural thrombosis filling from the upper lobe pulmonary artery branch, the largest was 9x8x7 mm of diameter, and thromboembolism of the left pulmonary artery (Figure 1).

All serologic markers were negative and no microorganisms could be identified from her blood, urine, and sputum cultures. The hemagglutination test for *Treponema pallidum*, and tests for human immunodeficiency virus, hepatitis B surface antigen, tuberculosis, *Rickettsia*, *Aspergillus*, and *Candida albicans* were all negative.

Coagulation studies were normal (prothrombin time, partial thromboplastin time, antithrombin III, protein C activity, protein S activity, activated protein C resistance ratio).

Immunological analysis including antinuclear antibodies, rheumatoid factor and antineutrophilic cytoplasmic antibodies were also within the referential range. Human lymphocyte antigen B5 was also negative.

Thereafter, she did not fulfill the diagnostic criteria of the complete BD. Finally, a rare diagnosis of systemic vasculitis, HSS was made on the basis of multiple pulmonary artery aneurysms and pulmonary thrombi in such a young patient.

The patient was treated with low-molecular-weight heparin, the appropriate oral anticoagulant therapy (with optimal therapeutic international normalized ratio range between 2 and 3). A high-dose regimen of prednisone (1 mg/kg/day) and monthly bolus of cyclophosphamide were started (1 g/month for a total of 12 bolus). Coil embolization of the aneurysm was not performed because there was no massive hemoptysis.

Thenceforward, she was afebrile with eup-

Correspondence: Faten Frikha, Department of Internal Medicine, Hedi Chaker Hospital, 3029 Sfax, Tunisia.

E-mail: fetenfrikha@yahoo.fr

Key words: Hughes-Stovin syndrome, aneurysms, thrombosis.

Conflict of interest: the authors have no conflict of interest.

Contributions: the authors contributed equally.

Received for publication: 7 May 2014.

Revision received: 6 August 2014.

Accepted for publication: 7 August 2014.

This work is licensed under a Creative Commons Attribution NonCommercial 3.0 License (CC BY-NC 3.0).

©Copyright S. El Aoud et al., 2014
Licensee PAGEPress, Italy
Clinics and Practice 2014; 4:647
doi:10.4081/cp.2014.647

neic respiratory rhythm and no further hemoptysis. Two months later, in the control chest CT, the aneurysms except the ones at the lower lobe were all regressed with disappearance of aneurysm mural thrombosis (Figure 2).

The complaint was getting worse in a month before, accompanied by 1 episode of fever. Chest examination showed midscapular crackles. Chest-X-ray (Figure 3) and CT scan (Figure 4) revealed a left midzone cavitory lesion. *Aspergillus* antibodies and antigens were negative. Sputum smear for acid-fast bacilli (AFB) was negative so was the culture of sputum for AFB.

The culture-sensitivity examination of bronchoalveolar lavage was positive for *C. albicans*. The patient was diagnosed with pulmonary candidiasis. She received treatments with cefotaxim 3 g once daily, fluconazole 200 mg per day for 14 days with a good response.

After one year of follow up and after a total of 12 bolus of cyclophosphamid, the patient is going well, without a recurrence of hemoptysis.

Discussion

In 1959, Hughes and Stovin reported four cases of deep venous thrombosis and multiple segmental pulmonary artery aneurysms.¹ Since then, this association of multiple pulmonary aneurysms and peripheral venous thrombosis has been named Hughes-Stovin syndrome⁴ and several cases have been published.²⁻⁶ There have been less than 50 published cases of HSS described in English med-

ical literature so far.⁷ It usually affects the young adult aged from 12 to 48 years and holds a strong predilection for the male gender^{4,8,9} with only 6 cases describing women.^{7,10-13} We report a case of a 42 year-old woman with the HSS in whom multiple pulmonary arterial aneurysms with an unusual pulmonary arterial embolism were found. To our knowledge, our patient is the seventh woman presenting this disease.

Etiopathogenesis of HSS remains largely obscure and a systemic vasculitis has been suggested.¹⁴ Septic embolisms, angiodysplasia of bronchial arteries, are another debatable hypothesis to account for the vascular changes.^{7,15} Actually, weakening of the arterial wall from the subsequent inflammation is the likely mechanism.³

Being an extremely rare disease, there are no formally described diagnostic criteria or pathognomonic laboratory investigations for this syndrome. Generally, the syndrome is characterized by the association of multiple pulmonary and/or bronchial aneurysms and thrombophlebitis.

Nearly 25% of patients with HSS develop vascular thromboembolism, arterial aneurysms, and arterial and venous occlusions with nonspecific vasculitis. The vascular lesions are arterial in 7%, venous in 25%, and both in 68% of reported cases.¹⁰ Reports indicate that pulmonary lesions and deep venous thrombosis of the lower extremities are the most frequent findings.¹⁰ Aneurysms may be single or multiple, unilateral or bilateral. It is rarely multiple or bilateral. Aneurysms at other anatomic locations (iliac, femoral, popliteal, carotid and hepatic arteries) have also been described in HSS. Peripheral venous thrombosis may affect vena cavae, jugular veins, iliac veins, femoral veins, hepatic veins, cerebral venous sinuses or even the cardiac chambers.¹⁵ Our patient has multiple pulmonary artery aneurysms associated with embolism of the left pulmonary artery without peripheral deep vein thrombosis.

The typical presentation of HSS involves in 3 phases: a first stage involving symptoms of thrombophlebitis, a second stage consisting of formation and enlargement of pulmonary aneurysms, and a third stage of aneurysmal rupture that triggers massive hemoptysis, leading to death.⁹ The main clinical features of the syndrome can be non-specific including cough, dyspnea and fever. Hemoptysis may be a late sequela of disease progression, thus making early diagnosis a challenge.⁵

Chest radiography may reveal round opacities and hilar enlargement. Helical computed tomography (HCT) and magnetic resonance imaging have been reported as non-invasive method useful for the diagnosis of PAA. They may demonstrate high quality vascular images with more sensitivity of HCT in the

detection of small aneurysms.⁵ Pulmonary angiography should be avoided because of the potential of aneurysm formation.

Two types of vasculitis have commonly been associated with PAA: BD and HSS. So that, the main differential diagnosis of the HSS is BD; a multisystem disorder, that at onset, may present with PAA, which is scarce; usually around 1.5%.¹⁶ Several authors suggested that HSS is a variant or an incomplete presentation of BD owing to their similar clinical, radiological and histopathological findings.¹⁵ In fact, HSS might be a cardiovascular manifestation of BD or the incomplete type of BD (isolated pulmonary presentation of BD with the inflammatory vascular component but lacking some of the other clinical manifestations like oral and genital ulceration, skin lesions, and uveitis).

On the other hand, arterial involvement in BD was expressed by aneurysms that can involve all arterial territories with a preference for the pulmonary arteries (HSS).^{11,17} Takayasu arteritis can also involve the pulmonary arteries; however, more commonly, it produces pulmonary artery narrowing and occlusion rather than dilation.

There are also reports of mycotic pulmonary artery aneurysms resulting from *Mycobacterium tuberculosis*, and from fungi, such as *Mucormycosis*, *Aspergillus*, and *Candi-*

da.¹⁵ Therefore, these infectious etiologies should be eliminated before thinking about systemic diseases such as the case of our patient.

Owing to the lack of controlled trials, there are no standard treatment guidelines for HSS and various treatment modalities have been described in the management of this disease. These include immunosuppression with systemic corticosteroid and cytotoxic agents (cyclophosphamide),⁷ used most commonly in

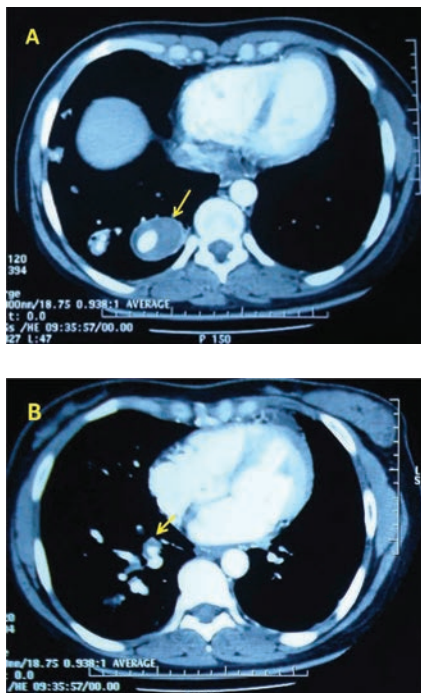


Figure 1. A and B) Contrast enhanced computed tomography of the thorax axial section showing multiple pulmonary aneurysms (arrows in A and B) with mural thrombosis filling from the upper lobe pulmonary artery branch.

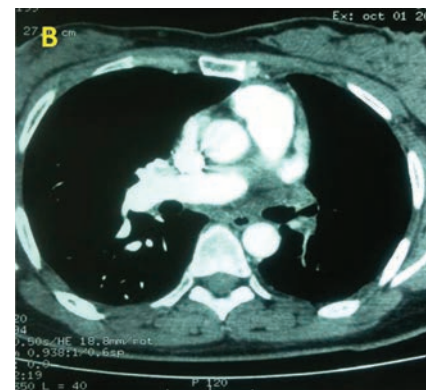
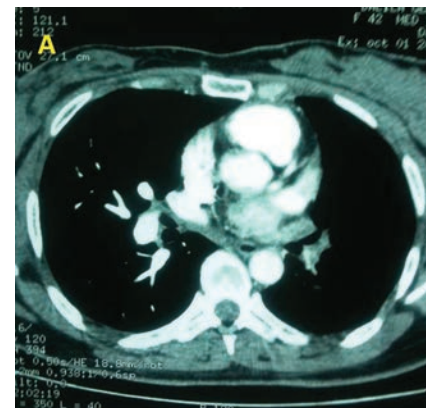


Figure 2. A and B) Contrast enhanced computed tomography. Control after 2 months of treatment: the aneurysms except the ones at the lower lobe were all regressed with disappearance of aneurysm mural thrombosis.

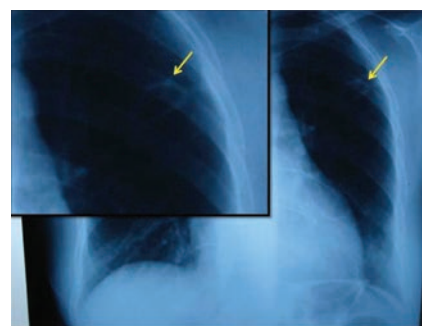


Figure 3. Chest-X-ray revealing a left mid-zone cavitory lesion (arrow).

the treatment of the early stages of the disease. This therapy confers clinical improvement, stabilization and even regression of small pulmonary artery aneurysms in most patients.⁵

Anticoagulation is generally contraindicated due to an increased risk of fatal hemorrhage. However, it may be employed with great vigilance in a few carefully evaluated circumstances where the benefits are believed to significantly outweigh the risks.¹⁵ A therapeutic dilemma is often posed in using anticoagulants if pulmonary embolism is present. Anticoagulation may prevent the progression of pulmonary embolism and resolve vein thrombi. Our patient benefited of anticoagulation because of thromboembolism of the left pulmonary artery and the aneurysm mural thrombosis.

For patients with extensive, bilateral multi-

focal aneurysms and/or severe or recurrent hemoptysis arterial embolization has been suggested as the treatment modality choice.^{7,15} Surgical treatment (lobectomy or pneumonectomy) is reserved for some cases complicated by massive hemoptysis due to a large pulmonary aneurysm but with associated high morbidity and mortality.⁵

Our patient described in this report, was treated with immunosuppression with both cyclophosphamide and prednisone with favorable outcome. She has remained free of pulmonary artery aneurysms and hemoptysis after 12 months of follow-up.

Conclusions

HSS is a rare but grave clinical entity and has not been extensively studied so far. The cause of this entity is currently unknown. Our patient presented a particular clinical presentation of HSS, which should be kept in mind in the differential diagnosis of pulmonary involvement of BD. It seems that the most convenient method of imaging is angio-CT scan. Early detection and treatment is mandatory to save the patient's life.

References

1. Hughes JP, Stovin PG. Segmental pulmonary artery aneurysms with peripheral venous thrombosis. *Br J Dis Chest* 1959;53:19-27.
2. Tzilalis VD, Vourliotakis G, Tsironis IA, et al. Use of an amplatzer vascular plug in embolization of a pulmonary artery aneurysm in a case of Hughes-Stovin syndrome: a case report. *J Med Case Rep* 2011;5:425.
3. Choh NA, Jehangir M, Mir KM, et al. Hughes-Stovin syndrome: a rare cause of hemoptysis. *Lung India* 2011;28:285-6.
4. Weintraub JL, DeMayo R, Haskal ZJ, Susman J. SCVIR annual meeting film panel session: diagnosis and discussion of case 1. *J Vasc Interv Radiol* 2001;12:531-4.

5. Lee J, Noh JW, Hwang JW, et al. Successful cyclophosphamide therapy with complete resolution of pulmonary artery aneurysm in Hughes-Stovin syndrome patient. *Clin Rheumatol* 2008;27:1455-8.
6. Chalazonitis AN, Lachanis SB, Mitseas P, et al. Hughes-Stovin syndrome: a case report and review of the literature. *Cases J* 2009;2:98.
7. Curci N E, Bilfinger TV. Successful multimodality treatment of a young woman with Hughes-Stovin syndrome. *Am Surg* 2012;78:E304-5.
8. Grembiale RD, Calderazzo M, Pelaia G, et al. A case of Hughes-Stovin syndrome associated with Budd-Chiari syndrome. *Case Rep Clin Pract Rev* 2002;3:92-4.
9. Khalil A, Parrot A, Fartoukh M, et al. Images in cardiovascular medicine. Large pulmonary artery aneurysm rupture in Hughes-Stovin syndrome: multidetector computed tomography pattern and endovascular treatment. *Circulation* 2006;114:e380-1.
10. Al-Jahdali H. Massive hemoptysis and deep venous thrombosis presenting in a woman with Hughes-Stovin syndrome: a case report. *J Med Case Rep* 2010;4:109.
11. Kinjo M, Tanaka K, Ishimaru S, et al. Hughes-Stovin syndrome. Report of a female autopsy case and review of the literature. *Acta Pathol Jpn* 1978;28:335-44.
12. Amezyane T, Bassou D, Abouzahir A, et al. Unusual right ventricular thrombus in a woman with Hughes-Stovin syndrome. *Intern Med* 2010;49:207-8.
13. Kindermann M, Wilkens H, Hartmann W, et al. Images in cardiovascular medicine. Hughes-Stovin syndrome. *Circulation* 2003;108:e156.
14. Ketchum ES, Zamanian RT, Fleischmann D. CT angiography of pulmonary artery aneurysms in Hughes-Stovin syndrome. *AJR* 2005;185:330-2.
15. Khalid U, Saleem T. Hughes-Stovin syndrome. *Orphan J Rare Dis* 2011;6:15.
16. Yilmaz S, Cimen KA. Pulmonary artery aneurysms in Behçet's disease. *Rheumatol Int* 2010;30:1401-3.
17. Francois MF. Is Hughes-Stovin syndrome a particular expression of Behçet's disease? *Chest* 1983;83:288.

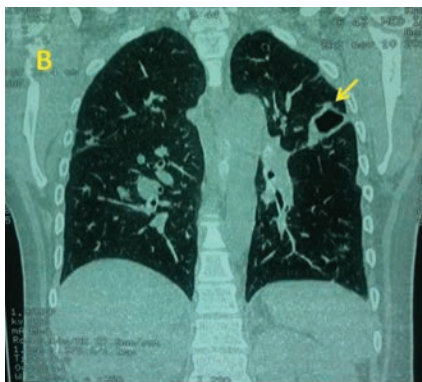
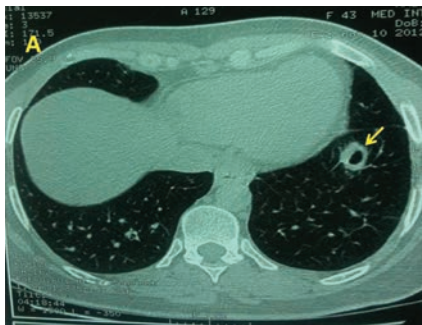


Figure 4. A and B) Computed tomography scans of thorax showing a left midzone cavitory lesion (arrow).