



Prosthetic Breast Reconstruction With Acellular Dermal Matrices: Achieving Predictability and Reproducibility

Maurice Y. Nahabedian, MD,
FACS

Summary: The use of acellular dermal matrices in the setting of prosthetic breast reconstruction has captured the attention of many plastic surgeons. The regenerative capacity of these materials has provided additional tissue support to the mastectomy skin flaps with the ultimate result of improving surgical and aesthetic outcomes. Despite the benefits, there remains a significant diversity with regard to outcomes with some surgeons reporting increased morbidity. The reasons for this are varied but ultimately related to differences in patient selection and surgical techniques. The purpose of this article is to provide strategies for using acellular dermal matrix to achieve success in a manner that is usually associated with outcomes that are predictable and reproducible. (*Plast Reconstr Surg Glob Open* 2016;4:e698; doi: 10.1097/GOX.0000000000000459; Published online 4 May 2016.)

For many surgeons, the use of acellular dermal matrix (ADM) has revolutionized the process of prosthetic breast reconstruction. The reasons for this include tissue support, elasticity, reduced scar formation, pectoralis major stabilization, and device compartmentalization.¹ ADM's use, however, is not associated with widespread acceptance because outcomes seem to vary from surgeon to surgeon. Some surgeons report excellent aesthetic outcomes with low complication rates, whereas others report increased morbidity and reconstructive failure. The reasons for this are variable but may be the result of differences in technique and patient selection criteria.

The purpose of this article is to review a single surgeon's experience with >700 prosthetic breast reconstruction procedures using ADM since 2005.

From the Department of Plastic Surgery, Georgetown University, Washington, DC.

Received for publication May 18, 2015; accepted June 25, 2015.

Copyright © 2016 The Authors. Published by Wolters Kluwer Health, Inc. on behalf of The American Society of Plastic Surgeons. All rights reserved. This is an open-access article distributed under the terms of the Creative Commons Attribution-Non Commercial-No Derivatives License 4.0 (CCBY-NC-ND), where it is permissible to download and share the work provided it is properly cited. The work cannot be changed in any way or used commercially.

DOI: 10.1097/GOX.0000000000000459

The goal is to review many of the salient factors that are ultimately related to achieving predictable and reproducible outcomes. The techniques and recommendations described are based on personal experience, personal observation, and evidence-based medicine.

PATIENT SELECTION

The increased use of ADM in the United States has been associated with a shift in our patient selection algorithms.^{2,3} Traditionally (before ADM), patients considered good candidates for prosthetic reconstruction were typically thin [body mass index (BMI) < 30 kg/m²] with small breast volumes. As surgeons became more adept at the ADM techniques, larger breasts were being reconstructed with prosthetic devices and ADM.⁴ Although successful from a technical perspective, adverse events such as infection, seroma, and delayed healing became more frequent and reconstructive failure became more common.

Our current algorithm for immediate reconstruction using prosthetic devices and ADM has been substantially modified. Women with a BMI <30 kg/m² are usually good candidates, women with a BMI rang-

Disclosure: Dr. Nahabedian is a consultant for LifeCell. No assistance was obtained in preparation of this manuscript. The Article Processing Charge was paid by LifeCell.

ing from 30 to 39 are individualized, and women with a BMI >40 kg/m² are discouraged from immediate reconstruction because outcomes are generally suboptimal and complications such as seroma, compromised healing, and infection are more frequent.⁵ Alternatives include delayed reconstruction with prosthetic or autologous techniques and/or weight loss to reduce the complication rate. When immediate prosthetic reconstruction in a high-risk patient is performed, total muscle coverage without ADM should be considered.⁶

Other factors related to patient selection include tobacco use and diabetes mellitus.⁷⁻⁹ Tobacco use is associated with poor perfusion, delayed healing, reconstructive failure, and increased rates of reoperation.^{7,8} Nicotine and carbon monoxide are associated with delayed healing and wound-related complications. It is recommended that patients be free of tobacco products for 1 month before surgery and for 2 weeks after surgery. By avoiding tobacco, wound-related complications could be reduced as much as 3-fold from 23.5% to 7.7%.⁸ In patients who continue to smoke, the typical recommendation is to proceed with the mastectomy but refrain from proceeding with immediate breast reconstruction.

Poorly controlled diabetes mellitus is a well-known factor that is associated with compromised healing.⁹ Hyperglycemic states can interfere with normal wound healing and can contribute to increased rates of incisional dehiscence, soft tissue infection, and increased rates of soft tissue infection. In diabetic patients, serum glucose should be <200, there should be no glucose in the urine, and hemoglobin A1c should be <7. Elevated levels may be an indication to defer immediate breast reconstruction. The effects of adjuvant and neoadjuvant chemotherapy can also delay healing when administered too early.¹⁰ It is recommended to wait approximately 1 month after chemotherapy or until cell counts have normalized before proceeding with reconstruction.

MASTECTOMY SKIN FLAPS

It is widely accepted that predictable and aesthetically pleasing reconstructive outcomes are more likely to occur in patients with well-perfused mastectomy skin flaps (Fig. 1). Excessively thin mastectomy skin flaps or widely undermined skin flaps are often associated with poor vascularity, a deficiency of fat, a greater likelihood of tissue necrosis, and ultimately reconstructive failure, reoperation, and poor outcome.¹¹ Thus, it is important for breast surgeons and plastic surgeons to communicate and ensure that the mastectomy is performed with the intent of optimizing thickness and vascularity without compromising oncologic integrity. Larson et al¹² have demonstrated

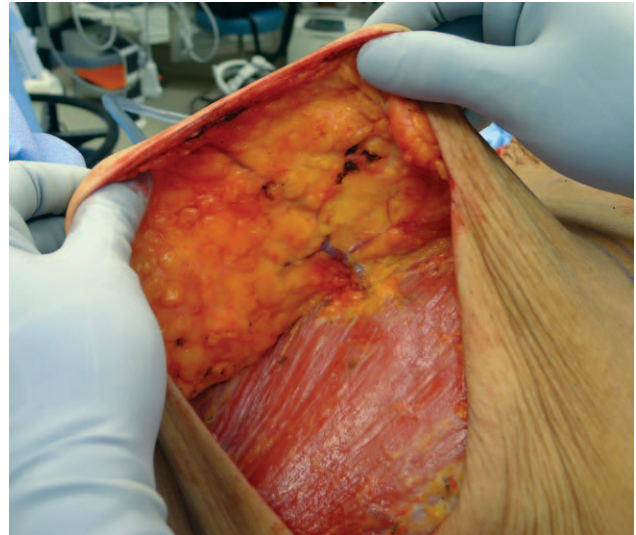


Fig. 1. A preserved internal mammary perforator to the medial mastectomy skin envelope to maintain vascularity.

that the subcutaneous layer of the breast ranges in thickness from 1–2 mm to 3 cm.

Mastectomy techniques to enhance the likelihood of optimizing perfusion and thickness include sharp dissection and minimal use of electrocautery. Proper retraction of the soft tissues to avoid excessing pressure and tension on the vulnerable mastectomy skin flaps is important. Breast surgeons should identify the investing fascia of the breast parenchyma and remain in this dissection plane rather than skeletonizing the skin down to the level of the subdermal plexus. Adherence, revascularization, and recellularization of ADM are dependent on adequate vascularity of the recipient bed. When the perfusion or viability of the mastectomy skin flap is questionable, fluorescent angiography is considered.¹³ When perfusion is deemed inadequate, surgical debridement of the skin is considered. Alternatives include total muscle coverage of the device, autologous reconstruction, or delayed reconstruction.

The ideal mastectomy includes a meniscus of subcutaneous fat along the sternal border and the inframammary fold. The thickness should approximate 1 cm, but this may vary depending on the tumor location and characteristics. Excessively thick mastectomy skin flaps are usually defatted to a thickness of 1 cm because they otherwise may become indurated during wound healing. Mastectomy may be skin or nipple sparing.¹⁴ Skin-sparing mastectomy is typically performed along the axis of the nipple-areolar complex. The orientation of the excision may be transverse, oblique, or vertical. In women with moderate to severe mammary hypertrophy, an inverted T mastectomy can be considered. Nipple-sparing mastectomy is commonly performed via an inframammary approach or a transverse

areolar approach. The incision is typically 6–8 cm in length, ensuring a complete mastectomy and providing adequate access to the mastectomy space for the prosthetic reconstruction using ADM (Fig. 2). Gentle retraction is recommended to minimize trauma and spasm to the subdermal plexus of vessels. Laterally based incisions are sometimes created in a sigmoid fashion rather than linear to minimize lateral displacement of the NAC (Fig. 3). Laterally based incisions should terminate at the areolar-skin junction. Supra- and infra-areolar incisions will occasionally result in mild and superficial areolar necrosis (Fig. 4).

DEVICES

Many surgeons in the United States perform prosthetic reconstructions in 2 stages using a tissue expander followed by a permanent implant. Tabbed tissue expanders have become common during the first stage because of the ability to define the footprint of the new breast.^{15,16} The inferior tabs are sutured to the chest wall at the desired location along the inframammary fold (Fig. 5). The medial aspect of the tissue expander should be positioned as medial as possible without detaching the medial fibers of the pectoralis major muscle. The sutures prevent migration of the devices and reduce the need for the ADM to compartmentalize the device.¹⁵ Thus, the primary purpose of the ADM is to provide tissue support inferiorly and laterally. This tends to ensure optimal adherence of the ADM along the lateral and inferior mastectomy skin flaps, creating a well-defined pocket for the permanent implant with less lateral and inferior migration.

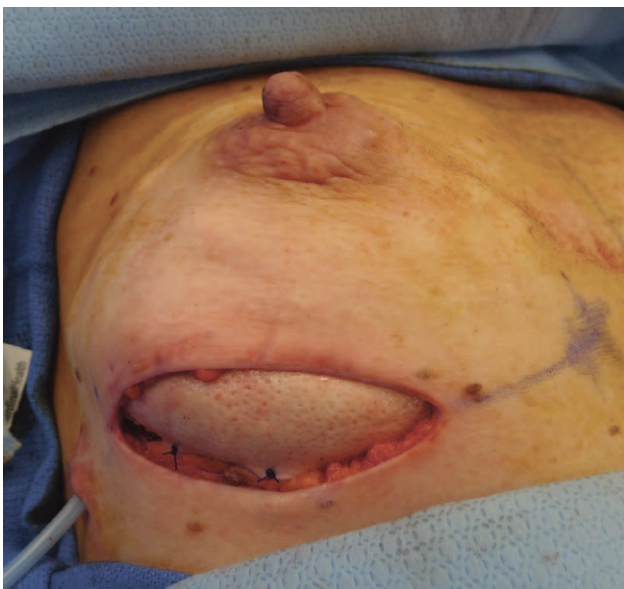

Fig. 2. The inframammary approach to nipple-sparing mastectomy using ADM for tissue support.

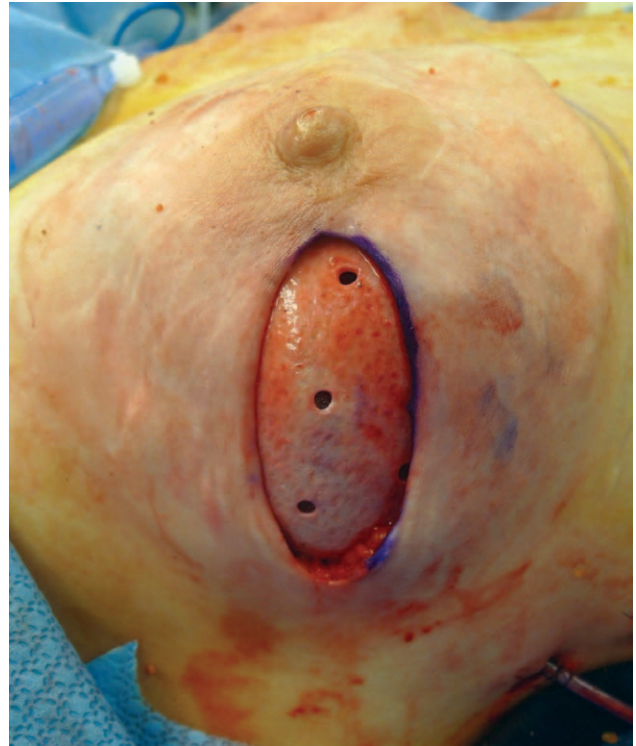

Fig. 3. The lateral mammary approach to nipple-sparing mastectomy using ADM for tissue support.

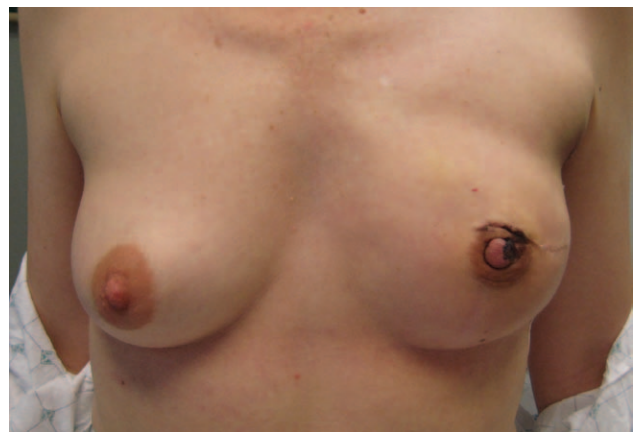

Fig. 4. Periareolar extensions of the lateral mammary incision can result in superficial nipple-areolar necrosis.

In women having direct to implant reconstruction, there is a greater reliance on the ADM to compartmentalize the implant and to prevent inferior or lateral migration.¹⁷ In these patients, the authors' preference is to first use a silicone gel sizer to determine the ideal location and position of the lateral border of the periprosthetic space. The ADM is sized appropriately based on the dimensions of the selected implant and sutured securely to the inferior edge of the pectoralis major muscle and the inferior and lateral chest wall at the predetermined inframa-

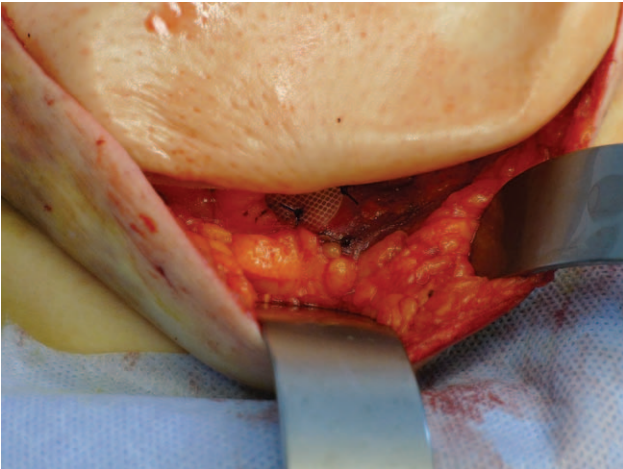


Fig. 5. Tabbed tissue expanders can stabilize the position of the device and prevent migration.

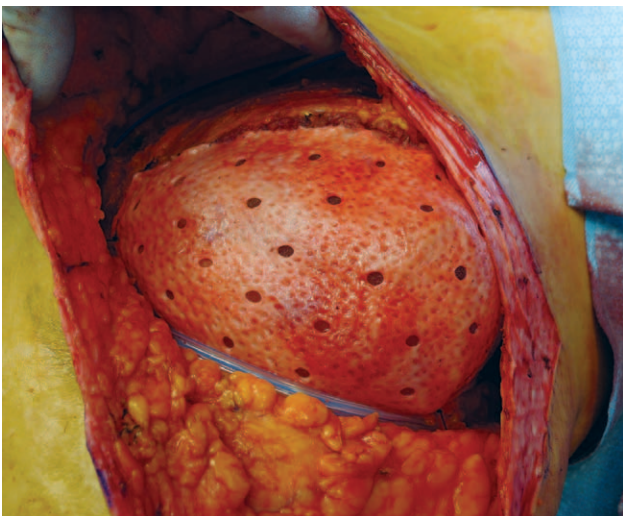


Fig. 6. Perforated ADM can permit bidirectional movement of fluid and minimize the incidence of seroma and improve tissue adherence.

mmary and lateral mammary folds using absorbable monofilament sutures.

ACELLULAR DERMAL MATRIX

ADM is arguably one of the most important components of prosthetic reconstruction. The purpose of this section is to provide salient technical details based on the authors' experience rather than dictate which ADM to use. In general, sterile ADMs are preferred to reduce the rate of infection.^{18,19} Human ADM is preferred because of the inherent elasticity of human skin. Perforated ADM is preferred to minimize the risk of seroma formation and to promote zones of adherence that can promote better incorporation (Fig. 6). Thin sheets of ADM in the range of 1–1.5 mm in thickness are preferred as this may

facilitate more rapid incorporation, adherence, and revascularization.

When the ADM is removed from the packaging, recommendations include minimal handling and treatment as a sterile device. All ADMs require some degree of soaking when removed from the package. Freeze-dried ADMs typically require 20–30 minutes, whereas the prehydrated materials are usually soaked for 5 minutes. The added benefit of soaking is to remove any preserving materials or antibiotics that are included in the packaging. Some of these additives may be responsible for the development of “red breast syndrome” that is typically located along the cutaneous distribution overlying the ADM.¹⁸ The techniques for ADM use emphasized in the ensuing paragraphs will be based on partial muscle coverage rather than on prepectoral coverage.

The technical aspects of ADM use are an important determinant of a good to excellent outcome. Most ADMs are available in a rectangular or a contoured/crescent form. The ADM should be trimmed appropriately such that it fits the device essentially like a hand-in-glove (Fig. 6). The length should be sufficient to span the width of the device, and the height should be sufficient to stabilize and extend the inferior edge of the pectoralis major such that it is pulled down to at least the midheight of the device (Fig. 7). A high-riding pectoralis major muscle functions poorly and may create more distortion. The orientation of the ADM is important because most ADMs are usually polarized and have a dermal and basement membrane surface. The dermal surface should be in contact with the mastectomy skin flap to enhance soft tissue incorporation. The ADM can be positioned inferiorly and/or laterally depending on the tissue requirements. ADM is typical-

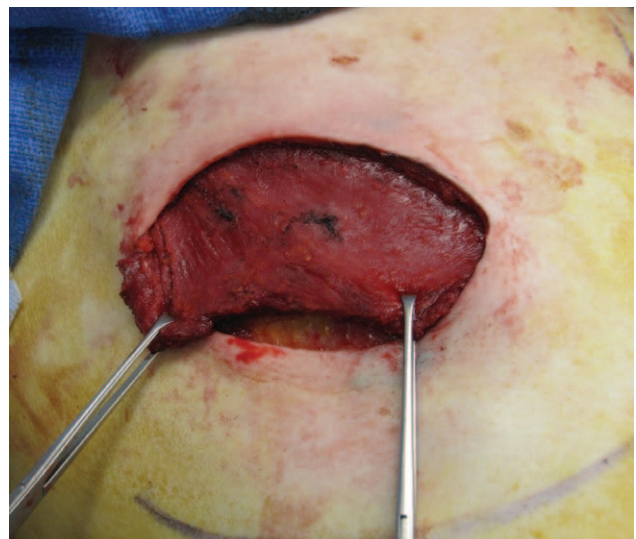


Fig. 7. The pectoralis major muscle is detached at its inferior insertion and elevated to create a subpectoral pocket.

ly sutured to the inferior edge of the pectoralis major muscle first, pulled inferiorly to determine the optimal position of the pectoralis major muscle, trimmed inferiorly and laterally as needed, then sutured to the inframammary fold (Figs. 8–10). The preferred suture is a continuous or interrupted 2-0 monofilament absorbable. Tightly inset ADM will tend to elevate the position of the device and elevate the footprint of the reconstructed breast mound; therefore, the ADM should be somewhat lax, especially medially, to permit optimal expansion of the device without compression. With expansion, the folds and laxity of the ADM will promote optimal expansion. The initial expansion is typically limited to 40–60% of the tissue expander capacity to minimize compression of the subdermal plexus of vessels. Compression may lead to vascular occlusion and delayed healing or tissue necrosis. With robust skin flaps, the degree of expansion can be increased or a direct to implant reconstruction can be considered. The expanded ADM should be without folds or ripples to ensure 100% contact with the mastectomy skin flap, minimize dead space, and lessen the likelihood of a fluid collection or poor adherence (Fig. 6). During final skin closure, the mastectomy incision and/or nipple-areolar complex should ideally be over muscle and not ADM; however, it is not an absolute requirement.

MAMMARY HYPERTROPHY

Mammary hypertrophy in and of itself is not a contraindication to prosthetic breast reconstruction

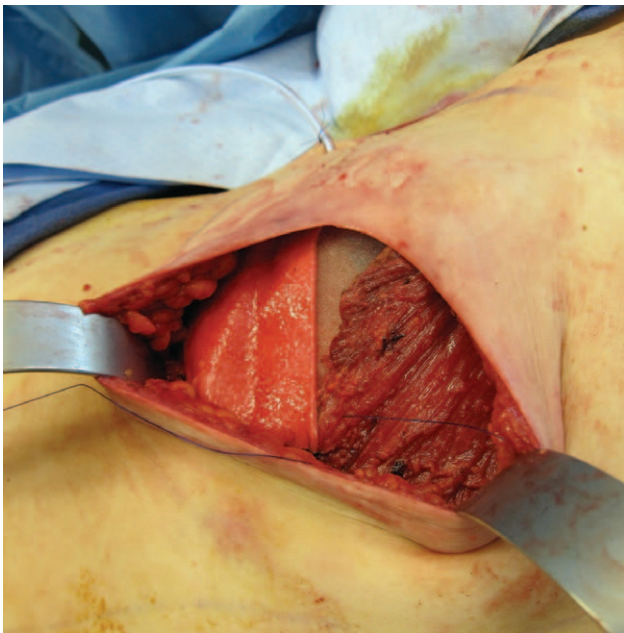


Fig. 8. The inferior edge of the pectoralis major is sutured to the upper edge of the ADM with a running absorbable monofilament suture.

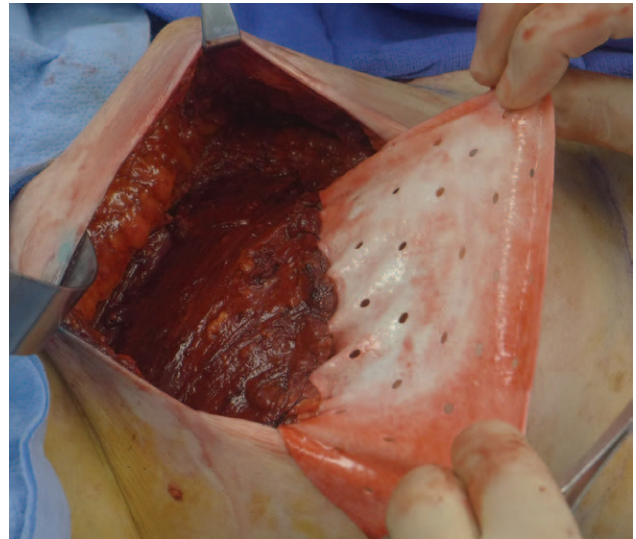


Fig. 9. The muscle-ADM complex is pulled inferiorly and redraped over the device.

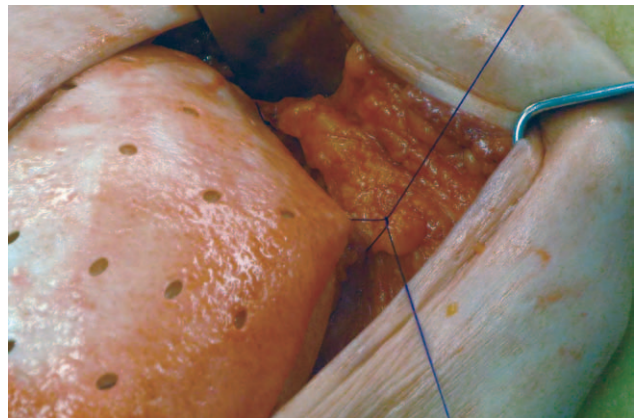


Fig. 10. The inferior edge of the ADM is sutured to the superficial fascia at the level of the desired inframammary fold.

using ADM; however, there are several strategies that one should consider to increase the likelihood of a successful outcome. Most women with mammary hypertrophy will have skin-sparing or traditional mastectomy because nipple sparing is usually not an option. The mastectomy can be performed via the inverted T incision, Passot (horizontal only incision), or extended transverse/oblique skin excision pattern.^{20,21} Skin redundancy should be minimized as much as possible; otherwise, the skin flaps will tend to fold upon themselves becoming painful and more difficult to correct at the time of revision.

After the mastectomy, the device and the ADM are inserted as previously described (Fig. 6). Once the tissue expander has been optimally filled or the permanent implant placed and secured with ADM, the skin envelope is addressed. In the setting of an invert T incision, the skin flaps are redraped over

the breast mound and the skin flaps debrided as necessary to provide a tension-free closure without skin redundancy. In the setting of a transverse or oblique incision, there is usually skin redundancy medially and laterally (Fig. 11). For medial excess, the tailor tack method is recommended to determine the amount of skin to de-epithelize (Fig. 12). After de-epithelialization, the dermis and subcutaneous fat is imbricated to provide additional soft tissue fill medially (Fig. 13). For lateral excess, the same principles and concepts are used. In the event that the medial or lateral tissues are poorly vascularized or too thin, they are typically excised rather than de-epithelized. It is not uncommon for these lateral incisions to extend to the anterior or midaxillary line. The goal of this maneuver is to create a breast mound that has optimal contour on the table; however, secondary contouring procedures are often necessary in these women.

Many women with mammary hypertrophy will have a wide breast with a wide base diameter. Device selection is usually based on the internal base diameter of the breast pocket after mastectomy. The exter-

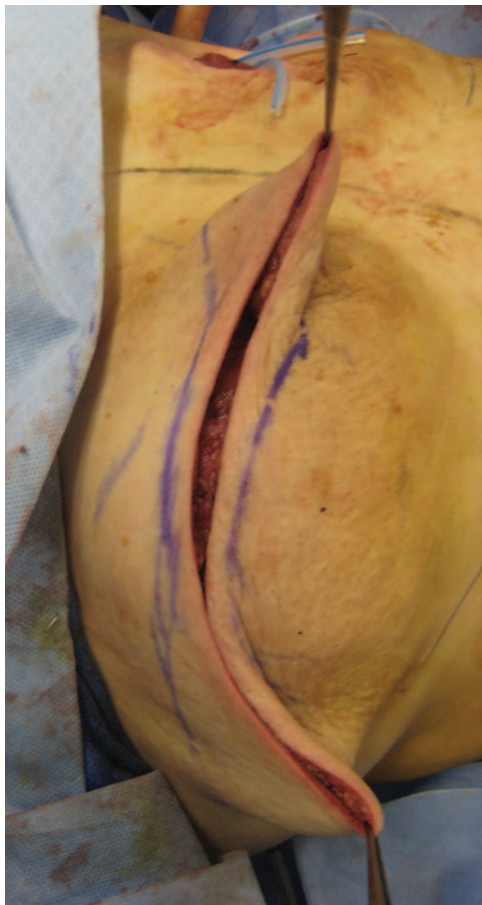


Fig. 11. The excess skin is assessed, delineated, and excised to avoid redundant skin.

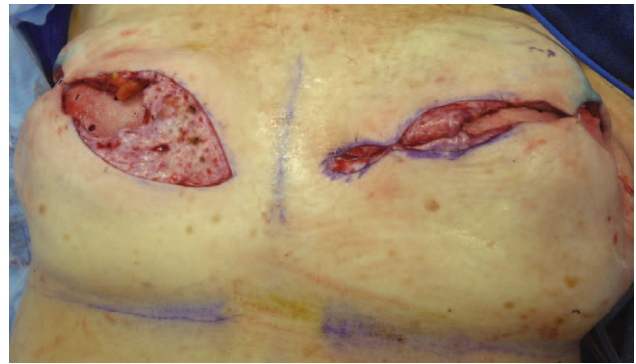


Fig. 12. The excess medial skin is de-epithelialized, imbricated, and sutured to provide additional medial volume and to minimize the degree of scalloping.

nal measurements in these patients are not usually reflective of the chest wall dimensions. Devices will typically extend from the sternal border to the anterior axillary line. After stage 1, many hypertrophic breasts will have a boxy appearance because of the increased breast width; however, this can be modified and corrected at the second stage using skin excision techniques and recontouring (Figs. 14, 15). Thus, the 2-stage technique is preferred in women with severe mammary hypertrophy to better define an optimal breast contour.

RADIATION

ADMs have the potential to integrate, recellularize, and revascularize in the setting of radiation; however, the time frame by which this occurs may be increased.²² These matrices have the potential to

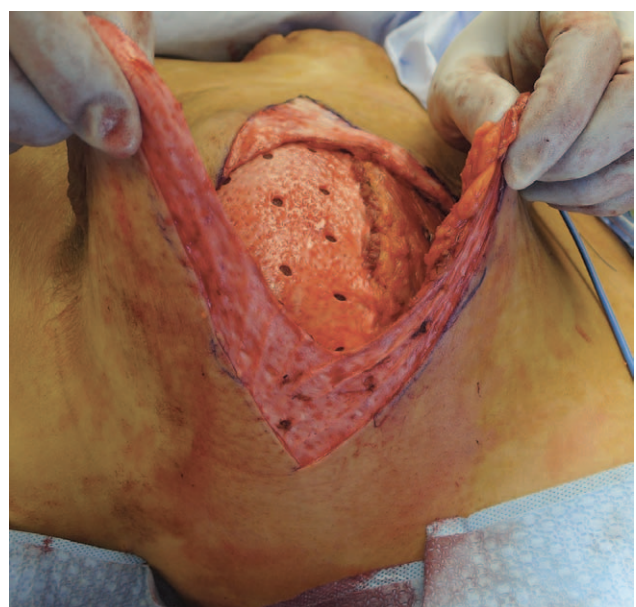

Fig. 13. The excess lateral skin is also de-epithelialized, imbricated, and sutured to provide lateral contour.

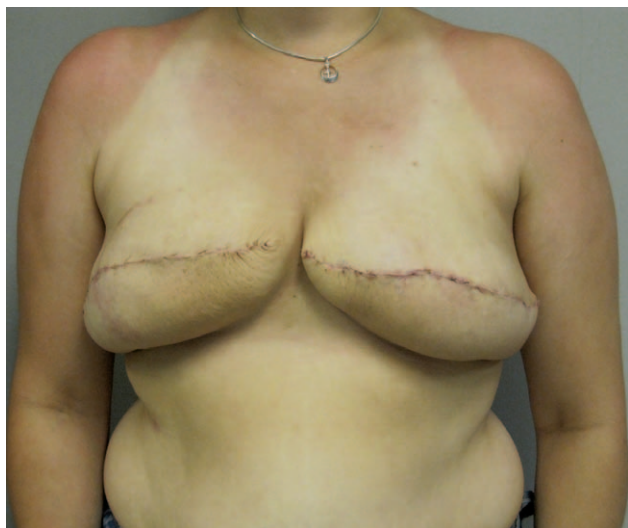

Fig. 14. After stage 1 in a woman with a wide breast, the breast will sometimes assume a boxy appearance.

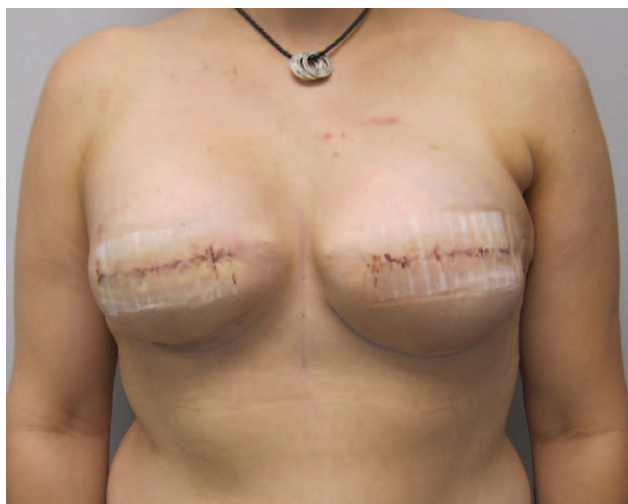

Fig. 15. After stage 2, the boxy contour can be revised to achieve a more natural contour.

improve capsular contracture when used as a secondary lining after capsular excision; however, ADM may be less effective in preventing capsular contracture in the setting of immediate placement and subsequent radiation therapy. The postulated mechanism by which ADM works to minimize capsular contracture is much like that of a full-thickness skin graft in its ability to reduce wound contraction and to minimize the spherical contractile process when used as an interposition.

IRRIGATION, ANTIBIOTIC, AND DRAIN PROTOCOLS

The importance of adequate irrigation protocols with prosthetic reconstruction and ADM cannot be

overemphasized. Many surgeons will use a triple antibiotic solution consisting of Ancef, bacitracin, and gentamicin.²³ An alternative solution is a 50% povidone-iodine solution that is equally as effective as the triple antibiotic solution and is usually used to irrigate the ADM and pocket. When povidone-iodine is used, contact with the device should be limited to the external surface and should be rinsed off within 5 minutes.

Antibiotic regimens are important considerations during the perioperative period.^{24–27} The Surgical Care Improvement Project (SCIP) has dictated many of the current protocols and recommended minimizing postoperative antibiotics to 24 hours. Although uniform consensus with preoperative antibiotics has been achieved, there is controversy regarding postoperative antibiotic administration.²⁸ Many surgeons will deliver a preoperative dose of 1–2 g cephalosporin or equivalent antibiotic. Most cancer patients will have some degree of underlying immunosuppression that may render them susceptible to infection. Other factors predisposing to infection include normal breast flora, poorly perfused mastectomy skin flaps, and use of prosthetic devices. Thus, some surgeons prefer to maintain patients on postoperative oral antibiotics for a limited period of time.

The occurrence of red breast syndrome can mimic the appearance of cellulitis and can be mistaken for infection.¹⁸ These patients are usually afebrile, have a normal leukocyte count, and do not manifest pain or swelling. This is presumed to be an inflammatory reaction to the ADM and is self-limiting. Because of the confusion, a short course of antibiotics is usually initiated. Prolonged redness may warrant a dermatology consult, antihistamines, biopsy, steroid therapy, or surgical exploration.

Several studies have evaluated the role and duration of postoperative antibiotics with regard to infection. Avashia et al²⁴ demonstrated infection rates of 31.6% when antibiotic delivery was limited to <24 hours postoperatively, 7.9% with 48 hours of antibiotics, and 3.2% with >48 hours of antibiotics. Clayton et al²⁶ demonstrated a 2-fold increase in surgical site infection (34.3% vs 18.1%, $P=0.004$) and a 4-fold increase in reoperation (16.4% vs 4.3%, $P=0.002$) when SCIP measures were followed compared with when they were not. Reoperation secondary to surgical site infection was also associated with obesity, previous radiation therapy, and tissue expanders. In support of SCIP measures, Phillips et al,²⁵ in a systematic review of antibiotic delivery and duration, demonstrated infection rates of 14.4%, 5.8%, and 5.8% in the setting of no antibiotics, <24 hours of antibiotics, and >24 hours of anti-

biotics, respectively. The authors' current protocol is to administer perioperative intravenous antibiotics for 24 hours followed by a 5- to 7-day course of oral antibiotics irrespective of drain duration.

Surgical drains are an essential component in the setting of prosthetic reconstruction using ADM.^{25,29,30} It is recommended to use 1–2 drains (Fig. 6), with the primary drain placed between the ADM and the lower mastectomy skin flap. A second drain can be placed between the device and the ADM or along the upper pole of the breast atop the pectoralis major muscle. Drain placement is usually through a tunnel that traverses subcutaneously for a distance of 2–3 cm. A chlorhexidine patch is placed at the skin/drain interface to minimize the migration of bacteria along the drain into the periprosthetic space.³¹ Drain duration is typically 7–14 days and based primarily on the amount of drain output and secondarily to ensure that the ADM has had enough time to adhere to the mastectomy skin flap. Ideal drain output should be <30 mL/24 hours for 2 consecutive days before removal. In some patients, drain output may be persistently high and prolonged with outputs exceeding 50 mL/d. This may be secondary to premature or increased physical activity, lymphatic fluid, or obesity. All drains are removed at the 4-week mark regardless of output. It is the authors' opinion that drain use beyond 4 weeks may increase the risk of infection. A soft compression bra has also demonstrated success in reducing the incidence of seroma.^{29,30} Tissue expansion typically begins on postoperative day 14. The occurrence of a seroma can interfere with the adherence of ADM. Recommended management for a seroma is aspiration and continued expansion.

CONCLUSIONS

ADMs have demonstrated success with primary breast reconstruction using prosthetic devices. Success is based on proper surgical technique, proper patient selection, and good surgical judgment. Adherence to the principles and concepts set forth in this article should create a framework for predictability and reproducibility and provide a foundation for good to excellent outcomes.

Maurice Y. Nahabedian, MD, FACS

Department of Plastic Surgery
Georgetown University
3800 Reservoir Rd, NW
Washington, DC, 20007
E-mail: DrNahabedian@aol.com

REFERENCES

1. Nahabedian MY. Acellular dermal matrices in primary breast reconstruction: principles, concepts, and indications. *Plast Reconstr Surg*. 2012;130:5S–2, 44–53.

2. Albornoz CR, Bach PB, Mehrara BJ, et al. A paradigm shift in U.S. Breast reconstruction: increasing implant rates. *Plast Reconstr Surg*. 2013;131:15–23.
3. Cemal Y, Albornoz CR, Disa JJ, et al. A paradigm shift in U.S. breast reconstruction: Part 2. The influence of changing mastectomy patterns on reconstructive rate and method. *Plast Reconstr Surg*. 2013;131:320e–326e.
4. Nahabedian MY. Breast reconstruction: a review and rationale for patient selection. *Plast Reconstr Surg*. 2009;124:55–62.
5. McCarthy CM, Mehrara BJ, Riedel E, et al. Predicting complications following expander/implant breast reconstruction: an outcomes analysis based on preoperative clinical risk. *Plast Reconstr Surg*. 2008;121:1886–1892.
6. Sullivan SR, Fletcher DR, Isom CD, et al. True incidence of all complications following immediate and delayed breast reconstruction. *Plast Reconstr Surg*. 2008;122:19–28.
7. Khullar D, Maa J. The impact of smoking on surgical outcomes. *J Am Coll Surg*. 2012;215:418–426.
8. Coon D, Tuffaha S, Christensen J, et al. Plastic surgery and smoking: a prospective analysis of incidence, compliance, and complications. *Plast Reconstr Surg*. 2013;131:385–391.
9. Endara M, Masden D, Goldstein J, et al. The role of chronic and perioperative glucose management in high-risk surgical closures: a case for tighter glycemic control. *Plast Reconstr Surg*. 2013;132:996.
10. Oh E, Chim H, Soltanian HT. The effects of neoadjuvant and adjuvant chemotherapy on the surgical outcomes of breast reconstruction. *J Plast Reconstr Aesthet Surg*. 2012;65:e267–e280.
11. Patel KM, Hill LM, Gatti ME, et al. Management of Massive Mastectomy Skin Flap Necrosis Following Autologous Breast Reconstruction. *Ann Plast Surg*. 2011;69:139–144.
12. Larson DL, Basir Z, Bruce T. Is oncologic safety compatible with a predictably viable mastectomy skin flap? *Plast Reconstr Surg*. 2011;127:27.
13. Kanuri A, Liu AS, Guo L. Whom should we SPY? A cost analysis of laser-assisted indocyanine green angiography in prevention of mastectomy skin flap necrosis during prosthesis-based breast reconstruction. *Plast Reconstr Surg*. 2014;133:448e–454e.
14. Endara M, Chen D, Verma K, et al. Breast reconstruction following nipple-sparing mastectomy: a systematic review of the literature with pooled analysis. *Plast Reconstr Surg*. 2013;132:1043–1054.
15. Spear SL, Economides JM, Shuck J, et al. Analyzing implant movement with tabbed and nontabbed expanders through the process of two-stage breast reconstruction. *Plast Reconstr Surg*. 2014;133:256e.
16. Khavanin N, Gust MJ, Grant DW, et al. Tabbed tissue expanders improve breast symmetry scores in breast reconstruction. *Arch Plast Surg*. 2014;41:57–62.
17. Nahabedian MY. Mastectomy, nipple areolar preservation, and immediate implant reconstruction: are total and partial muscle coverage techniques aesthetically equivalent? *Plast Reconstr Surg*. 2010;126:319e–320e.
18. Lewis P, Jewell J, Mattison G, et al. Reducing postoperative infections and red breast syndrome in patients with acellular dermal matrix based breast reconstruction: the relative roles of product sterility and lower body mass index. *Ann Plast Surg*. 2015;74:1–3.
19. Weichman KE, Wilson SC, Saadeh PB, et al. Sterile “ready-to-use” AlloDerm decreases postoperative infectious complications in patients undergoing immediate implant-based breast reconstruction with acellular dermal matrix. *Plast Reconstr Surg*. 2013;132:725–736.

20. Dietz J, Lundgren P, Veeramani A, et al. Autologous inferior dermal sling (autoderm) with concomitant skin-envelope reduction mastectomy: an excellent surgical choice for women with macromastia and clinically significant ptosis. *Ann Surg Oncol*. 2012;19:3282–3288.
21. Rinker B, Thornton BP. Skin-sparing mastectomy and immediate tissue expander breast reconstruction in patients with macromastia using the Passot breast reduction pattern. *Ann Plast Surg*. 2014;72:S158–S164.
22. Nahabedian MY. AlloDerm performance in the setting of prosthetic breast surgery, infection, and irradiation. *Plast Reconstr Surg*. 2009;124:1743–1753.
23. Adams WP, Rios JL, Smith SJ. Enhancing patient outcomes in aesthetic and reconstructive breast surgery using triple antibiotic breast irrigation: six-year prospective clinical study. *Plast Reconstr Surg*. 2006;117:30.
24. Avashia YJ, Mohan R, Berhane CC, et al. Postoperative antibiotic prophylaxis for implant-based breast reconstruction with acellular dermal matrix. *Plast Reconstr Surg*. 2013;131:453.
25. Phillips BT, Wang ED, Mirrer J, et al. Current practice among plastic surgeons of antibiotic prophylaxis and closed-suction drains in breast reconstruction: experience, evidence, and implications for postoperative care. *Ann Plast Surg*. 2011;66:460–465.
26. Clayton JL, Bazakas A, Lee CN, et al. Once is not enough: withholding postoperative prophylactic antibiotics in prosthetic breast reconstruction is associated with an increased risk of infection. *Plast Reconstr Surg*. 2012;130:495–502.
27. Phillips BT, Bishawi M, Dagum AB, et al. A systematic review of antibiotic use and infection in breast reconstruction: what is the evidence? *Plast Reconstr Surg*. 2013;131:1–13.
28. Nahabedian MY. To SCIP, or not to SCIP, the surgical care improvement project protocol. *Plast Reconstr Surg*. 2012;130:1161–1163.
29. Chun YS, Verma K, Rosen H, et al. Implant-based breast reconstruction using acellular dermal matrix and the risk of postoperative complications. *Plast Reconstr Surg*. 2010;125:429–436.
30. Ganske I, Verma K, Rosen H, et al. Minimizing complications with the use of acellular dermal matrix for immediate implant-based breast reconstruction. *Ann Plast Surg*. 2013;71:464–470.
31. Mann TJ, Orlikowski CE, Gurrin LC, et al. The effect of the biopatch, a chlorhexidine impregnated dressing, on bacterial colonization of epidural catheter exit sites. *Anaesth Intensive Care*. 2001;29:600–603.