



Case Report

Extradural malignant peripheral nerve sheath tumor of the thoracic spine: A rare case report

Ayu Yoniko Christi¹, Wisnu Baskoro¹, Bidari Kameswari², Irfaanstio Akbar Hakim¹, Vega Sola Gracia Pangaribuan¹, Andrianto Purnawan¹

Departments of ¹Neurosurgery and ²Pathology Anatomy, Dr. Soeradji Tirtonegoro General Hospital, Klaten, Central Java, Indonesia.

E-mail: *Ayu Yoniko Christi - ayuyoniko@gmail.com; Wisnu Baskoro - snu.nssby@gmail.com; Bidari Kameswari - bidarikameswari@gmail.com; Irfaanstio Akbar Hakim - irfaanstio13@gmail.com; Vega Sola Gracia Pangaribuan - vegasolagracia@gmail.com; Andrianto Purnawan - mrtopns@gmail.com



*Corresponding author:

Ayu Yoniko Christi,
Department of Neurosurgery,
Dr. Soeradji Tirtonegoro
General Hospital, Klaten,
Central Java, Indonesia.
ayuyoniko@gmail.com

Received : 17 October 2021
Accepted : 28 October 2021
Published : 16 November 2021

DOI
10.25259/SNI_1055_2021

Quick Response Code:



ABSTRACT

Background: Malignant peripheral nerve sheath tumors (MPNSTs) typically found in the trunk, limbs, head, and neck represent 3–10% of all soft-tissue sarcomas. Although they typically originating from peripheral nerve Schwann cells, 2–3% arise from the spinal nerves and may be found within the spinal canal. Here, we present a 43-year-old male with an extradural thoracic MPNST contributing to marked cord compression and a progressive paraparesis.

Case Description: A 43-year-old male presented with a progressive paraparesis of 16 months' duration. The MRI showed a posterior T2-T4 extradural tumor in the thoracic spine resulting in significant cord compression. Following a T2-T4 laminectomy and gross total excision of the epidural mass, the patient regained modest neurological function. Immunohistochemistry staining supported the diagnosis of thoracic spinal MPNST.

Conclusion: Rarely, spinal MPNST can be considered amongst the differential diagnoses of an extradural spinal tumor. In this case, gross total excision of a posterior T2-T4 epidural MPNST resulted in improvement in the patient's original paraparesis. Notably, immunohistochemistry staining helped confirm the diagnosis of a MPNST.

Keywords: Epidural mass, Extradural tumor, Histopathology, Malignant peripheral nerve sheath tumors, Spinal tumor

INTRODUCTION

Malignant peripheral nerve sheath tumors (MPNSTs) are rare (i.e. 3–10%; incidence 0.001% in general population) soft-tissue sarcomas that typically arise from major or minor peripheral nerve branches or sheaths of peripheral nerve fibers (i.e., derived from Schwann cells or pluripotent cells of neural crest origin).^[1,2,6] They typically occur in patients ages 20–60, with an equal frequency in males and females.^[6,7] The vast majority of MPNSTs occur in neurofibromatosis type 1 (NF-1) patients, with a cumulative lifetime risk of up to 10%.^[3] Spinal MPNSTs have been rarely reported and only 2–3% of all MPNSTs originate from the spinal nerves.^[6] In this report, we described a 43-year-old male without a history of neurofibromatosis, presented with a paraparesis attributed to a T2-T4 posterior extradural lesion that proved to be a MPNST.

CASE REPORT

A 43-year-old male presented with 16 months of a progressive paraparesis to final paraplegia, hypoaesthesia below the T10 sensory level, and loss of sphincter function. Interestingly,

This is an open-access article distributed under the terms of the Creative Commons Attribution-Non Commercial-Share Alike 4.0 License, which allows others to remix, tweak, and build upon the work non-commercially, as long as the author is credited and the new creations are licensed under the identical terms.

©2021 Published by Scientific Scholar on behalf of Surgical Neurology International

there was no past medical history or family history of neurofibromatosis. All lab studies were normal.

MRI study results

A whole spine MRI revealed a posterior isointense soft-tissue mass, measuring 69.5×16 mm at the T2-T4 levels that markedly compressed the cord [Figure 1]. It was strongly homogeneously enhanced with contrast [Figure 2].

Surgery

The patient underwent a T2-T4 laminectomy for posterior extradural tumor resection followed by pedicle screw stabilization. The lesion had a well-defined border and was removed in a piecemeal fashion; the dura remained intact [Figure 3].

Histopathological evaluation

On gross analysis, the specimen consisted of an aggregate of brownish-white soft-tissue fragments with a spongy consistency (i.e., weight 15 g; largest measurements were $1.5 \times 2 \times 0.6$ cm). Histopathology revealed brisk mitotic activity with the cellular area consisting of spindle nuclei arranged in a palisading pattern [Figure 4]. There was perivascular hypercellularity and slight intraluminal herniation along with well-delineated geographical necrosis with some areas with enlarged round nuclei [Figures 5-7]. Immunohistochemistry staining was positive for S100, CD99, and Ki67 [Figure 8], supporting the final diagnosis of thoracic spinal MPNST.

Postoperative course and radiation treatment

Postoperatively, the numbness in the lower extremities largely resolved but the motoric deficit improved only marginally. The patient was referred to an oncologist and received adjuvant radiotherapy with total dose of 45 Gray divided into 22 fractions. Six months later, after completion of radiotherapy, the thoracic spine MRI without contrast demonstrated cord swelling at the T2-T3-T4 levels [Figure 9]. By 18 months, the patient was bedridden without bladder control.

DISCUSSION

MPNST is a rare form of sarcoma, accounting for only 10% of all soft tissue sarcomas.^[5] MPNST arises from cells associated with the peripheral nerve including Schwann cells, perineural cells, and fibroblasts.^[4,7] The incidence of MPNST is 0.001% in the general population, but it is higher in patients with NF-1, (i.e., lifetime risk in NF-1 ranges from 8% to 13%).^[5,6] Spinal MPNSTs are even more rare, with only 2–33% of all MPNSTs originate from the spinal nerves, with most occurring in the thoracic spine.^[2,7]

Despite gross total resection of these lesions, there is still a local recurrence rate of 32–65% after median intervals of 5–32.2 months.^[5] Chou *et al.* divided surgical management of spinal MPNST into two categories, Enneking appropriate (EA) or Enneking inappropriate (EI); they found the rates of recurrence and survival were similar for patients who had either EA or EI resection for spinal MPNST.^[2]

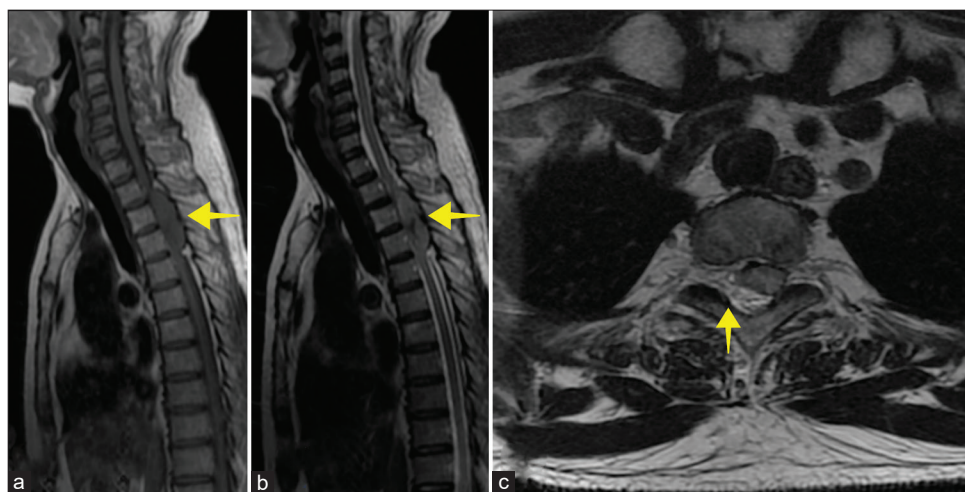


Figure 1: MRI of the thoracic spine. (a) Sagittal T1 and (b) sagittal T2-weighted image shows isointense extradural mass (yellow arrow) in thoracic spinal canal lying from T2 until T4 levels. (c) Axial T2-weighted imaging shows severe thoracic canal narrowing due to compression by the mass (yellow arrow).

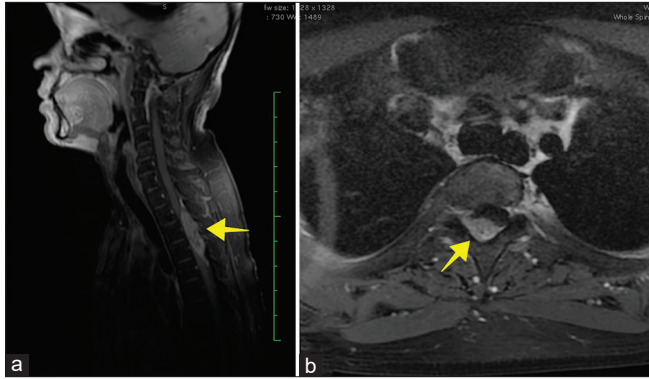


Figure 2: MRI of the thoracic spine. (a) Sagittal T1 and (b) axial T1 MRI after injection of contrast agent show strong homogenous enhancing mass (yellow arrow).

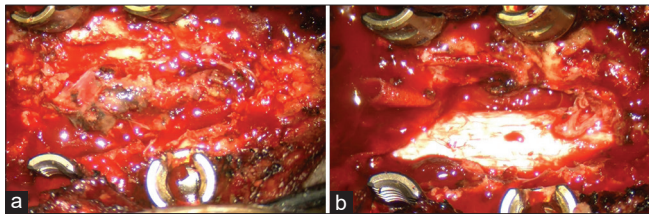


Figure 3: (a) Epidural tumor (b) after total resection, it showed intact duramater.

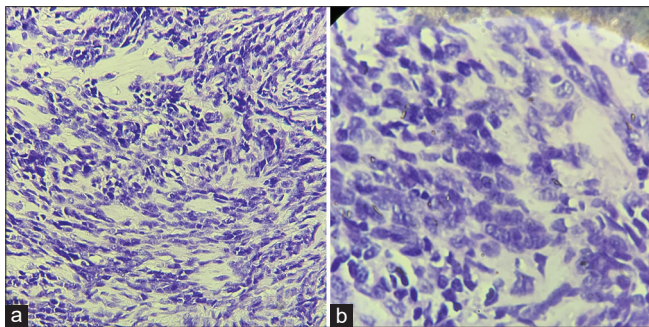


Figure 4: Brisk mitotic activity and the cellular area consists of spindle nuclei arranged in palisading pattern on ×40 zoom (a) and ×100 zoom (b).

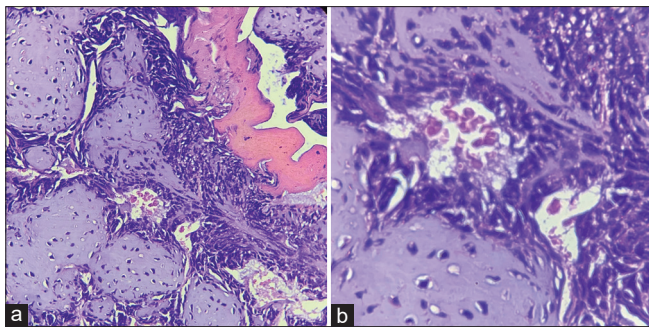


Figure 5: Pattern of perivascular hypercellularity and slight intraluminal herniation on ×40 zoom (a) and ×100 zoom (b).

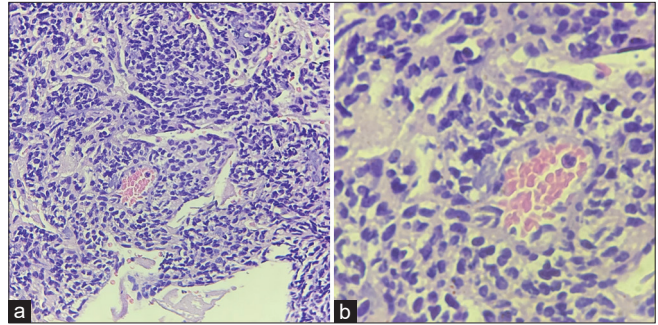


Figure 6: Pattern of perivascular hypercellularity and slight intraluminal herniation on ×40 zoom (a) and ×100 zoom (b).

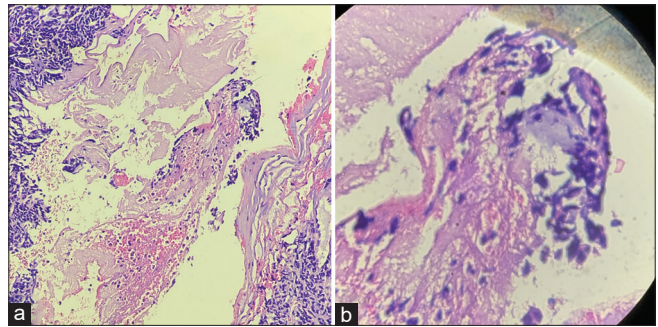


Figure 7: Well-delineated geographical necrosis on ×40 zoom (a) and ×100 zoom (b).

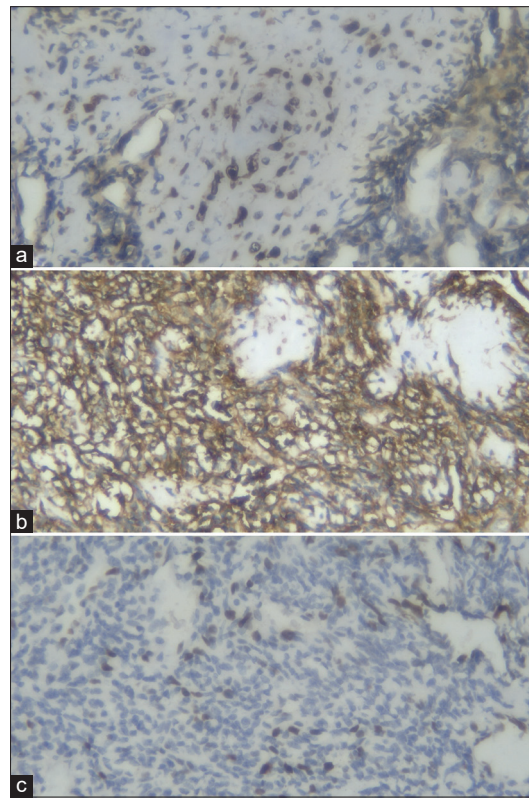


Figure 8: Immunohistochemistry staining showed positivity for S-100 (a), CD-99 (b), and Ki67 (c) on ×40 zoom.

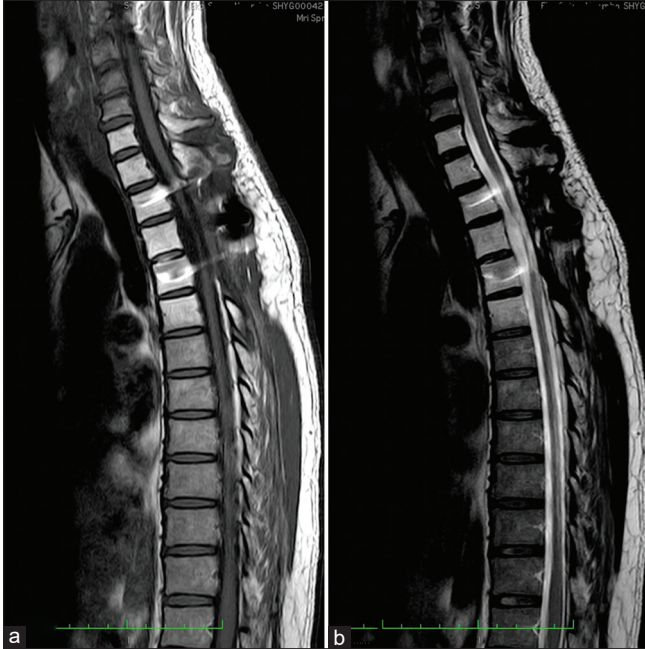

Figure 9: Sagittal T1 (a) and T2 (b) sagittal T2-weighted image thoracic MRI showed spinal cord swelling on the T2-T3-T4 levels.

Status of postoperative radiation therapy

At present, postoperative radiotherapy is recommended by the oncology consensus group for MPNST. Adjuvant radiotherapy provides local control, and may delay the onset of recurrence, but has little effect on long-term survival.^[3,6]

Overall prognosis of MPNST

Patients with MPNST have a poor prognosis. The 5-year survival rates range from 20 to 50%, and a < 20% for spinal MPNST.^[2,6] The local recurrence rate following complete resection of MPNST remains as high as 20%–40%, which is higher than any other soft tissue sarcoma, with 75% of recurrences occurring within the first 2 years of surgery.^[6]

CONCLUSION

Spinal MPNST, although rare, should be considered among the differential diagnoses for extradural spinal tumors. Here, immunohistochemistry staining of S100, CD99, and Ki67 confirmed the diagnosis of a MPNST. Despite gross total tumor excision and adjuvant radiotherapy, these

lesions have a high recurrence rate with poor long-term survivals.

Acknowledgment

We acknowledged Nadia Christina, M.D for planning and conducting the radiotherapy management for the patient.

Declaration of patient consent

The authors certify that they have obtained all appropriate patient consent.

Financial support and sponsorship

Nil.

Conflicts of interest

There are no conflicts of interest.

REFERENCES

1. Amirian ES, Goodman JC, New P, Scheurer ME. Pediatric and adult malignant peripheral nerve sheath tumors: An analysis of data from the surveillance, epidemiology, and end results program. *J Neurooncol* 2014;609-16.
2. Chou D, Bilsky MH, Luzzati A, Fisher CG, Gokaslan ZL, Rhines LD, *et al.* Malignant peripheral nerve sheath tumors of the spine: Results of surgical management from a multicenter study. *J Neurosurg* 2017;26:291-8.
3. Gupta G, Maniker A. Malignant peripheral nerve sheath tumors. *Neurosurg Focus* 2007;22:1-8.
4. Peterson MS, Waddell JK, Ebbert TL, Perry A, Berg LC. Malignant peripheral nerve sheath tumor within the spinal canal with apparent drop metastases. *Hum Pathol Case Rep* 2018;14:88-91.
5. Widemann BC. Current status of sporadic and neurofibromatosis Type 1-associated malignant peripheral nerve sheath tumors. *Curr Oncol Rep* 2009;11:322-7.
6. Winn HR. *Youmans and Winn Neurological Surgery*. 7th ed. Philadelphia, PA: Elsevier; 2017.
7. Zhu B, Liu X, Liu Z. Malignant peripheral nerve sheath tumours of the spine: Clinical manifestations, classification, treatment, and prognostic factors. *Eur Spine J* 2012;897-904.

How to cite this article: Christi AY, Baskoro W, Kameswari B, Hakim IA, Pangaribuan VS, Purnawan A. Extradural malignant peripheral nerve sheath tumor of the thoracic spine: A rare case report. *Surg Neurol Int* 2021;12:560.