

SHORT COMMUNICATION

Serological evidence of exposure of Bornean wild carnivores to feline-related viruses at the domestic animal–wildlife interface

Sergio Guerrero-Sánchez^{1,2,3} | Amanda Wilson^{3,4} | Macarena González-Abarzúa³ |
Miriam Kunde³ | Benoit Goossens^{3,5,6,7} | Rosa Sipangkui⁷ | Liesbeth Frias^{3,8}

¹Centre for Applied One Health Research and Policy Advice, Department of Infectious Diseases and Public Health, Jockey Club College of Veterinary Medicine and Life Sciences, City University of Hong Kong, Kowloon, Hong Kong

²Institute of Borneo Studies, University College Sabah Foundation, Kota Kinabalu, Malaysia

³Danau Girang Field Centre, Kota Kinabalu, Malaysia

⁴Institute for Tropical Biology and Conservation, Universiti Malaysia Sabah, Kota Kinabalu, Malaysia

⁵Organisms and Environment Division, Cardiff School of Biosciences, Cardiff University, Cardiff, UK

⁶Sustainable Places Research Institute, Cardiff University, Cardiff, UK

⁷Sabah Wildlife Department, Kota Kinabalu, Malaysia

⁸Asian School of the Environment, Nanyang Technological University, Singapore, Singapore

Correspondence

Sergio Guerrero-Sánchez, Centre for Applied One Health Research and Policy Advice, Department of Infectious Diseases and Public Health, Jockey Club College of Veterinary Medicine and Life Sciences, City University of Hong Kong, Kowloon, Hong Kong.

Email: ekio0474@gmail.com

Liesbeth Frias, Asian School of the Environment, Nanyang Technological University, Singapore.

Email: liesbeth.frias@gmail.com

Present address

Sergio Guerrero-Sánchez, Sustainable Places Research Institute, Cardiff University, Cardiff, UK

Liesbeth Frias, Sabah Wildlife Department, Kota Kinabalu, Malaysia

Funding information

Panthera Small Cat Action Fund (LF); UMSGreat Grant (AW), Grant/Award Number: GUG0440-1/2020; Ocean Park Conservation Foundation Hong Kong (BG); Sime Darby Foundation (BG); Houston Zoo (BG); Nanyang Technological University Presidential Postdoctoral Fellowship (LF), Grant/Award Number: #020617-00001

Abstract

We conducted an exploratory serological survey to evaluate the exposure of Bornean wild carnivores to several viruses common to domestic felids, at interface areas between protected forest and industrial agriculture in the Kinabatangan floodplain (Sabah, Malaysia). Blood samples, collected from wild carnivores ($n = 21$) and domestic cats ($n = 27$), were tested for antibodies against feline coronavirus (FCoV), feline panleukopenia virus (FPLV), feline herpesvirus (FHV) and feline calicivirus (FCV), using commercial enzyme-linked immunosorbent assay (ELISA) test kits. Anti-FCoV antibodies were detected in most species, including one flat-headed cat (*Prionailurus planiceps*, [1/2]), leopard cats (*Prionailurus bengalensis*, [2/5]), Malay civets (*Viverra zibetha*, [2/11]) and domestic cats (*Felis catus*, [2/27]). Anti-FCV antibodies were present in all domestic cats and one flat-headed cat, while anti-FPLV antibodies were identified in Sunda clouded leopards (*Neofelis diardi*, [2/2]), domestic cats [12/27] and Malay civets [2/11]. Anti-FHV antibodies were only detected in domestic cats [2/27]. Our findings indicate pathogen transmission risk between domestic and wild carnivore populations at the domestic animal–wildlife interface, emphasizing the concern for wildlife conservation for several endangered wild carnivores living in the area. Special consideration should be given to species that benefit from their association with humans and have the potential to carry pathogens between forest and plantations (e.g., Malay civets and

This is an open access article under the terms of the [Creative Commons Attribution-NonCommercial](https://creativecommons.org/licenses/by-nc/4.0/) License, which permits use, distribution and reproduction in any medium, provided the original work is properly cited and is not used for commercial purposes.

© 2022 The Authors. *Transboundary and Emerging Diseases* published by Wiley-VCH GmbH.

leopard cats). Risk reduction strategies should be incorporated and supported as part of conservation actions in human-dominated landscapes.

KEYWORDS

civets, domestic cats, infectious diseases, oil palm, wild felids

1 | INTRODUCTION

Frequent encounters between domestic animals and wildlife, as a result of human-mediated encroachment and fragmentation of wildlife habitats, can be detrimental for wild populations, especially when endangered (Nyhus, 2016). Because domestic animals often outnumber wildlife hosts of shared pathogens, they can maintain the environmental circulation of pathogens that can drive smaller populations of wild animals to extinction. As an example, canine distemper virus initially spreading from domestic dogs to lions almost drove the local population to extinction in the Serengeti ecosystem (Cleaveland et al., 1995). Even after widespread dog vaccination had reduced the infection in dogs, transmission to lions still occurred (Viana et al., 2015), emphasizing the complexities of controlling an infection once spread into natural protected areas.

In Sabah (Malaysian Borneo), oil palm plantations have become part of the dominant landscape, impacting the behaviour, adaptability and survival capacities of different wildlife species, particularly those that require extensive and continuous habitat (Hearn et al., 2019). The complex oil palm-dominated matrix favours the increasing interaction between domestic and wild animals, as well as the risk of pathogen transmission, especially for wild carnivores, which are susceptible to multi-host pathogens (Sepúlveda et al., 2014). The Kinabatangan floodplain, located in the east coast of Sabah, has sustained decades of large-scale commercial logging and extensive land conversion to industrial oil palm plantations, resulting in a heavily impacted landscape with significant forest loss, fragmentation and degradation (Abram et al., 2014). Nonetheless, the Lower Kinabatangan Wildlife Sanctuary (LKWS) remains an important biodiversity hotspot in the island of Borneo and a stronghold for many endangered and endemic species. Four out of five Bornean felids can be found here (Hearn et al., 2018), and three of them, that is, the Sunda clouded leopard (*Neofelis diardi*), the leopard cat (*Prionailurus bengalensis*) and the flat-headed cat (*P. planiceps*), have been observed using areas frequented by domestic dogs and cats (Figure 1). Among these species, leopard cats seem to have a higher tolerance to anthropogenic landscapes, as they can be found inhabiting a broad range of habitat types, including disturbed and undisturbed forests, rubber estates and oil palm plantations (Rajaratman et al., 2007). Likewise, two species of civets, that is, the Malay civet (*Viverra zangalunga*) and the common palm civet (*Paradoxurus hermaphroditus*), are the most common viverrids roaming around the boundaries between oil palm plantations and natural forest (Ross et al., 2016). Due to their persistence in oil palm-dominated landscapes, both leopard cats and civets are species that can potentially spread

pathogens to other wildlife, linking reservoir hosts to susceptible populations of wild carnivores (Caron et al., 2015).

2 | MATERIALS AND METHODS

To better understand the exposure of wild carnivores to pathogens common in domestic felids, we conducted an exploratory serological survey in the LKWS (5° 18' N-5° 42' N and 117° 54' E-118° 33' E) and surrounding oil palm plantations. Immunological tests are a useful tool to detect historical exposure to pathogens, as well as to assess the success of vaccination programs. Commercial immunological kits, such as enzyme-linked immunosorbent assays (ELISA), have provided valuable preliminary information regarding the health status of wildlife, both in captivity and free-ranging, and are more easily adaptable to field conditions (Franklin et al., 2007). The evaluation of diagnostic kits in domestic cats and several wild cats species further suggests that the risk of misinterpreting results due to species-specificity is low, when positive reactions are higher than the cut-off point (Naidenko et al., 2018).

Wild carnivores were captured within and around the LKWS between 2019 and 2021. Sunda clouded leopards and civets were captured using cage traps, while leopard cats and flat-headed cats were netted. All wild animals were immobilized using different anaesthesia protocols for each species (Table 1). Health and body condition were assessed prior to sample collection. Adult domestic cats were sampled in plantation quarters with the permission and assistance of their owners. Physical examination suggested that both wild and domestic individuals were in good physical condition, and domestic cat owners declared that their pets had never been vaccinated. Blood samples were collected by venipuncture of the saphenous or cephalic veins and centrifuged in the field within 2 h of collection. Plasma was stored in the freezer until used for analysis. Plasma samples were tested for antibodies against feline coronavirus (FCoV) (ImmunoComb, Biogal Galed Lab. Acs. Ltd., Israel), feline panleukopenia virus (FPLV), feline herpes virus (FHV) and feline calicivirus (FCV) (VacciCheck, Biogal Galed Lab. Acs. Ltd., Israel). ImmunoComb has a reported specificity and sensitivity of 100% in domestic cats (Addie et al., 2015), while VacciCheck has a specificity of 91% for FCV, 96% for FHV and 98% for FPLV, and a sensitivity of 90% for FCV, 93% for FHV, and 89% for FPLV (Mazar et al., 2011). Although results provided by the kits are qualitative, reaction intensity can be defined as 'low', 'moderate' and 'high' according to the manufacturer's instructions. These commercial kits have been previously tested in wild felids with satisfactory results (Naidenko et al., 2018).

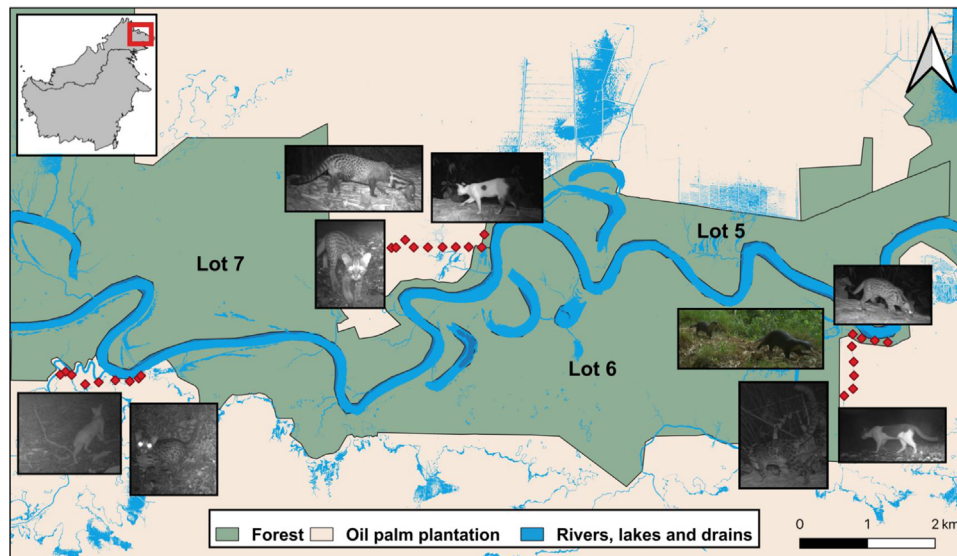


FIGURE 1 Camera trap transects deployed at the boundary between forest and oil palm plantation estates, where both domestic and wild carnivores have been frequently recorded

TABLE 1 Seroprevalence of pathogens in Bornean wild and domestic carnivores

Species	IUCN	N	Anaesthesia protocol ^a	FCoV (1:20) (%)	FPLV (1:80) (%)	FHV (1:16) (%)	FCV (1:32) (%) ^b
Sunda clouded leopard (<i>Neofelis diardi</i>)	VU	2	Ket.-Med. (3-0.06)	0	100	0	0
Leopard cat (<i>Prionailurus bengalensis</i>)	LC	5	Ket.-Med. (5-0.05)	40	0	0	0
Flat-headed cat (<i>Prionailurus planiceps</i>)	EN	2	Ket.-Med. (5-0.06)	50	0	0	50
Malay civet (<i>Viverra zangalunga</i>)	LC	11	Ket.-Zol.-Med. (2-2-0.1)	18.2	18.2	0	0
Common palm civet (<i>Paradoxurus hermaphroditus</i>)	LC	1	Ket.-Zol.-Xy. (1.5-2-1.5)	0	0	0	0
Domestic cat (<i>Felis catus</i>)	-	27	-	7.4	44.4	7.4	100

Abbreviations: EN, endangered; FCoV, feline coronavirus; FCV, feline calicivirus; FHV, feline herpesvirus; FPLV, feline panleukopenia virus; IUCN, International Union for the Conservation of Nature; Ket., ketamine; LC, least concern; Med., medetomidine; VU, vulnerable; Xy., xylazine; Zol., zoletil.

^aAnaesthesia protocols are given in mg/kg.

^bBaseline titres to be considered as positive, according to manufacturer's instructions.

[Correction added on 11 May 2022, after first online publication: "Ket.-Med. (5-0.06)" was changed to "LC" for Leopard cat under IUCN column.]

3 | RESULTS AND DISCUSSION

Wild carnivores tested positive for three out of the four pathogens studied (Table 1). All Sunda clouded leopards ($n = 2$), two Malay civets (18.2%; $n = 11$) and 12 domestic cats (44.4%; $n = 27$) tested positive for antibodies to FPLV. [Correction added on 11 May 2022, after first online publication: 44% was changed to 44.4% in the preceding sentence.] One flat-headed cat (50%; $n = 2$), two leopard cats (40%; $n = 5$), two Malay civets (18.2%) and two domestic cats (7.4%) tested positive for FCoV. All domestic cats and one flat-headed cat tested positive for FCV, while only two domestic cats (7.4%) were infected with FHV. The intensity of positive reactions varied among studied species and viruses. Positive reaction against FCoV was high in two out of the seven domestic cats, while the other five showed low reaction. Low reaction for FCoV was also observed in two leopard cats, one flat-headed cat

and two Malay civets. For FPLV, out of the 17 positive domestic cats, seven indicated high reaction, five were moderate and the other five presented low reaction. One Sunda clouded leopard and one Malay civet presented moderate reaction to FPLV, while the other sampled individuals from these species had a low reaction to the virus. While domestic cats had a low reaction to FHV, all of them, including one flat-headed cat, had a high reaction to FCV.

In this serological survey, only one of the flat-headed cats tested positive for both FCoV and FCV, while the two Sunda clouded leopards presented antibodies against FPLV. Infection with FCoV is of concern, particularly in endangered populations, as it can result in fatal feline infectious peritonitis. Feline coronavirus is shed in faeces, and cats can become infected by ingesting or inhaling the virus. Feline calicivirus is extremely contagious, especially in areas with high feline densities (Lenghaus et al., 2001), as reflected by the seropositivity of all domestic

cats in this study. Feline panleukopenia virus is highly contagious and has been reported in felids, procyonids and viverrids (Inthong et al., 2019). It has also been associated with high morbidity and mortality, especially in young individuals (Steinel et al., 2001). On the other hand, FHV is relatively fragile and short-lived outside felines, so the external environment is not a long-term source of infection. Since all individuals, wild and domestic, were reported in good physical condition and with no clinical signs, our results only demonstrate viral circulation among carnivores, and no actual active disease.

Although the use of commercial kits have been shown to be effective in a wide range of wild felid species and recommended as an adequate alternative for disease monitoring and sero-surveillance (Franklin et al., 2007; Naidenko et al., 2018), there is still a risk of misinterpreting results when titre levels are low. The existence of endogenous parvoviruses in several mammal species (Kapoor et al., 2010) and the antigenic diversity of coronaviruses (Kennedy et al., 2001), might favour cross-reactivity, especially for FPLV and FCoV. Our study highlights special concern for the high reaction of one flat-headed cat to FCoV, as well as moderate reactions of one Sunda clouded leopard and one Malay civet to FPLV. Although low reactions should be taken cautiously due to the likelihood of cross-reactivity, the sero-prevalence found in domestic cats in the area suggests that the presence of these viruses in the carnivore community should not be readily dismissed. So far, there is no evidence on the performance of commercial ELISA test kits for viverrids, such as Malay and common palm civets. However, as some members of this family are susceptible to FPLV (Demeter et al., 2009; Steinel et al., 2001), viverrids should still be considered as a group of concern in areas where their interaction with domestic felids is high, especially since viral shedding can occur from asymptomatic individuals (Lorusso et al., 2019; Meli et al., 2013).

Our results provide the first data on exposure of Bornean wild carnivores to various viruses common to domestic felids with which they overlap. Among Bornean felids, the flat-headed cat is the least studied and it is listed as endangered, while the conservation status of the Sunda clouded leopard is reported as vulnerable. Flat-headed cats have been reported using oil palm plantations in the Kinabatangan floodplain (González-Abarzúa et al., 2021). In fact, one individual sampled in this study was captured within an oil palm estate, while the other was trapped at a plantation edge. The elusive nature and low densities of these two species make incidental observations like these highly valuable. Most importantly, our findings highlight an underestimated effect of oil palm plantations on the native community of carnivores, through the risk of infectious disease transmission from domestic animals due to increased inter-species interactions and habitat overlap. They also evidence the importance of including animal health and welfare programs as part of the management protocols of oil palm companies. Although serosurveys do not allow for the identification of active infection during sampling, they underline the importance of establishing continuous monitoring for diseases at the domestic animal-wildlife interface, and provide a relevant baseline in areas where these data are lacking.

During this study, we detected the presence of one Sunda clouded leopard roaming around the boundaries between oil palm and adja-

cent forest. While this species is more likely to avoid anthropogenic habitats (Hearn et al., 2018), all the other carnivores involved in the study, including domestic cats, have been reported using both forest and oil palm plantations, making them potential carriers of pathogens to more vulnerable species, including Sunda clouded leopards, flat-headed cats, smooth-coated and hairy-nosed otters (*Lutrogale perspicillata*, *Lutra sumatrana*), among other eight species of carnivores reported in the area under different conservation status. The design and implementation of preventive medicine programs, as part of oil palm plantation management strategies, can assist the responsible ownership of domestic carnivores within estates and minimize pathogen spillover to vulnerable wildlife. By incorporating continuous infectious disease monitoring of wild and domestic carnivores, conservation initiatives can additionally support the long-term survival of populations living in interface areas.

ACKNOWLEDGEMENTS

We thank research assistants at the Danau Girang Field Centre for logistical support, plantation managers for granting us access to estates, and animal owners in plantations for kindly participating in our research. This study was financially supported by Panthera through its Small Cat Action Fund to LF and by Universiti Malaysia Sabah through its UMSGreat Grant (GUG0440-1/2020) to AW. Additional funding was provided by Ocean Park Conservation Foundation Hong Kong, Sime Darby Foundation and Houston Zoo to BG. LF is supported by a Nanyang Technological University Presidential Postdoctoral Fellowship (#020617-00001).

CONFLICT OF INTEREST

The authors declare no conflict of interest.

ETHICS STATEMENT

Animal handling and sampling protocols were designed and conducted by veterinarians, and reviewed and authorized by Sabah Wildlife Department and the Sabah Biodiversity Centre (JKM/MBS.1000-2/2 JLD.8 [110]; JKJ/MBS.1000-2/2 JLD.10 [57,59]) as part of the procedures to authorize access to natural resources, as well as for trapping and handling wildlife.

DATA AVAILABILITY STATEMENT

The authors confirm that the data supporting the findings of this study are available within the article.

REFERENCES

- Abram, N. K., Meijaard, E., Ancrenaz, M., Runting, R. K., Wells, J. A., Gaveau, D., Pellier, A. S., & Mengersen, K. (2014). Spatially explicit perceptions of ecosystem services and land cover change in forested regions of Borneo. *Ecosystem Services*, 7, 116–127. <https://doi.org/10.1016/j.ecoser.2013.11.004>
- Addie, D. D., Le Poder, S., Burr, P., Decaro, N., Graham, E., Hofmann-Lehmann, R., Jarrett, O., McDonald, M., & Meli, M. L. (2015). Utility of feline coronavirus antibody tests. *Journal of Feline Medicine and Surgery*, 17(2), 152–162. <https://doi.org/10.1177/1098612x14538873>
- Caron, A., Cappelle, J., Cumming, G. S., de Garine-Wichatitsky, M., & Gaidet, N. (2015). Bridge hosts, a missing link for disease ecology in

- multi-host systems. *Veterinary Research*, 46(1), 1–11. <https://doi.org/10.1186/s13567-015-0217-9>
- Cleaveland, S., & Dye, C. (1995). Maintenance of a microparasite infecting several host species: Rabies in the Serengeti. *Parasitology*, 111(S1), S33–S47. <https://doi.org/10.1017/S0031182000075806>
- Demeter, Z., Gál, J., Palade, E. A., & Rusvai, M. (2009). Feline parvovirus infection in an Asian palm civet (*Paradoxurus hermaphroditus*). *The Veterinary Record*, 164(7), 213. <https://doi.org/10.1136/vr.164.7.213>
- Franklin, S. P., Troyer, J. L., TerWee, J. A., Lyren, L. M., Kays, R. W., Riley, S. P., Boyce, W. M., Crooks, K. R., & Vandewoude, S. (2007). Variability in assays used for detection of lentiviral infection in bobcats (*Lynx rufus*), pumas (*Puma concolor*), and ocelots (*Leopardus pardalis*). *Journal of Wildlife Diseases*, 43(4), 700–710. <https://doi.org/10.7589/0090-3558-43.4.700>
- González-Abarzúa, M. C., Kunde, M. N., Fitri, M. S., & Goossens, B. (2021). First capture of a flat-headed cat in an oil palm plantation in Sabah, Borneo. *CATNews*, 72, 37–38.
- Hearn, A. J., Cushman, S. A., Ross, J., Goossens, B., Hunter, L. T., & Macdonald, D. W. (2018). Spatio-temporal ecology of sympatric felids on Borneo. Evidence for resource partitioning? *PLoS One*, 13(7), e0200828. <https://doi.org/10.1371/journal.pone.0200828>
- Hearn, A. J., Ross, J., Bernard, H., Bakar, S. A., Goossens, B., Hunter, L. T., & Macdonald, D. W. (2019). Responses of Sunda clouded leopard *Neofelis diardi* population density to anthropogenic disturbance: Refining estimates of its conservation status in Sabah. *Oryx*, 53(4), 643–653. <https://doi.org/10.1017/S0030605317001065>
- Inthong, N., Sutacha, K., Kaewmongkol, S., Sinsiri, R., Sribuarod, K., Sirinarumit, K., & Sirinarumit, T. (2019). Feline panleukopenia virus as the cause of diarrhea in a banded linsang (*Prionodon linsang*) in Thailand. *Journal of Veterinary Medical Science*, 81(12), 1763–1768. <https://doi.org/10.1292/jvms.19-0238>
- Kapoor, A., Simmonds, P., & Lipkin, W. I. (2010). Discovery and characterization of mammalian endogenous parvoviruses. *Journal of Virology*, 84(24), 12628–12635. <https://doi.org/10.1128/JVI.01732-10>
- Kennedy, M., Citino, S., Dolorico, T., McNabb, A. H., Moffat, A. S., & Kania, S. (2001). Detection of feline coronavirus infection in captive cheetahs (*Acinonyx jubatus*) by polymerase chain reaction. *Journal of Zoo and Wildlife Medicine*, 32(1), 25–30. [https://doi.org/10.1638/1042-7260\(2001\)032\[0025:DOFCII\]2.0.CO;2](https://doi.org/10.1638/1042-7260(2001)032[0025:DOFCII]2.0.CO;2). PMID:12790391
- Lenghaus, C., Studdert, M. J., & Gavier-Widen, D. (2001). Calicivirus infections. In E. S. Williams & I. K. Barker (Eds.), *Infectious diseases of wild mammals*, Williams. (pp. 280–291). Iowa State University Press.
- Lorusso, E., Mari, V., Losurdo, M., Lanave, G., Trotta, A., Dowgier, G., Colaiani, M. L., Zatelli, A., Elia, G., Buonavoglia, D., & Decaro, N. (2019). Discrepancies between feline coronavirus antibody and nucleic acid detection in effusions of cats with suspected feline infectious peritonitis. *Research in Veterinary Science*, 125, 421–424. <https://doi.org/10.1016/j.rvsc.2017.10.004>
- Mazar, S., DiGangi, B., & Dubovi, E. (2011). Sensitivity-specificity and accuracy of the ImmunoComb Feline VacchiCheck Antibody Test Kit for Feline Calici, Herpes and Panleukopenia Viruses. <https://www.biogal.com/wp-content/uploads/2020/03/SS-FVV-Study-17.12.12.pdf>
- Meli, M. L., Burr, P., Decaro, N., Graham, E., Jarrett, O., Lutz, H., McDonald, M., & Addie, D. D. (2013). Samples with high virus load cause a trend toward lower signal in feline coronavirus antibody tests. *Journal of Feline Medicine and Surgery*, 15(4), 295–299. <https://doi.org/10.1177/1098612x12467995>
- Naidenko, S. V., Hernandez-Blanco, J. A., Pavlova, E. V., Erofeeva, M. N., Sorokin, P. A., Litvinov, M. N., Kotlyar, A. K., Sulikhan, N. S., & Rozhnov, V. V. (2018). Primary study of seroprevalence to virus pathogens in wild felids of South Primorie, Russia. *Canadian Journal of Zoology*, 96(8), 839–846. <https://doi.org/10.1139/cjz-2017-0192>
- Nyhus, P. J. (2016). Human-wildlife conflict and coexistence. *Annual Review of Environment and Resources*, 41, 143–171. <https://doi.org/10.1146/annurev-environ-110615-085634>
- Rajaratnam, R., Sunquist, M., Rajaratnam, L., & Ambu, L. (2007). Diet and habitat selection of the leopard cat (*Prionailurus bengalensis borneoensis*) in an agricultural landscape in Sabah, Malaysian Borneo. *Journal of Tropical Ecology*, 23(2), 209–217. <https://doi.org/10.1017/S0266467406003841>
- Ross, J., Hearn, A. J., Macdonald, D. W., Alfred, R., Cheyne, S. M., Mohamed, A., Boonratana, R., Bernard, H., Hon, J., Brodie, J. F., Giordano, A., Heydon, M., Semadi, G., Mathai, J., Fredriksson, G., Marshall, A. J., Pilgrim, J. D., van Berkel, T., Belant, J. L., ... Wilting, A. (2016). Predicted distribution of the Malay civet *Viverra zibetha* (Mammalia: Carnivora: Viverridae) on Borneo. *Raffles Bulletin of Zoology*, 33, 78–83.
- Sepúlveda, M. A., Singer, R. S., Silva-Rodríguez, E. A., Eguren, A., Stowhas, P., & Pelican, K. (2014). Invasive American mink: Linking pathogen risk between domestic and endangered carnivores. *EcoHealth*, 11(3), 409–419. <https://doi.org/10.1007/s10393-014-0917-z>
- Steinel, A., Parrish, C. R., Bloom, M. E., & Truyen, U. (2001). Parvovirus infections in wild carnivores. *Journal of Wildlife Diseases*, 37(3), 594–607. <https://doi.org/10.7589/0090-3558-37.3.594>
- Viana, M., Cleaveland, S., Matthiopoulos, J., Halliday, J. O., Packer, C., Craft, M. E., Hampson, K., Czupryna, A., Dobson, A. P., Dubovi, E. J., Ernest, E., Fyumagwa, R., Hoare, R., Hopcraft, J. G. C., Horton, D. L., Kaare, M. T., Kanellos, T., Lankester, F., Mentzel, C., ... Lembo, T. (2015). Dynamics of a morbillivirus at the domestic-wildlife interface: Canine distemper virus in domestic dogs and lions. *Proceedings of the National Academy of Sciences*, 112(5), 1464–1469. <https://doi.org/10.1073/pnas.1411623112>

How to cite this article: Guerrero-Sánchez, S., Wilson, A., González-Abarzúa, M., Kunde, M., Goossens, B., Sipangkui, R., & Frias, L. (2022). Serological evidence of exposure of Bornean wild carnivores to feline-related viruses at the domestic animal-wildlife interface. *Transboundary and Emerging Diseases*, 69, e3250–e3254. <https://doi.org/10.1111/tbed.14549>