

Received: 2019.01.09 Accepted: 2019.02.28 Published: 2019.05.09

# A Rare Case of Stage IV Basaloid Squamous Cell Cancer with Intrapulmonary and Brain Metastases

Authors' Contribution: Study Design A Data Collection B Statistical Analysis C Data Interpretation D Manuscript Preparation E Literature Search F Funds Collection G

EF 1 Sundeep Grandhe EF 1 Tushar Bajaj EF 1,2 Hanh Duong EF 1 Saman N. Ratnayake

1 Department of Medicine, Kern Medical Center, University of California, Los Angeles (UCLA), Bakersfield, CA, U.S.A. 2 Department of Medicine, Ross University School of Medicine, Miramar, FL, U.S.A.

Corresponding Author: Sundeep Grandhe, e-mail: [sundeep.grandhe@kernmedical.com](mailto:sundeep.grandhe@kernmedical.com) Conflict of interest: None declared

Patient: Male, 42 Final Diagnosis: Basaloid squamous cell carcinoma of the neck Symptoms: Headache • neck swelling • throat pain Medication: — Clinical Procedure: — Specialty: Oncology

Objective: Rare disease Background: Metastatic basaloid squamous cell carcinoma is a fatal, high-grade variant of squamous cell carcinoma that is extremely rare in the oral cavity. We present a rare case of metastatic basaloid squamous cell carcinoma arising from the hypopharynx with pulmonary and brain metastases. Recognizing this diagnostic subtype is of critical importance due to the aggressive nature and high incidence of recurrence, lymph node metastases, and mortality.

Case Report: A 42-year-old male arrived at the Emergency Department reporting a 1-week headache. Six months prior, he reported throat pain and neck swelling. Triple endoscopy revealed a large ulcerative tumor. A carbon dioxide laser procedure debulked and removed the mass. Incisional biopsy with histopathology was consistent with invasive basaloid squamous cell carcinoma. Computed tomography (CT) of the neck with contrast demonstrated bilateral cervical level II/III necrotic adenopathy, and CT chest with contrast demonstrated bilateral pulmonary nodules. The patient completed chemoradiation therapy with cisplatin; however, repeat CT chest revealed enlarging intrapulmonary metastases. CT brain without contrast demonstrated a central brainstem lesion. The patient started treatment with pembrolizumab. On day 14 of treatment, he presented to the Emergency Department again for headache. MRI of brain with contrast demonstrated a new lesion with vasogenic edema. Intravenous dexamethasone was started and the decision to pursue stereotactic radiosurgery was made.

Conclusions: The diagnosis of basaloid squamous cell carcinoma in the setting of intrapulmonary and brain metastases is an extremely rare, high-grade bimorphic aggressive variant of squamous cell carcinoma that needs to be histopathologically differentiated from other tumors. Given its high mortality rate and poor prognosis the decision to pursue further treatment versus aggressive palliative care should be discussed.

MeSH Keywords: Carcinoma, Squamous Cell • Head and Neck Neoplasms • Medical Oncology

Full-text PDF: <https://www.amjcaserep.com/abstract/index/idArt/915073>

1340 — 2 14

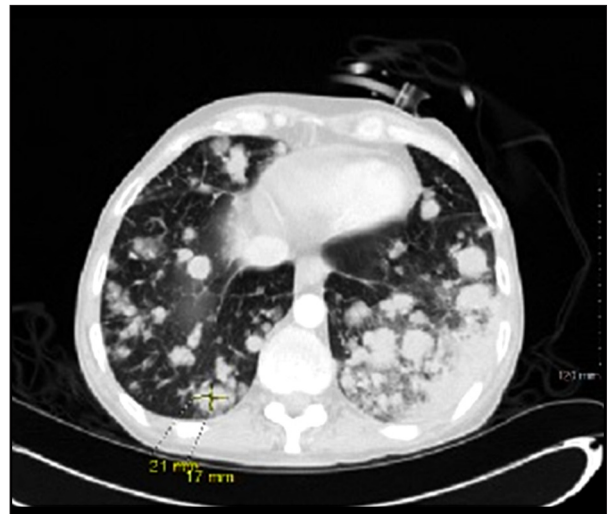


## Background

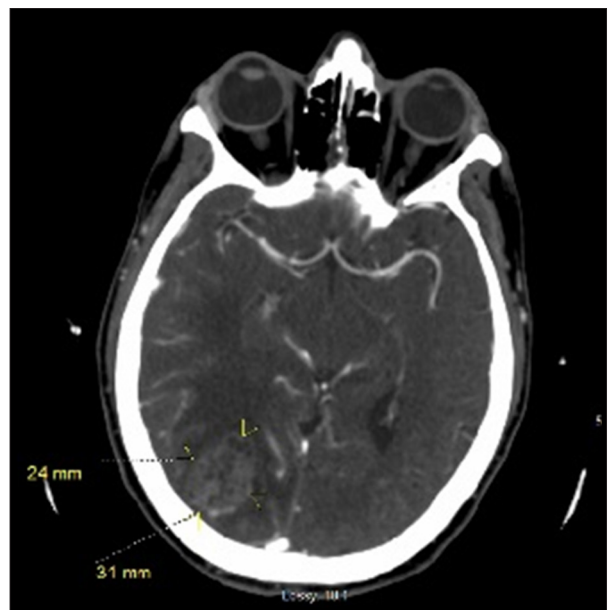Metastatic basaloid squamous cell carcinoma is a fatal, high-grade variant of squamous cell carcinoma that is extremely rare in the oral cavity; however, it is common in the oropharynx. We present a very rare case of metastatic basaloid squamous cell carcinoma arising from the hypopharynx with pulmonary and brain metastases. Recognizing this diagnostic subtype is of critical importance due to the aggressive nature and high incidence of recurrence, lymph node metastases, and mortality.

## Case Report

A 42-year-old male arrived at the Emergency Department reporting a 1-week history of headache. Six months prior to presentation, he reported increasing throat pain and noted an increasing amount of swelling of the left side of his neck and throat. He reported an extensive history of smoking, approximately 1 pack daily for 30 years. On examination, an ulceroproliferative growth that measured 2×2 cm with indurated margins on the lower aspect of the hypopharynx was identified. On mirror laryngoscopy, there was a very large tumor obstructing the supraglottic larynx that was centered around the left side of the hypopharynx. The true vocal cords could not be visualized although the right-hand side of the larynx could be seen. Triple endoscopy was performed and in the base of tongue and vallecula, there was a large ulcerative tumor found within the base of the tongue. It did not extend past the circumvallate papillae and did not involve the tonsils or the lateral pharyngeal wall but involved the lingual surface of the epiglottis. The laryngeal surface of the epiglottis was free from any evidence of mucosal lesions and the tumor did not invade into the piriform sinus. There was a large knob of tumor pushing the epiglottis inferiorly, which posed risk of airway obstruction, so a carbon dioxide laser was used to slowly debulked and removed the tumor in a piecemeal fashion, with subsequent examination via laryngoscope revealing no residual lesions in the bronchi or subsegmental bronchi. Incisional biopsy was performed at the base of the tongue with histopathology revealing tumor cells with a basaloid appearance, hyperchromatic nuclei with scanty cytoplasm arranged in a lobular configuration amongst a background of mitotic figures consistent with a diagnosis of invasive basaloid squamous cell carcinoma of the base of the tongue. Polymerase chain reaction amplification did not detect the presence of human papillomavirus DNA. Computed tomography (CT) of the neck soft tissue with contrast demonstrated bilateral cervical level II and level III necrotic adenopathy likely metastatic and CT of the chest with contrast demonstrated innumerable bilateral pulmonary nodules measuring up to 1 cm in diameter with mediastinal and right hilar adenopathy concerning for metastatic disease. The patient subsequently completed chemoradiation therapy with weekly cisplatin with significant



**Figure 1.** Computed tomography of the chest with contrast November 16, 2018. Marked interval enlargement mediastinal/hilar adenopathy and numerous pulmonary nodules bilaterally. A right lower lobe nodule 21×17 mm.



**Figure 2.** MRI of brain with contrast October 9, 2018. There has been significant interval increase in the size of a second heterogenous enhancing mass located in the right occipital lobe that currently measures 3.1×2.4×2.6 cm versus 0.8×0.5×1.3 cm on the prior study. There is extensive accompanying vasogenic edema surrounding this lesion.

decrement in the size of his neck mass; however, repeat CT chest with contrast status post chemoradiation revealed enlarging intrapulmonary metastases with mediastinal lymphadenopathy indicative of progression of disease (Figure 1). CT brain without

contrast demonstrated a small enhancing lesion in the central brainstem atypical for metastasis. After extensive discussion, the patient opted for treatment with pembrolizumab based on the KEYNOTE-055 study [1]. On day 14 of treatment, he presented to the emergency department endorsing sharp bilateral retro-orbital headache. MRI brain with contrast demonstrated a new heterogenous enhancing mass lesion in the periphery of the right temporo-occipital lobe that measures 1.4×1.6×1.1 cm with associated vasogenic edema (Figure 2). There had been significant interval increase in the size of a second heterogenous enhancing mass located in the right occipital lobe that now measured 3.1×2.4×2.6 cm versus 0.8×0.5×1.3 cm on the prior study, with extensive accompanying vasogenic edema surrounding the lesion with 4 mm midline shift representing new brain metastases, an extremely poor prognostic finding. He was started on dexamethasone IV 4 mg every 6 hours and after discussion of possible treatment modalities, he decided on pursuing stereotactic radiosurgery.

## Discussion

Basaloid squamous cell carcinoma is an extremely rare variant of squamous cell carcinoma with a reported frequency of less than 1% of all squamous cell cancers [2]. It may also present like squamous cell carcinoma with a painless irregular mass which may or may not ulcerate [3–6], and frequently with metastasis of cervical lymph nodes due to rich lymphatic accessibility [7,8]. Our patient followed this presentation, arriving into the emergency department with an enlarging tender neck mass. It was also noted at this time that he had bilateral cervical level II and III necrotic adenopathy that were likely due to metastasis. Basaloid squamous cell carcinoma is more aggressive and will more often have distant metastasis instead of recurring locally [9]. Our patient continued to have metastasis after treatment to the lungs and brain, which rarely has been reported with basaloid squamous cell carcinoma.

Basaloid squamous cell carcinoma is shown to affect predominantly older age groups, affecting both men and women but primarily men in seventh decade of life. Similar to squamous cell carcinoma's pathophysiology, literature describes most patients with basaloid squamous cell carcinoma as having a long history of alcohol and tobacco abuse [4]. Our patient was in his 40's, much younger than most patients diagnosed with basaloid squamous cell carcinoma. However, he did have a contributory 30-year history of tobacco use along with alcohol, THC (tetrahydrocannabinol), and methamphetamine abuse, that increased his exposure risk significantly.

Although histologically distinct, basaloid squamous cell carcinoma can be misdiagnosed as adenoid cystic carcinoma, adenosquamous carcinoma, basal cell adenocarcinoma, or salivary

duct carcinoma. Further biopsies should be done to confirm diagnosis because histologically basaloid squamous cell carcinoma will have a biphasic pattern of basaloid and squamous components, with a predominantly basaloid component (80% to 90%) and scanty cytoplasm with high mitotic figures and nuclear pleomorphism [4]. In our patient's case, the tumor appeared histologically the same, with basaloid appearance, and hyperchromatic nuclei with background mitotic figures.

Basaloid squamous cell carcinoma tends to be diagnosed in the later stages and because of this, it has an extremely poor prognosis and high mortality rate [8]. Although our patient had presented at an earlier stage, he already had pulmonary nodules resembling metastasis at time of diagnosis. A study performed in 2017 that assessed basaloid squamous cell carcinoma's aggressive pattern revealed 50% mortality and 57% of deaths were a result of secondary tumors [9]. Our patient's health progressively declined with the main complaint of shortness of breath, which was due to numerous pulmonary metastatic nodules causing hypoxia. Despite early diagnosis and intensive treatment, our patient expired after 10 months, which was much earlier compared to a median reported survival of 34 months [9], which further confirms basaloid squamous cell carcinoma lethality.

Treatment of basaloid squamous cell carcinoma is controversial with no standard protocol accepted universally. In resectable lesions with no evidence of metastasis, complete surgical excision, supplemented by postoperative radiation and chemotherapy is considered most acceptable [10–12]. There are also reports of 5-fluorouracil and cisplatin efficacy for treatment of basaloid squamous cell carcinoma with metastasis [13]. Our patient had surgical debulking of his epiglottic tumor and adjuvant chemoradiation with cisplatin. Given its tendency to metastasize early after definitive therapy, combining systemic chemotherapy with locoregional radiation is the logical approach to treatment [10–12]. Our patient progressed clinicoradiographically with worsening lesions in the lung and the brain after second line immunotherapy with pembrolizumab. Possible molecular genetic marker-based therapy targeting mutations involving PIK3CA in basaloid squamous cell carcinoma versus squamous cell carcinoma may provide a tailored therapeutic strategy as a treatment [14]. Despite aggressive treatment with 3 months of chemoradiation and 2 months of immunotherapy, our patient's health unfortunately continued to deteriorate and he passed away.

## Conclusions

The diagnosis of basaloid squamous cell carcinoma in the setting of intrapulmonary and brain metastases is an extremely rare, high-grade bimorphic aggressive variant of conventional

squamous cell carcinoma that needs to be histopathologically differentiated from other tumors containing basaloid components. Given its high mortality rate and poor prognosis the decision to pursue further treatment versus aggressive palliative care should be discussed.

## References:

1. Bauml J, Seiwert TY, Pfister DG et al: Pembrolizumab for platinum- and cetuximab-refractory head and neck cancer: Results from a single-arm, phase II study. *J Clin Oncol*, 2017; 35: 1542–49
2. Wain SL, Kier R, Vollmer RT, Bossen EH: Basaloid-squamous carcinoma of the tongue, hypopharynx, and larynx: Report of 10 cases. *Hum Pathol*, 1986;17: 1158–66
3. Chaidas K, Koltsidopoulos P, Kalodimos G, Skoulakis C: Basaloid squamous cell carcinoma of the tonsil. *Hippokratia*, 2012; 16: 74–75
4. Coletta RD, Cotrim P, Vargas PA et al: Basaloid squamous carcinoma of the oral cavity: Report of 2 cases and study of AgNOR, PCNA, p53, and MMP expression. *Oral Surg Oral Med Oral Pathol Oral Radiol Endod*, 2001; 91: 563–69
5. Ereño C, Gaafar A, Garmendia M et al: Basaloid squamous cell carcinoma of the head and neck: A clinicopathological and follow-up study of 40 cases and review of the literature. *Head Neck Pathol*, 2008; 2: 83–91
6. Heera R, Ayswarya T, Padmakumar SK, Ismayil P: Basaloid squamous cell carcinoma of oral cavity: Report of two cases. *J Oral Maxillofac Pathol*, 2016; 20: 545
7. Thompson L: Squamous cell carcinoma variants of the head and neck. *Current Diagnostic Pathology*, 2003; 9: 384–96
8. Ide F, Shimoyama T, Horie N, Kusama K: Basaloid squamous cell carcinoma of the oral mucosa: A new case and review of 45 cases in the literature. *Oral Oncol*, 2002; 38: 120–24
9. Ricciardiello F, Caraglia M, Iorio B et al: Aggressiveness pattern and second primary tumor risk associated with basaloid squamous cell carcinoma of the larynx. *Oncotarget*, 2017; (8)56: 95791–98
10. Winzenburg SM, Niehans GA, George E, Daly K, Adams GL: Basaloid squamous carcinoma: A clinical comparison of two histologic types with poorly differentiated squamous cell carcinoma. *Otolaryngol Head Neck Surg*, 1998; 119: 471–75
11. Sah K, Kale A, Hallikerimath S: Basaloid squamous cell carcinoma involving floor of the mouth. *J Oral Maxillofac Pathol*, 2008; 12: 61–63
12. Joshi NP, Hareesh KP, Das P et al: Unresectable basaloid squamous cell carcinoma of the trachea treated with concurrent chemoradiotherapy: A case report with review of literature. *J Cancer Res Ther*, 2010; 6: 321–23
13. Shibata Y, Baba E, Ariyama H et al: Metastatic basaloid-squamous cell carcinoma of the esophagus treated by 5-fluorouracil and cisplatin. *World J Gastroenterol*, 2007; 13(26): 3634–37
14. Baba Y, Ishimoto T, Harada K et al: Molecular characteristics of basaloid squamous cell carcinoma of the esophagus: Analysis of KRAS, BRAF, and PIK3CA mutations and LINE-1 methylation. *Ann Surg Oncol*, 2015; 22(11): 3659–65

## Department and Institution where work was done

Kern Medical Department of Medicine, Kern Medical Center, University of California, Los Angeles (UCLA), Bakersfield, CA, U.S.A.

## Conflicts of interest

None.