



# Exposure of the Middle Rectal Artery and Lateral Ligament of the Rectum Following the Gate Approach during Total Mesorectal Excision

Cristopher Varela<sup>1</sup>, Manar Nassr<sup>2</sup>, and Nam Kyu Kim<sup>3</sup>

<sup>1</sup>Coloproctology Unit, Department of General Surgery, Hospital Dr. Domingo Luciani, Caracas, Venezuela;

<sup>2</sup>Department of Colorectal Surgery, General Surgery Division, Royal Hospital, Muscat, Sultanate of Oman;

<sup>3</sup>Department of Surgery, Severance Hospital, Yonsei University College of Medicine, Seoul, Korea.

Controversial surgical anatomical landmarks in the deep pelvis can be visualized and identified using current technologies. Performing the gate approach technique during deep lateral dissection for total mesorectal excision facilitates visualization of the pelvic neurovascular structures following simple dissection steps to preserve the pelvic autonomic nerves and avoid accidental vascular injuries. Here, we discuss laparoscopic exposure of an infrequent disposition of the middle rectal artery anterior to the lateral ligament of the rectum while performing the gate approach.

**Key Words:** Rectal cancer surgery, gate approach to the pelvic floor, total mesorectal excision, deep anterolateral dissection

The middle rectal artery (MRA) and the lateral ligament of the rectum (LLR) have always been controversial surgical landmarks for rectal surgery.<sup>1</sup> Goligher<sup>2</sup> described LLR as a “roughly triangular structure with a base on the lateral pelvic wall joining the side of the rectum.” Lin, et al. describe LLR as a “bundle of dense connective tissue traversing between the rectum and visceral fascia instead of the pelvic sidewall.”<sup>3,4</sup> This bundle between the visceral and parietal fascia constantly contains the rectal branches of the pelvic plexus passing through the visceral fascia into the rectum, forming a continuous “hammock-like” sheath behind and lateral to the mesorectum.<sup>4</sup>

Historically, the running course of the MRA has been shown to be associated with the LLR and a lateral disposition, described as “an artery that penetrates the pelvic plexus from the

lateral side along with the lateral ligament,” with a frequency varying from 12% to 97%.<sup>1</sup> Still, it has been described in 20%–30% of cases as another type of “anterolateral MRA” that penetrates the neurovascular bundle and locates anterior to the LLR.<sup>5</sup>

The nervous component of the LLR was confirmed by Sato and Sato,<sup>6</sup> stating that nerves arising from the pelvic plexus are a constant component of the LLR and other fibrous tissues. Still, the frequency of the MRA in the LLR was only 22.2%.<sup>6</sup> Lin, et al.<sup>3</sup> findings by cadaver dissections describe a bilateral LLR present in all 32 cadavers, while a bilateral MRA was observed in only 28.1% (18/64 pelvic halves).

We present the finding of an anterolateral MRA and LLR during the “gate approach” dissection technique for rectal cancer mobilization during total mesorectal excision (TME) (Supplementary Video 1, only online). The gate approach facilitates preserving the neurovascular bundle,<sup>7</sup> located external to the junction of the visceral fascia and Denonvilliers’ fascia (DVF), and identifying the MRA when present (Fig. 1). This step is included in the anterolateral dissection of TME, starting behind DVF on the lateral side and detaching from the mesorectal fascia.<sup>7</sup> The dissection progresses to the deep pelvic floor, making a clear gate between the MRF and the pelvic floor. In addition to the deep posterior dissection, advancing in this surgical plane will leave the LLR and the upper soft connective tissue layer hanging like a bridge between the parietal and mesorectal

**Received:** November 24, 2021 **Revised:** December 30, 2021

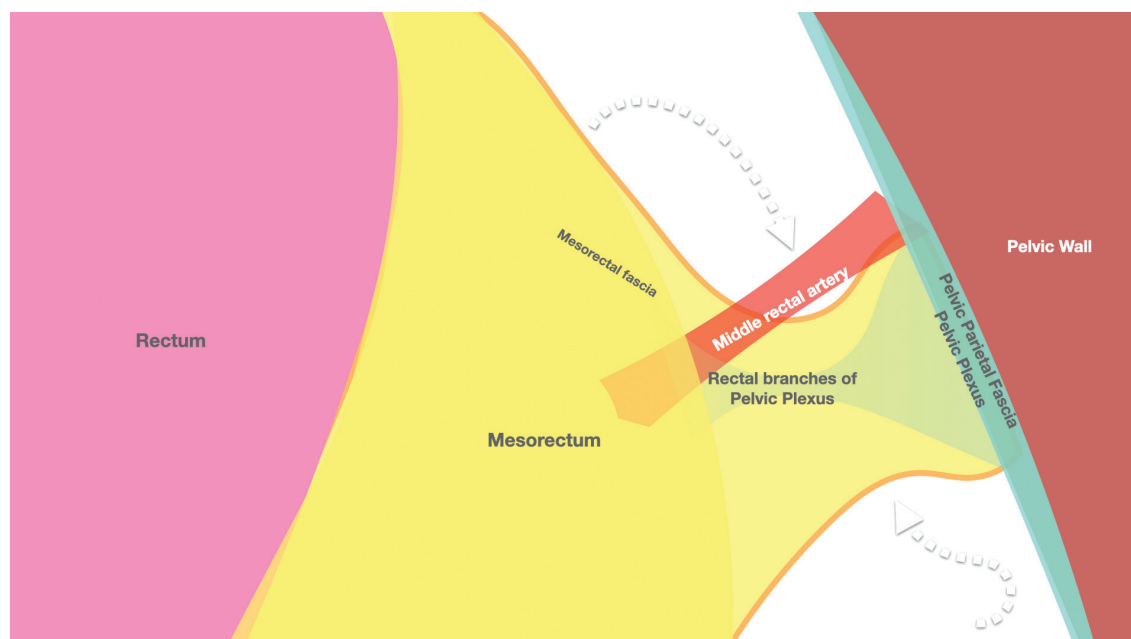
**Accepted:** January 11, 2022

**Corresponding author:** Nam Kyu Kim, MD, PhD, FACS, FRCS, FASCRS (Hon.), Department of Surgery, Severance Hospital, Yonsei University College of Medicine, 50-1 Yonsei-ro, Seodaemun-gu, Seoul 03722, Korea.  
Tel: 82-2-2228-2117, Fax: 82-2-313-8289, E-mail: namkyuk@yuhs.ac

•The authors have no potential conflicts of interest to disclose.

© Copyright: Yonsei University College of Medicine 2022

This is an Open Access article distributed under the terms of the Creative Commons Attribution Non-Commercial License (<https://creativecommons.org/licenses/by-nc/4.0>) which permits unrestricted non-commercial use, distribution, and reproduction in any medium, provided the original work is properly cited.



**Fig. 1.** Gate approach to the pelvic floor during lateral mobilization of the rectum.

fascia, where the dissection can proceed with ligation of the MRA, if present, while preserving the pelvic plexus within the parietal wall.

Surgeons have always referred to the LLR as an anatomical landmark for rectal excision since Miles' description in 1908 as a proper anatomical structure containing blood vessels, lymphatics, and nerve fibers that could be clamped, divided, and ligated during an abdominoperineal resection.<sup>8</sup> Goligher<sup>2</sup> also addressed the LLR as a palpable structure that could be hooked by the middle and index fingers of the left hand and then sharply incised on the lateral sides of the lower rectum. No controversy was initially raised regarding the LLR during the first descriptions of open rectal resection. With modern studies and new interpretations of the pelvic anatomy, however, especially with the development of TME by Heald,<sup>9</sup> the existence of LLR has been questioned.

The non-existence of LLR was proposed by Jones, et al.,<sup>10</sup> suggesting the term should be dropped from surgical texts after performing dissection in the mesorectal plane on 28 cadaveric pelvises and finding no lateral connective tissue in 10/28 cadavers and 17 unilateral MRAs. The authors ultimately concluded that the entire rectum may be mobilized by sharp dissection without the need for clamping or ligation of any significant structure during TME.

The upper part of the LLR has been defined by Nano, et al.<sup>5</sup> as an artifact due to not strictly mobilizing the rectum between the rectal visceral and pelvic parietal fascia. The described the LLR as being conformed by extensions of the mesorectum that must be cut at their attachment at the endopelvic fascia following the surgical plane of a continuous, soft connective tissue layer containing no actual ligation structures and possibly some

vessels and nerve filaments that are of little importance.

Another anatomical study by Lin, et al.<sup>3</sup> proposed a different location for the LLR, based on dissections of 32 cadavers, and reported that the LLR constantly appeared as a bundle of dense connective tissues traversing between the rectum and visceral fascia at the level of the ischial spine, instead of emerging from the pelvic sidewall. One constant component of the LLR was the rectal branches from the pelvic plexus. An MRA was observed in only 18 of 32 pelvises. No substantial tissue strand, except for pelvic splanchnic nerves, was found between visceral fascia and parietal fascia at the same level, allowing for sharp mobilization of the rectum in the TME plane. This study proposes using LLR as a clinical anatomical landmark of the appropriate surgical plane, meaning that if it is visualized during dissection, the surgical plane ought to be medial to the visceral fascia compromising the mesorectal integrity.

A critical review of current controversies by Wang, et al.,<sup>4</sup> based on surgical observation, concluded that the LLR is a constant anatomical structure of connective tissue bundles running between the rectal visceral fascia and the pelvic parietal fascia that terminates in the distal part of the rectum laterally, much lower than thought, and is covered by the superior fascia of the pelvic diaphragm above the levator ani and containing nerve fibers and the MRA.

From a surgical standpoint, performing deep rectal mobilization with the gate approach facilitates the identification of the condensed connective tissue forming the LLR during anterolateral dissection and the visualization of different variations of the MRA when present while preserving the pelvic autonomic nervous plexus.<sup>7</sup> Although the concept of the LLR has been in constant evolution, we believe the advances in surgical

technologies for laparoscopic and robotic dissection that permit better visualization of the deep pelvic structures will help clarify classic anatomic controversies and improve rectal cancer surgery outcomes.

## SUPPLEMENTARY DATA

Video 1. Laparoscopic rectal mobilization and exposure of the middle rectal artery and lateral ligament of the rectum following the gate approach during total mesorectal excision.

## AUTHOR CONTRIBUTIONS

**Conceptualization:** Cristopher Varela. **Data curation:** Manar Nasser. **Formal analysis:** Cristopher Varela. **Funding acquisition:** all authors. **Investigation:** Cristopher Varela. **Methodology:** Manar Nasser. **Project administration:** Cristopher Varela. **Resources:** Nam Kyu Kim. **Software:** Cristopher Varela. **Supervision:** Nam Kyu Kim. **Validation:** Nam Kyu Kim. **Visualization:** Nam Kyu Kim. **Writing—original draft:** Cristopher Varela. **Writing—review & editing:** Manar Nasser. **Approval of final manuscript:** all authors.

## ORCID iDs

Cristopher Varela <https://orcid.org/0000-0001-6353-0461>  
Manar Nassr <https://orcid.org/0000-0003-1405-5865>  
Nam Kyu Kim <https://orcid.org/0000-0003-0639-5632>

## REFERENCES

1. Kiyomatsu T, Ishihara S, Murono K, Otani K, Yasuda K, Nishikawa T, et al. Anatomy of the middle rectal artery: a review of the historical literature. *Surg Today* 2017;47:14-9.
2. Goligher JC. Surgical treatment. *Br Med J* 1971;1:653-5.
3. Lin M, Chen W, Huang L, Ni J, Yin L. The anatomy of lateral ligament of the rectum and its role in total mesorectal excision. *World J Surg* 2010;34:594-8.
4. Wang GJ, Gao CE, Wei D, Wang C, Meng WJ. Anatomy of the lateral ligaments of the rectum: a controversial point of view. *World J Gastroenterol* 2010;16:5411-5.
5. Nano M, Dal Corso HM, Lanfranco G, Ferronato M, Hornung JP. Contribution to the surgical anatomy of the ligaments of the rectum. *Dis Colon Rectum* 2000;43:1592-7.
6. Sato K, Sato T. The vascular and neuronal composition of the lateral ligament of the rectum and the rectosacral fascia. *Surg Radiol Anat* 1991;13:17-22.
7. Sauri F, Cho MS, Kim NK. Gate approach at deep anterolateral pelvic dissection. *Surg Oncol* 2021;37:101535.
8. Miles WE. A method of performing abdomino-perineal excision for carcinoma of the rectum and of the terminal portion of the pelvic colon. *Lancet* 1908;172:1812-3.
9. Heald RJ. A new approach to rectal cancer. *Br J Hosp Med* 1979;22:277-81.
10. Jones OM, Smeulders N, Wiseman O, Miller R. Lateral ligaments of the rectum: an anatomical study. *Br J Surg* 1999;86:487-9.