



Contents lists available at ScienceDirect

International Journal of Surgery Case Reports

journal homepage: www.casereports.com

Successful treatment of nonocclusive mesenteric ischemia after aortic valve replacement with continuous arterial alprostadil infusion: A case report



Kunio Ogi^a, Masamitsu Sanui^{a,*}, Yusuke Iizuka^a, Akinori Aomatsu^a, Ikue Nakashima^a, Kohei Hamamoto^b, Tomohisa Okochi^b, Alan K. Lefor^c

^a Department of Anesthesiology and Critical Care Medicine, Jichi Medical University Saitama Medical Center, 1-847 Amanumacho, Omiyaku, Saitama, Saitama, 330-8503, Japan

^b Department of Radiology, Jichi Medical University Saitama Medical Center, 1-847 Amanumacho, Omiyaku, Saitama, Saitama, 330-8503, Japan

^c Department of Surgery, Jichi medical University, 3311-1 Yakushiji, Shimotsuke, Tochigi, 329-0498, Japan

ARTICLE INFO

Article history:

Received 19 December 2016

Received in revised form 28 March 2017

Accepted 28 March 2017

Available online 30 March 2017

Keywords:

Nonocclusive mesenteric ischemia

Papaverine

Prostaglandin E1

Aortic valve replacement

Postoperative complications

ABSTRACT

INTRODUCTION: Nonocclusive mesenteric ischemia (NOMI) after surgery has an extremely poor prognosis with a mortality rate of 30–100%. We report a patient with NOMI following aortic valve replacement who failed to improve despite continuous intra-arterial infusion of papaverine, but was successfully treated with alprostadil (prostaglandin E1 [PGE1]) infusion.

PRESENTATION OF CASE: The patient is a 77-year-old man who underwent aortic valve replacement. Due to elevated serum lactate levels five hours after intensive care unit admission, superior mesenteric arteriography was performed, establishing the diagnosis of NOMI. Although continuous intra-arterial infusion of papaverine was begun, lactate levels remained elevated. Repeat angiography and laparotomy revealed extensive ischemic changes of the intestine. The vasodilator was changed to PGE1, which improved arterial spasm. The patient ultimately needed an ileocecal resection, but the extent of the resection was limited with concomitant PGE1 administration.

DISCUSSION: In the present patient, although NOMI was unresponsive to appropriate treatment including intra-arterial infusion of papaverine, continuous intra-arterial infusion of PGE1 salvaged most of the intestine.

CONCLUSIONS: In a patient with recurrent NOMI despite appropriate treatment including intra-arterial infusion of papaverine, continuous intra-arterial infusion of PGE1 may limit the extent of intestinal resection needed. Continuous intra-arterial infusion of PGE1 may be a useful treatment for patients with refractory NOMI.

© 2017 The Authors. Published by Elsevier Ltd on behalf of IJS Publishing Group Ltd. This is an open access article under the CC BY-NC-ND license (<http://creativecommons.org/licenses/by-nc-nd/4.0/>).

1. Introduction

Nonocclusive mesenteric ischemia (NOMI) is a condition in which mesenteric artery spasm causes ischemia and necrosis of the intestine in the absence of vascular obstruction. Although the incidence of NOMI following open heart surgery is as low as 0.2–2%, the prognosis is extremely poor with a mortality rate of 30–100%

[1–4]. It has been suggested that early detection and prompt intervention may improve the outcomes [5]. We report a patient who developed NOMI following aortic valve replacement who failed to improve despite continuous intra-arterial infusion of papaverine, but was successfully treated with alprostadil (prostaglandin E1 [PGE1]) infusion. This work has been reported in line with the SCARE criteria [6].

2. Presentation of case

The patient is a 77-year-old man who underwent aortic valve replacement for aortic stenosis. The operative time was 9 h and 23 min, and the cardiopulmonary bypass time was 257 min. He was admitted to the intensive care unit (ICU) postoperatively.

At the time of ICU admission, the serum lactate level was 2.92 mmol/L, but 5 h after ICU admission, the serum lactate markedly increased to 10.96 mmol/L, raising suspicion for the

Abbreviations: NOMI, nonocclusive mesenteric ischemia; PGE1, Prostaglandin E1; ICU, Intensive Care Unit; CT, Computed Tomography; SMA, superior mesenteric artery.

* Corresponding author.

E-mail addresses: kogi0430@gmail.com (K. Ogi), msanui@mac.com, msanui.jichi@gmail.com (M. Sanui), zucarinn@gmail.com (Y. Iizuka), ayksera@gmail.com (A. Aomatsu), queue323@yahoo.co.jp (I. Nakashima), hkouhei917@yahoo.co.jp (K. Hamamoto), t.shachi@dj8.so-net.ne.jp (T. Okochi), alefor@jichi.ac.jp (A.K. Lefor).

<http://dx.doi.org/10.1016/j.ijscr.2017.03.037>

2210-2612/© 2017 The Authors. Published by Elsevier Ltd on behalf of IJS Publishing Group Ltd. This is an open access article under the CC BY-NC-ND license (<http://creativecommons.org/licenses/by-nc-nd/4.0/>).

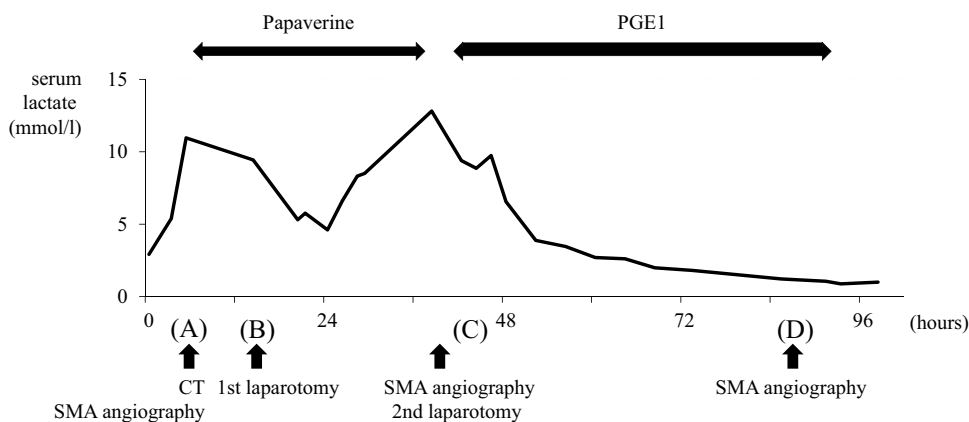


Fig. 1. The serum lactate levels and clinical course in the Intensive Care Unit.

development of intestinal ischemia. Contrast-enhanced computed tomography (CT) scan of the abdomen and angiography of the superior mesenteric artery (SMA) were performed (Fig. 1(A)). Although there was no evidence of occlusion of the SMA on the CT scan, poor contrast enhancement was found in some areas of the small intestine with narrowing and blocking of distal branches of the SMA (Fig. 2), leading to the diagnosis of NOMI. Continuous intra-arterial infusion of papaverine was started via a catheter placed in the SMA.

Despite a 9-h infusion of papaverine, the serum lactate level was still 9.46 mmol/L. Emergent exploratory laparotomy was then performed (Fig. 1(B)), with no obvious ischemic changes of the intestine seen intraoperatively. Postoperatively, the intra-arterial infusion of papaverine was continued, with moderate improvement in serum lactate level. However, serum lactate level again increased markedly to 12.81 mmol/L after 33 h of intra-arterial infusion therapy. Angiography was performed again, which showed diffuse narrowing and lack of flow in distal branches of the SMA with suspicion of dislocation of the intra-arterial infusion catheter. During the procedure, a trial of alprostadil injection into the SMA was performed, resulting in dilatation of narrowed arteries. The decision was made to perform a second exploratory laparotomy (Fig. 1(C)). Intraoperative findings showed ischemic

changes in the celiac artery distribution extending from the stomach to the descending limb of the duodenum with extensive segmental ischemic changes in the SMA distribution (Fig. 3), but no areas appeared to require resection at that time. The decision was made to leave the abdomen open with continuous intra-arterial infusion of alprostadil postoperatively. Lactate levels decreased and eventually returned to a normal level of 1.44 mmol/L with no symptoms suggestive of intestinal necrosis after 48 h of infusion. Another angiography study showed no narrowing or arterial obstruction (Fig. 1(D)). Eight days after the second operation, inspection of the bowel during abdominal wall closure revealed no ischemic changes of the intestinal tract. The patient was discharged from the ICU two days later.

However, the patient developed fever and right lower quadrant abdominal pain two days following ICU discharge. A third laparotomy was performed, and ileal necrosis was found 20 cm proximal to the ileocecal valve, requiring resection and ileostomy. Postoperatively, the patient was admitted to the ICU for continuous intra-arterial infusion of alprostadil for another 48 h. The patient was discharged to a chronic care facility 62 days after the original operation.

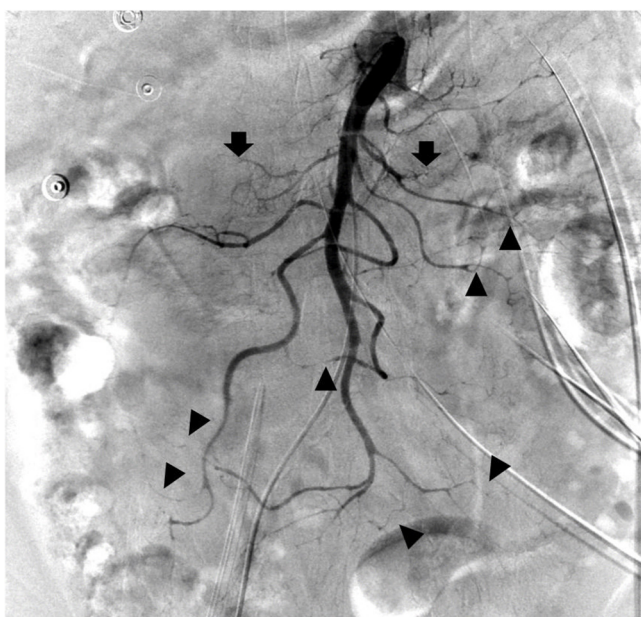

Fig. 2. Superior mesenteric arteriography. Superior mesenteric arteriography shows discontinuous flow (arrow) with multiple areas of stenosis (arrow heads).

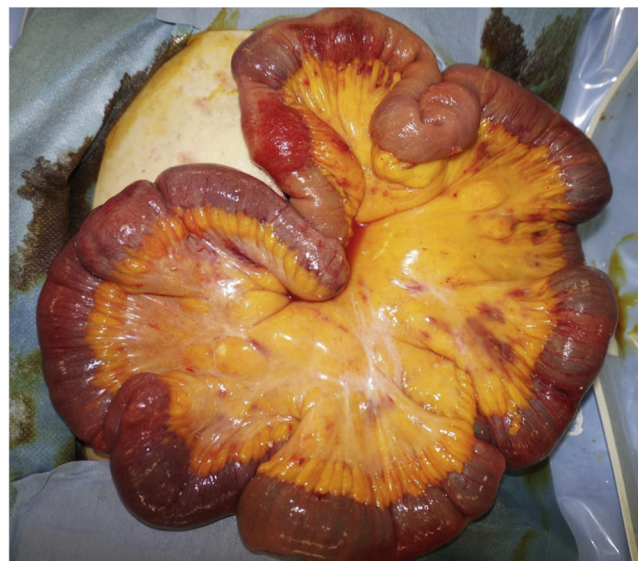

Fig. 3. Intraoperative findings at the second laparotomy, 38 h after Intensive Care Unit admission. Extensive segmental ischemia is observed.

3. Discussion

We present a patient who developed NOMI after aortic valve replacement but survived after receiving continuous intra-arterial infusion of alprostadil and three laparotomies. Continuous intra-arterial administration of a vasodilator through an indwelling abdominal angiographic catheter is considered to be the first-line treatment of NOMI, and papaverine is commonly used [3,4,7].

Papaverine was initially used in this patient at the time of establishing the diagnosis of NOMI. The serum lactate levels temporarily decreased but increased again, together with extensive ischemic changes not amenable to resection. During the second arteriography procedure, although a dislocation of the catheter could not be ruled out, we raised the possibility that NOMI in this case was not responsive to papaverine infusion, and selected intra-arterial infusion therapy with PGE1 after documenting that this patient was a PGE1 responder.

After intravenous administration, 68% of PGE1 is metabolized in the lung, while the remaining unmetabolized portion acts on prostanoid receptors of the vascular smooth muscle to increase intracellular cAMP, thus exerting a vasodilatory effect. PGE1 not only inhibits platelet aggregation but also improves peripheral circulation. These effects are also observed after systemic administration of PGE1, and PGE1 is usually administered at a dose of 10–15 µg/day in patients with chronic peripheral arterial disease [8].

There have been sporadic reports describing PGE1 therapy for patients with NOMI. A search of PubMed using keywords of “alprostadil” and “acute mesenteric ischemia” identified four studies. Mitsuyoshi et al. [5] reported that surgery was performed for 11 of 13 patients who were not given PGE1 and only four of them survived, whereas surgery was not required in eight of nine patients who were given systemic intravenous administration of PGE1 (0.03 µg/kg/min) and seven of them survived. In addition, Kamimura et al. [9] reported three patients treated successfully with the systemic intravenous administration of PGE1 (0.01 µg/kg/min). Weiss et al. [10] reported that patients given an intra-arterial infusion of PGE1 at a dose of 40 µg/day via an arterial catheter placed in the SMA survived. They concluded that intra-arterial infusion therapy with PGE1 is the only effective treatment for patients with NOMI.

In the present patient, a second-look laparotomy revealed unresectable extensive ischemic changes in the small intestine. However, when intra-arterial PGE1 was administered at a dose of 40 µg/day through a catheter in the celiac artery and the SMA, the serum lactate level markedly improved. A third-look laparotomy also revealed improvement in the previously ischemic areas. Thus, intra-arterial infusion therapy with PGE1 appears to be a very promising treatment.

According to the literature, systemic intravenous administration of PGE1 requires a massive dose (720–2160 µg/day in patients weighing 50 kg) [5,9]. Currently, this drug is not approved for the treatment of NOMI, which suggests that the drug cost should be borne by the hospital under the rules of the Japanese National Health Insurance system. However, because this patient survived after receiving an intra-arterial infusion of PGE1 at a dose of 40 µg/day according to the method of Weiss et al., we believe that intra-arterial infusion therapy is a more cost-effective treatment of NOMI than its intravenous administration. Further studies are needed to verify or refute this concept.

When NOMI is associated with intestinal necrosis, the standard treatment is resection of the necrotic area. Postoperatively, however, the remaining intestine is susceptible to subsequent ischemic changes, and additional resections are often required [11,12]. In this patient, intestinal resection was eventually required, but the extent of resection was limited most likely because blood flow to

the ischemic area was improved by the potent vasodilating effect of PGE1. A strategy of continuous PGE1 administration combined with second-look surgery appears to be useful for avoiding intestinal resection or by limiting the extent of resection when resection is necessary.

4. Conclusion

In a patient with recurrent NOMI despite appropriate treatment including intra-arterial infusion of papaverine, continuous intra-arterial infusion of PGE1 may limit the extent of intestinal resection needed. Continuous intra-arterial infusion of PGE1 may be a useful treatment for patients with refractory NOMI.

Conflict of interest

The authors declare that they have no competing interest.

Sources of Funding

This research did not receive any specific grant from funding agencies in the public, commercial, or not-for-profit sectors.

Ethical approval

Not required for case report per the IRB policy. The patient has been informed and provided explicit consent to the presentation of this case report.

Consent

A written and signed consent was obtained from the patient for publication of the information and the images. The signed consent form is available upon the Editor's request.

Author's contribution

KO, AA and IN performed the literature review, compiled the case report and discussion, and reviewed and selected the relevant images.

KO and MS drafted the manuscript.

MS, KH, TO, YI and AL revised the manuscript critically for important intellectual content.

All authors have read and approved the final manuscript.

Registration of research studies

This research was registered at Research Registry (researchregistry#1202).

Guarantor

Masamitsu Sanui, M.D., Ph.D.

References

- [1] A. Schutz, W. Eichinger, M. Breuer, B. Gansera, B. Kemkes, Acute mesenteric ischemia after open heart surgery, *Angiography* 49 (1998) 267–273.
- [2] A. Eker, B. Malzac, J. Teboul, J. Jourdan, Mesenteric ischemia after coronary bypass grafting: should local continuous intra-arterial perfusion with papaverine be regarded as a treatment, *Eur. J. Cardiothorac. Surg.* 15 (1999) 218–220.
- [3] S. Klotz, T. Vestring, J. Rotker, C. Schmidt, H. Scheld, C. Schmid, Diagnosis and treatment of nonocclusive mesenteric ischemia after open heart surgery, *Ann. Thorac. Surg.* 72 (2001) 1583–1586.
- [4] H. Huwer, J. Winning, U. Straub, H. Isringhaus, G. Kalweit, Clinically diagnosed nonocclusive mesenteric ischemia after cardiopulmonary bypass-retrospective study, *Vascular* 12 (2004) 114–120.

- [5] K. Mitsuyoshi, A. Oosaki, N. Shinkura, T. Ito, M. Zaima, Survival in nonocclusive mesenteric ischemia: early diagnosis by multidetector row computed tomography and early treatment with continuous intravenous high-dose prostaglandin E(1), *Ann. Surg.* 246 (2007) 229–235.
- [6] R.A. Agha, A.J. Fowler, A. Saeta, I. Barai, S. Rajmohan, Orgill DP; SCARE Group: The SCARE Statement: Consensus-based surgical case report guidelines, *Int. J. Surg.* 34 (2016) 180–186.
- [7] S.J. Boley, S. Sprayregan, S.S. Siegelman, F.J. Veith, Initial results from an aggressive roentgenological and surgical approach to acute mesenteric ischemia, *Surgery* 82 (1977) 848–855.
- [8] M. Golub, P. Zia, M. Matsuno, R. Horton, Metabolism of prostaglandins A1 and E1 in man, *J. Clin. Invest.* 56 (1975) 1404–1410.
- [9] K. Kamimura, A. Oosaki, S. Sugahara, S. Mori, Survival of three nonocclusive mesenteric ischemia patients following early diagnosis by multidetector row computed tomography and prostaglandin E1 treatment, *Intern. Med.* 47 (2008) 2001–2006.
- [10] G. Weiss, H. Lippert, F. Meyer, Successful management of non-occlusive mesenteric ischemia (NOMI)-case report, *Pol. Przegl. Chir.* 84 (2012) 214–218.
- [11] W.M. Park, P. Gloviczki, K.J. Cherry Jr., J.W. Hallett Jr., T.C. Bower, J.M. Panneton, et al., Contemporary management of acute mesenteric ischemia: factors associated with survival, *J. Vasc. Surg.* 35 (2002) 445–452.
- [12] D. Ward, A.M. Vernava, D.L. Kaminski, T. Ure, G. Peterson, P. Garvin, et al., Improved outcome by identification of high-risk nonocclusive mesenteric ischemia, aggressive reexploration, and delayed anastomosis, *Am. J. Surg.* 170 (1995), 577–80; discussion 580–1.

Open Access

This article is published Open Access at [sciencedirect.com](https://www.sciencedirect.com). It is distributed under the [IJSCR Supplemental terms and conditions](#), which permits unrestricted non commercial use, distribution, and reproduction in any medium, provided the original authors and source are credited.