



A coronary cameral fistula treated with coil embolization

Ethan D Hinds III¹, Manuel J Marin III², Joggy George² and Reynolds Delgado III² 

Abstract

A 56-year-old man who had twice previously undergone orthotopic heart transplantation was admitted with dyspnea and heart failure symptoms. A biopsy excluded rejection. Left heart catheterization revealed a coronary cameral fistula. After the patient was given mild diuretics, his condition improved. No significant fistula flow was detected, and he was discharged. Several months later, the patient was readmitted with worsening chest pain and dyspnea. Left ventricular end-diastolic pressure and flow through the fistula were increased. To correct the coronary cameral fistula, we performed a coil embolization without complications. Several months later at follow-up, the patient's symptoms had resolved, and his left ventricular end-diastolic pressure had normalized. We conclude that coronary fistulas may be caused by trauma to the heart during the de-airing process, which may be prevented in the future with the development of safer and more effective de-airing techniques.

Keywords

Coronary cameral fistula, coil embolization, de-airing, heart failure, heart transplant

Received 2 January 2019; Revised received 21 May 2019; accepted 22 May 2019

Introduction

Although coronary fistulas have been reported, few sources have considered their origin and prevention. Even fewer sources have considered coronary cameral fistulas (CCF), which remain under-reported, and imaging to characterize their pathogenesis has been lacking. We describe a heart transplant recipient with a symptomatic CCF masquerading as rejection and the use of coil embolization as treatment.

Case report

A 56-year-old man who had previously undergone a redo orthotopic heart transplantation was hospitalized for suspected rejection after a routine catheterization showed abnormal hemodynamics. Ischemic cardiomyopathy led to his first orthotopic transplantation, which lasted 10 years. The patient's medical history included thyroid disease, diabetes mellitus, renal insufficiency, and hypertension. His family history was significant for heart disease in both parents, including paternal myocardial infarction.

Right and left heart catheterizations revealed elevated left ventricular (LV) end-diastolic pressure and right ventricular end-diastolic pressure. A coronary

angiogram showed a CCF (Figure 1). A cardiac biopsy was graded 1R, indicating mild rejection with a negative C4D result.¹ The possibility that the patient's LV dysfunction was due to the CCF rather than organ rejection was considered. The patient underwent gentle diuresis and was discharged after symptom resolution.

Three months later, the patient presented to the emergency department with chest pain and dyspnea at rest. Right heart catheterization revealed pulmonary hypertension and elevated pulmonary capillary wedge pressure, and a coronary angiogram showed increased flow from the CCF, with dye filling nearly the entire left ventricle (Figure 1; online supplemental Video 1).

Coil embolization was performed as follows. After vascular access to the right common femoral artery was established, a 6-Fr sheath was placed without difficulty. Anticoagulation with heparin was initiated and

¹School of Medicine, University of Texas Medical Branch, Galveston, USA

²Center for Clinical Research, Texas Heart Institute, Houston, USA

Corresponding author:

Reynolds Delgado III, 6624 Fannin St., Suite 1910, Houston, TX 77030, USA.

Email: RDelgado@texasheart.org



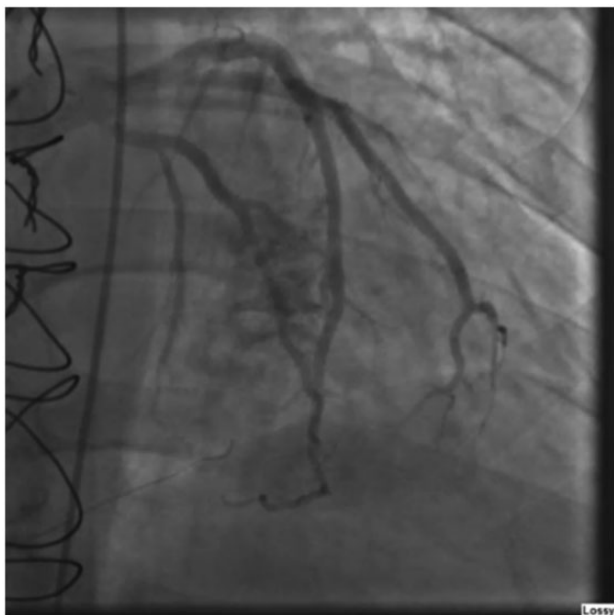


Figure 1. Still image from the coronary angiogram showing the patient's coronary cameral fistula at the time of the index admission.

adjusted as necessary. A 6-Fr XBLAD 3.5 guiding catheter (Cordis Corp., Milpitas, CA) was advanced over a J-tipped wire to the ascending aorta. The J-tipped wire was removed, and the catheter was aspirated and flushed. The guiding catheter was placed into the left main ostium. A 0.014" Hi-Torque Balance Middle Weight (Abbott Vascular, Chicago, IL) guide wire was inserted into the guiding catheter and advanced into the septal perforators from the left anterior descending artery from which the fistula originated. A Renegade microcatheter (Boston Scientific, Marlborough, MA) was advanced over the wire and placed into the septal branch where the fistula originated. A 3 × 50-mm Azur 18 detachable coil (Terumo Corp., Tokyo, Japan) was advanced over the microcatheter and was deployed in the same septal branch without complications. A 2 × 20-mm Azur 18 detachable coil (Terumo Corp.) was advanced and deployed in the same segment. A 3 × 50-mm Azur detachable coil (Terumo Corp.) was advanced and deployed in the septal branch, with care not to disturb the left anterior descending artery.

After coil deployment, an angiogram showed adequate coil positioning without dissection or distal embolization. Flow in the CCF was significantly reduced, and thrombolysis in myocardial infarction grade 3 flow was detected in the distal left anterior descending artery, indicating normal perfusion. The wire was then removed from the coronary artery, and the guiding catheter was disengaged and removed over a J-wire. The sheath was aspirated and flushed,

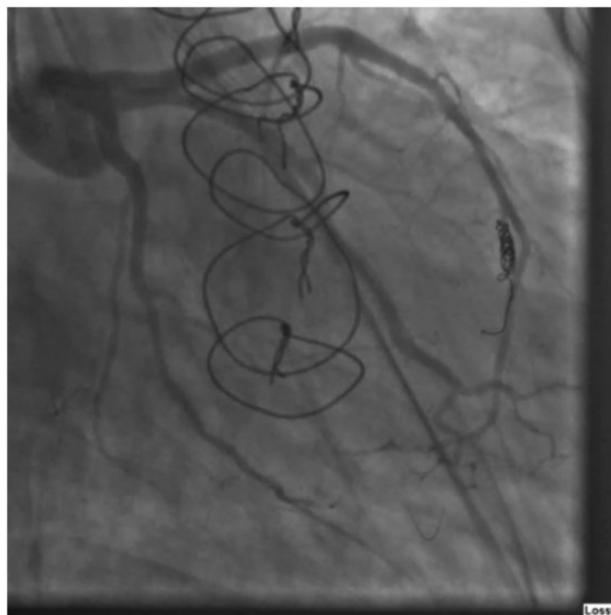


Figure 2. Still image from the coronary angiogram showing the patient's coronary cameral fistula 14 months after being corrected through coil embolization.

and the patient was sent to the holding area in stable condition.

The procedure was completed without complication. The patient was hemodynamically stable throughout the procedure. The postoperative plan was to monitor the patient in the coronary care unit for hemodynamic status and complications while optimizing medical therapy and aggressively controlling for cardiovascular risk factors.

Fourteen months after discharge, the patient underwent a surveillance procedure that indicated minimal flow in the fistula and normal hemodynamics. Imaging of the coronary arteries (Figure 2; online supplemental Video 2) confirmed successful coil embolization.

Discussion

In a previous study,² coronary fistulas occurred in 4 out of 74 (5.4%) heart transplant recipients, a rate higher than the expected congenital rate of 0.1% to 0.2%. The authors hypothesized that coronary fistulas may result from endomyocardial biopsies performed on the right ventricle and are therefore unlikely to be prevented.² However, an LV biopsy was not analyzed for our patient. Furthermore, the acuity of his symptoms indicated that the CCF was not congenital in the donor heart. Therefore, we believe that our patient may have acquired the CCF during transplantation. Previously, Hermoni et al.³ described a patient who inserted needles into his own heart and created an LV CCF, suggesting that puncturing the heart with needles

such as those used in the de-airing process during heart transplantation can cause a CCF. Others⁴ have reported that traumatic CCFs are rare but can be acquired as complications of surgical procedures and traumas. Thus, iatrogenic CCFs are a risk of performing orthotopic heart transplantation.

CCFs that result from orthotopic heart transplantation can be avoided by continuing to make improvements in the de-airing process. New and effective de-airing procedures and devices that eliminate needle aspiration are presently being developed. Al-Rashidi et al.⁵ showed that inducing bilateral pulmonary collapse before mechanical ventilation of the left side of the heart significantly reduced de-airing time ($P < 0.001$) and microembolic signal formation ($P < 0.001$). This technique may be used by surgeons to reduce the incidence of coronary fistulas caused by trauma during the de-airing process. Svenarud et al.⁶ have described carbon dioxide insufflation as an alternative method. Carbon dioxide has better solubility and toleration in the blood than does air. Carbon dioxide also has a greater density than air, allowing it to displace air in the wound. The CarbonAid designed by Cardia Innovation AB (Stockholm, Sweden) improves upon previous carbon dioxide insufflation devices, which could fill only 20% to 80% of the wound, by attaining carbon dioxide concentrations greater than 98.65% at a 5-L/min flow, making it a viable alternative for de-airing the heart.^{6,7}

Conclusion

Our patient who presented with symptoms of heart transplant rejection was successfully treated for a CCF with coil embolization. Several months later, resolution was confirmed on follow-up. After considering various causes of coronary fistulas, we conclude that CCFs may be caused by trauma to the heart during the de-airing process in heart transplant patients and may be prevented with safer and more effective de-airing techniques.

Acknowledgements

Nicole Stancel, PhD, ELS, of Scientific Publications at the Texas Heart Institute, provided editorial support. James Philpot and Joseph Brewton provided assistance with the videos.

Contributorship

Ethan Hinds and Manuel Marin wrote the manuscript. Manuel Marin procured images. Ethan Hinds coordinated the submission and preparation of manuscript. Joggy George, MD, performed the coil embolization and reviewed the manuscript. Reynolds Delgado, MD, saw the patient throughout his clinical course and reviewed the manuscript.

All authors read and approved the final manuscript before submission.

Declaration of conflicting interests

The authors declared the following potential conflicts of interest with respect to the research, authorship, and/or publication of this article: Dr. George is an advisor and speaker for Abiomed. He is also a consultant and speaker for Novartis and Zoll Medical.

Ethical approval

Per ICMJE guidelines and the Helsinki Declaration (2013 revision), nonessential identifying details were omitted, and anonymity is maintained in our manuscript.

Funding

The authors received no financial support for the research, authorship, and/or publication of this article.

Guarantor

Reynolds Delgado, MD.

ORCID iD

Reynolds Delgado III  <https://orcid.org/0000-0002-1169-8702>

Supplemental Material

Supplemental videos for this article is available online.

References

1. Billingham M and Kobashigawa JA. The revised ISHLT heart biopsy grading scale. *J Heart Lung Transplant* 2005; 24: 1709.
2. Henzlova MJ, Nath H, Bucy RP, et al. Coronary artery to right ventricle fistula in heart transplant recipients: a complication of endomyocardial biopsy. *J Am Coll Cardiol* 1989; 14: 258–261.
3. Hermoni Y, Engel PJ and Gallant TE. Sequelae of injury to the heart caused by multiple needles. *J Am Coll Cardiol* 1986; 8: 1226–1231.
4. Sheikhi MA, Asgari M, Firouzabadi MD, et al. Traumatic left anterior descending coronary artery-right ventricle fistula: a case report. *J Tehran Heart Cent* 2011; 6: 92–94.
5. Al-Rashidi F, Blomquist S, Høglund P, et al. A new de-airing technique that reduces systemic microemboli during open surgery: a prospective controlled study. *J Thorac Cardiovasc Surg* 2009; 138: 157–162.
6. Svenarud P, Persson M and van der Linden J. Effect of CO₂ insufflation on the number and behavior of air microemboli in open-heart surgery: a randomized clinical trial. *Circulation* 2004; 109: 1127–1132.
7. Chaudhuri K, Storey E, Lee GA, et al. Carbon dioxide insufflation in open-chamber cardiac surgery: a double-blind, randomized clinical trial of neurocognitive effects. *J Thorac Cardiovasc Surg* 2012; 144: 646–653.e1.