

Original Article

# Describing a new syndrome in L5-S1 disc herniation: Sexual and sphincter dysfunction without pain and muscle weakness

Nezih Akca<sup>1</sup>, Bulent Ozdemir<sup>2</sup>, Ayhan Kanat<sup>2</sup>, Osman Ersagun Batcik<sup>2</sup>, Ugur Yazar<sup>3</sup>, Orhan Unal Zorba<sup>1</sup>

<sup>1</sup>Departments of Urology, and <sup>2</sup>Neurosurgery, Faculty of Medical, Recep Tayyip Erdogan University, Rize, <sup>3</sup>Department of Neurosurgery, Karadeniz Technical University, Faculty of Medical, Trabzon, Turkey

Corresponding author: Dr. Ayhan Kanat, Department of Neurosurgery, Faculty of Medical, Recep Tayyip Erdogan University, Merkez - 53100, Rize, Turkey.  
E-mail: [ayhankanat@yahoo.com](mailto:ayhankanat@yahoo.com)

Journal of Craniovertebral Junction and Spine 2014, 5:37

## Abstract

**Context:** Little seems to be known about the sexual dysfunction (SD) in lumbar intervertebral disc herniation. **Aims:** Investigation of sexual and sphincter dysfunction in patient with lumbar disc herniations. **Settings and Design:** A retrospective analysis. **Materials and Methods:** Sexual and sphincter dysfunction in patients admitted with lumbar disc herniations between September 2012-March 2014. **Statistical Analysis Used:** Statistical analysis was performed using the Predictive Analytics SoftWare (PASW) Statistics 18.0 for Windows (Statistical Package for the Social Sciences, SPSS Inc., Chicago, Illinois). The statistical significance was set at  $P < 0.05$ . The Wilcoxon signed ranks test was used to evaluate the difference between patients. **Results:** Four patients with sexual and sphincter dysfunction were found, including two women and two men, aged between 20 and 52 years. All of them admitted without low back pain. In addition, on neurological examination, reflex and motor deficit were not found. However, almost all patients had perianal sensory deficit and sexual and sphincter dysfunction. Magnetic resonance imaging (MRI) of three patients displayed a large extruded disc fragment at L5-S1 level on the left side. In fourth patient, there were not prominent disc herniations. There was not statistically significant difference between pre-operative and post-operative sexual function, anal-urethral sphincter function, and perianal sensation score. A syndrome in L5-S1 disc herniation with sexual and sphincter dysfunction without pain and muscle weakness was noted. We think that it is crucial for neurosurgeons to early realise that paralysis of the sphincter and sexual dysfunction are possible in patients with lumbar L5-S1 disc disease. **Conclusion:** A syndrome with perianal sensory deficit, paralysis of the sphincter, and sexual dysfunction may occur in patients with lumbar L5-S1 disc disease. The improvement of perianal sensory deficit after surgery was counteracted by a trend toward disturbed sexual function. Further researches are needed to explore the extent of this problem.

**Key words:** Sphincter dysfunction, lumbar disc herniation, sexual dysfunction

Access this article online	
Quick Response Code:	Website: <a href="http://www.jcvjs.com">www.jcvjs.com</a>
	DOI: 10.4103/0974-8237.147076

## INTRODUCTION

Low back pain (LBP) is one of the most common problems<sup>[1-3]</sup>, and herniated lumbar disc is one of the most commonly diagnosed abnormalities associated with LBP. For decades, lumbar discectomy has been one of the most common surgical practices performed by neurosurgeons.<sup>[4,5]</sup> Cauda equina syndrome (CES) is a serious neurologic disorder of lumbar

disc herniation.<sup>[6]</sup> Back pain and radiculopathy are the most common symptoms. There may be urinary retention resulting in incontinence or rectal dysfunction. Saddle anesthesia should immediately raise suspicion for CES.<sup>[7,8]</sup> However, its pathophysiological mechanisms are not completely understood. It may result from direct mechanical compression of Cauda equina (CE) nerve roots.<sup>[8,9]</sup> It is a common health problem leading to work disability.<sup>[10]</sup> However, sexual and sphincter dysfunction with the CES due to a prolapsed lumbar L5-S1 intervertebral disc is of rare occurrence, which has not well been investigated. The aim of the present study is to assess the outcome and possible mechanism of the sexual and sphincter dysfunction associated with lumbar disc herniation.

## SUBJECTS AND METHODS

The study conducted in patients with lumbar disc herniation and sexual dysfunction admitted to our department between September 2012 and March 2014 after informed patient consent had been obtained. Neurological examination of the trunk and lower limbs was undertaken. This included: power of knee and ankle flexion, briskness of Achilles reflex, and perianal sensation. Sexual function was scored as 0: normal, 1: slight dysfunction, 2: moderate dysfunction, 3: severe dysfunction (impotence). Anal + urethral sphincter function (SF) was graded as 0: normal, 1: slight dysfunction, 2: moderate dysfunction, 3: severe dysfunction. Perianal sensation was scored as 0: normal, 1: slight dysesthesia, 2: moderate dysesthesia, 3: anesthesia. Magnetic resonance imaging (MRI) scans were obtained in all patients. MRIs confirm the diagnosis and reveal the exact level of disk herniation. Statistical analysis was performed using the Predictive Analytics SoftWare (PASW) Statistics 18.0 for Windows (Statistical Package for the Social Sciences, SPSS Inc., Chicago, Illinois). The statistical significance was set at  $P < 0.05$ . The Wilcoxon signed ranks test was used to evaluate the difference between patients.

## RESULTS

The examined group consisted of four patients, including two women and two men, aged between 20 and 52 years, admitted without low back pain. The patients admitted with a few days history of numbness in her buttocks, urinary, and fecal incontinence. On neurological examination, knee and ankle flexion and Achilles reflexes were normal. Almost all patients

had a clear perianal sensory deficit, diminished anal tone, and sexual dysfunction, and they did not have any limitation of straight leg-raising. Radiologic investigations such as plain radiography, MRI were obtained. The herniation was at the disc between L5 and S1 vertebrae in all patients. In three patients, a large extruded disc fragment was seen on the left side. In fourth patient, prominent disc herniation was not observed.

## Post-operative course and follow-up

The longest follow-up was 2 years and the shortest was 6 months. There was not statistically significant difference between preoperative and post-operative SF score ( $P = 0.317$ ), anal-urethral SF score ( $P = 0.066$ ), perianal sensation score ( $P = 0.059$ ). Pre-operative period, there was no motor deficit. Following surgery, three patients stated that they were less active and passive and one lost interest in sex. Only in one patient, sexual function slightly improved. In this study, a syndrome in L5-S1 disc herniation with sexual and sphincter dysfunction without pain and muscle weakness was noted. Table shows the sexual, anal, urethral SF score, and perianal sensation scores of patients. The improvement of perianal sensory deficit after surgery was counteracted by a trend toward disturbed sexual function.

## Illustration of cases

### Case 1 (IM)

A 55-year-old male had difficulty in passing urine and was sexually impotent. On examination, there was absence of ankle reflexes and hypoaesthesia in the L5, S1 dermatomes on the left side and neurogenic claudication. He had retention of urine with a distended bladder. Lumbar MRI revealed a prolapsed disc herniation at the level L5-S1 [Figure 1]. An urgent, hemipartial laminectomy of left side L5 was performed and a massive disc prolapse, compressing the CE, was removed. The bladder control returned by the eight week after operation and although he was able to pass urine on his own, it took 4 months to recover normal bladder function. His sensation was gradually improved. However, sexual function and tendon reflexes had not returned to normal even 2 years after the operation.

### Case 2 (AK)

A 54-year-old male was admitted for acute retention of urine. He had no history of backache. Two days before his admission, he had developed left-sided sciatica, followed by urinary retention and impotence. Clinical examination revealed saddle anesthesia, a distended bladder, and loss of anal tone. The straight leg-raising

**Table: The sexual, anal, urethral sphincter function score, and perianal sensation scores of patients**

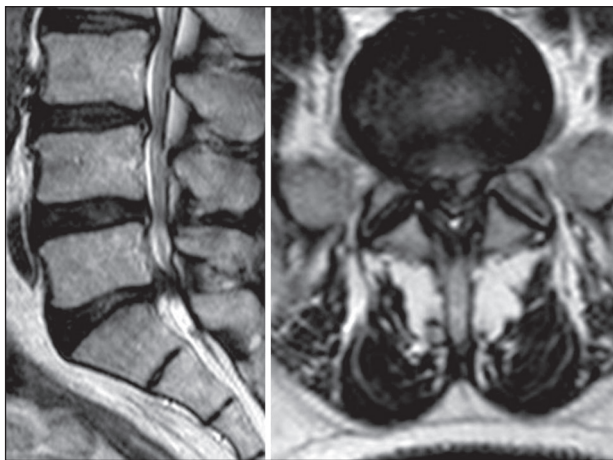
	SF Score			Anal+ urethral sphincter function score			Perianal sensation score		
	Pre op	Post op	P	Pre op	Post op	P	Pre op	Post op	P
IM patient 1	3	3	0.317	2	1	0.066	3	0	0.059
AK patient 2	3	1		3	0		2	0	
HZ patient 3	3	3		2	0		3	1	
EK patient 4	3	3		3	1		3	1	

SF (sexual function) score: 0: normal, 1: slight dysfunction, 2: moderate dysfunction, 3: severe dysfunction (impotence) Anal+ urethral sphincter function score: 0: normal, 1: slight dysfunction, 2: moderate dysfunction, 3: severe dysfunction Perianal sensation score: 0: normal, 1: slight dysesthesia 2: moderate dysesthesia, 3: anesthesia

test was normal on both sides, there was no motor weakness in the lower limbs and the Achilles reflexes were absent on the right side. Lumbar MRI revealed a L5-S1 disc herniation [Figure 2]. A right side hemipartial laminectomy of L5 was performed immediately and a large disc prolapse at the L5-S1 level was removed. On the two months after surgery, he was able to pass urine but it took six months for him to recover normal bladder function. One year after operation he was able to have a sustained erection.

**Case 3 (HZ)**

A 29-year-old woman admitted with transient difficulty in passing urine, sexual dysfunction, and perianal hypoesthesia. Clinically, both the Achilles reflexes were absent and there was perianal hypoesthesia but no motor weakness. A lumbar MRI revealed a prolapse at the level of the left side L5-S1 disc space, and at operation, disc prolapse was removed [Figure 3]. The perianal hypoesthesia diminished and bladder control was returned to normal after three months of operation. However, there was no recovery of her sexual dysfunction.



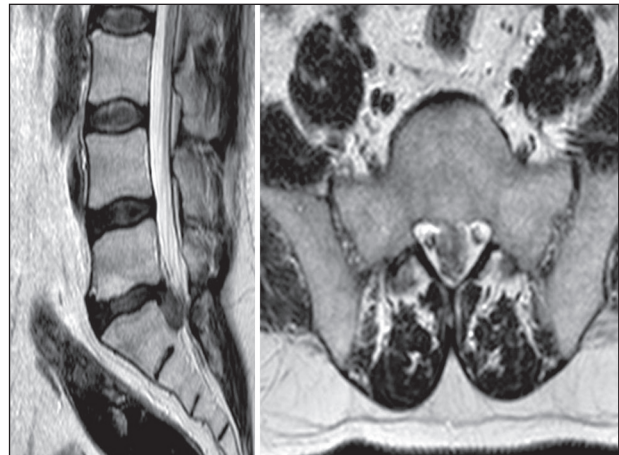**Figure 1: Pre-operative lumbar magnetic resonance imaging (MRI) of 55-year-old male with sexual dysfunction and L5-S1 lumbar disc herniation**

**Case 4 (EK)**

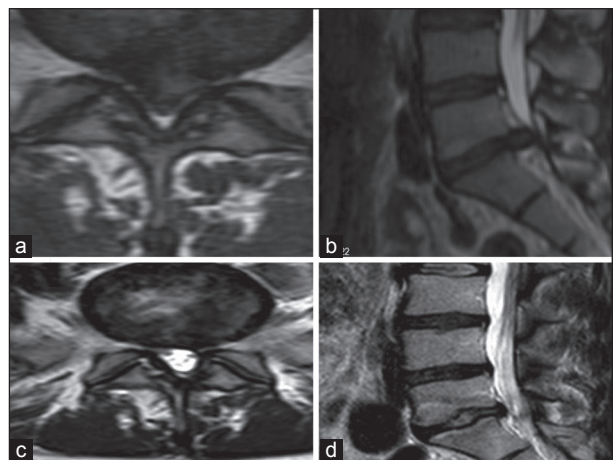
A 31-year old woman, she has had left side L5-S1 disc herniation; however, it was not prolapsed, only bulging was noted on the lumbar MRI [Figure 4]. Urinary retention and sexual dysfunction were main problems. After initial evaluation, emergent, standard left L5-S1 partial hemilaminotomy and microdiscectomy performed. The post-operative period of patient was uneventful. They discharged on the fourth post-operative day. At 6-month follow-up, although bladder was nearly normal, the reduced sensation in the sacral area, and her sexual dysfunction were continuing.

**DISCUSSION**

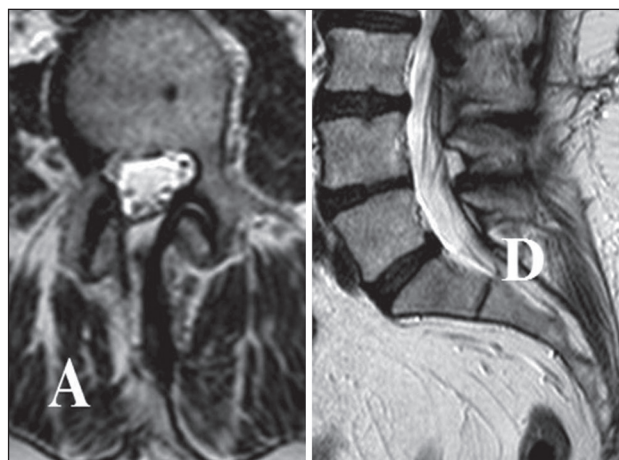
Disc herniation of the same size may be asymptomatic in one patient<sup>[1]</sup>, and can lead to severe nerve root compromise in another patient.<sup>[2]</sup> The symptoms of CES usually include 1: low back pain (LBP), 2: often bilateral but sometimes unilateral sciatica, especially at L5/S1 with an inferior extrusion, 3: genital



**Figure 2: Pre-operative magnetic resonance imaging (MRI) of a 54-year-old male with left-sided sciatica, urinary retention, and impotence**



**Figure 3: Pre-operative (a and b), post-operative (c and d) magnetic resonance imaging (MRI) of a 29-year-old woman with transient difficulty in passing urine, sexual dysfunction, and perianal hypoesthesia**



**Figure 4: Post-operative magnetic resonance imaging (MRI) of a 31-year-old woman with disc bulging, urinary retention, and sexual dysfunction**

sensory disturbance, 4: bladder, bowel, and sexual dysfunction. At present, neurosurgical practice is confronted by an explosion of technology.<sup>[5,12]</sup> In spite of recent advances in surgical technique, sexual dysfunction in patients suffering from lumbar disc herniations still remains a considerable clinical problem. It can be socially disruptive and emotionally distressing. The pathophysiology remains unclear. However, the most frequent disorders caused by L-S segment discopathy are erection disorders in men and orgasm disorders in women and Dzierżanowski *et al.* concluded that the responsible factor for sexual dysfunction are chronic back pain and depression.<sup>[13]</sup> We did not observe both chronic back pain and depression in our patients. This is interesting point of present study. Akbas *et al.* reported that lumbar disc herniation has negative effects on sexual life. They studied patients' sexual problems and sexual behavior patterns before and after surgical treatment of lumbar disc herniation.<sup>[14]</sup>

In last two studies, improvement in sex life after lumbar disc surgery was positively correlated to a reduction in low back pain. Our study is different than those studies because in all of four patients, sexual dysfunctions were related to L5-S1 disc herniation. However, association of sexual dysfunction and lumbar disc herniation with is not new in medical literature. There is only two cases report about sexual dysfunction related to disc herniation at the level of L4-S, published in 1999.<sup>[15]</sup>

Another case about sildenafil treatment in neurogenic female sexual dysfunction caused by L5-S1 intervertebral disk rupture in 2007.<sup>[16]</sup> We present here additional four cases. Interesting point of our cases is that all disc occurred at the level L5-S1. Sexual and sphincter dysfunction in these patients developed without low back pain and motor deficit. Almost all patients had perianal sensory deficit. The questions arise as to what extent L5-S1 disc herniations in time and severity of compression are of prognostic significance. The answer is not clear. We can only advise that the longer compression continues the more likely is long-term permanent sexual and sphincter dysfunction which are the most distressing sequelae of patients. Our cases show that compression of the sacral roots at the L5-S1 level, unlike the lumbar ones, may not cause motor signs in the legs, reflex deficit. Although severe back ache with sciatica should raise the spectre of compression of the CE, none of our three patients with a large prolapsed, and a patient with bulging at the L5-S1 level did not complain any pain. In addition, they did not have any limitation of straight leg-raising. Saddle anesthesia with bladder and sexual symptoms were the consistent features in our patients. For that reason, we think that the syndrome, we described here, may be different than classic cauda equine syndrome. Poor recovery of sexual function in all of patients after surgery was a significant feature. Only two CES treated by surgical decompression, the influence of timing on surgical outcome, patients regained partial control of micturition. There was not statistically significant different between pre-operative and post-operative sexual function, anal-urethral SF, and perianal sensation score [see Table 1]. All this four patients were operated in 18 months (between September 2012-March 2014). There was an early realization that paralysis of the sphincter and sexual dysfunction are important in patients

with lumbar L5-S1 disc disease. We again stress that the leg and back pain may be absent in this syndrome. This point is important for spine and urologic surgeon. They should be aware of sexual dysfunction in patient with L5-S1 disc herniations. Our all four cases presented during the first attack of lumbar disc disease associated with sexual dysfunction so they have not had chronic disc disease. This may be another important point of this syndrome. Neurological examination should include a careful search for sensory abnormality in the perineum.

### Possible pathogenesis of sexual dysfunction in L5-S1 lumbar disc herniation

Sexual dysfunction is sometimes a complication following anterior approach lumbar disc surgery. Retrograde ejaculation has been reported in 6% of cases with anterior exposure of the lumbar spine.<sup>[17]</sup> Sexual dysfunction may be related to damage to the hypogastric nervous plexus. The hypogastric plexus contains efferent pre- and post-ganglionic sympathetic fibers, preganglionic parasympathetic fibers, and visceral afferent pain fibers. The superior and inferior hypogastric plexuses receive input from sympathetic preganglionic fibers whose cell bodies reside in the intermediolateral cell columns of the lower spinal cord. These efferent, preganglionic fibers first leave the spinal cord via the ventral roots of spinal nerves and exit the spinal nerves via the white rami communicantes into the lumbosacral sympathetic chain.<sup>[18]</sup> The superior hypogastric plexus lies anterior to the L5 vertebral body and the sacral promontory on both sides. In addition, contraction of the ischiocavernosus and bulbospongiosus striated muscles, located at the penile crus and innervated by the S2-S4 somatic motor fibers, plays a contributory role in penile erection.<sup>[19]</sup> Our study shows that L5-S1 disc may affect these fibers.

### Importance of the study

The syndrome, described here, is based on a study of four patients with neurological signs of compression at the L5-S1 level. We found pronounced sexual and sphincter dysfunction, perineal sensory deficit. Three cases have had left-side involvement. Why this is important? We think that large, extruded L5-S1 disc herniations may affect the superior hypogastric plexus or pre-sacral nerve which is situated anterior to the last lumbar vertebra, the middle sacral artery, the lumbosacral intervertebral disc.

### Limitation of the study

Solid information about long-term recovery of micturition, defecation, and sexual function in CES is not abundant. The reason is probably the shame that revolves around discussing problems of micturition, defecation and sexual function.<sup>[20]</sup> The limitation of the present study is its retrospective nature. As the first pilot study, we hope it will promote prospective studies of sexual dysfunction of L5-S1 disc herniations.

### CONCLUSION

The improvement of perianal sensory deficit after surgery was counteracted by a trend towards disturbed sexual function. Since sexual dysfunction in L5-S1 disc herniation seems to be

severely underreported, we recommend to neurosurgeon to be aware such a catastrophic syndrome. To avoid any misdiagnosis and delay, a rectal examination with sensory examination of the sacral area recommended in the patients having a history of acute onset sexual, sphincter dysfunction, and perianal sensory deficit. These patients may not have radicular symptoms and signs such motor weakness and reflex deficits. We advocate that emergency surgical decompression plays an important role in improving the sexual dysfunction in this syndrome. Detailed physical examination with magnetic resonance (MR) scanning should be done in the case of sexual sphincter dysfunction with perianal sensory deficit. A rectal examination with sensory examination of the sacral area may be required in the patients having L5-S1 disc herniations. Further researches are needed to explore the extent of this problem.

## ABBREVIATION

CE: Cauda equina

CES: Cauda equina syndrome

LBP: Low back pain

MRI: Magnetic resonance imaging

## REFERENCES

- Shemshaki H, Nourian SM, Fereidan-Esfahani M, Mokhtari M, Etemadifar MR. What is the source of low back pain? *J Craniovertebr Junction Spine* 2013;4:21-4.
- Bajpai J, Saini S, Singh R. Clinical correlation of magnetic resonance imaging with symptom complex in prolapsed intervertebral disc disease: A cross-sectional double blind analysis. *J Craniovertebr Junction Spine* 2013;4:16-20.
- Shete KM, Suryawanshi P, Gandhi N. Management of low back pain in computer users: A multidisciplinary approach. *J Craniovertebr Junction Spine* 2012;3:7-10.
- Kanat A, Yazar U, Kazdal H, Sonmez OF. Introducing a new risk factor for lumbar disc herniation in females: Vertical angle of the sacral curvature. *J Korean Neurosurg Soc* 2012;52:447-51.
- Kanat A, Yazar U. Spinal surgery and neurosurgeon: Quo vadis? *J Neurosurg Sci* 2013;57:75-9.
- Turkoglu E, Karavelioglu E, Oral N, Sanli AM, Sekerci Z. Cauda equine syndrome due to posterior sequestered lumbar disc herniation: A rare case report and MRI finding. *J Turk Spinal Surg* 2013;24:165-8.
- Gitelman A, Hishmeh S, Morelli BN, Joseph SA Jr, Casden A, Kuflik P, et al. Cauda equina syndrome: A comprehensive review. *Am J Orthop (Belle Mead NJ)* 2008;37:556-62.
- Ma B, Wu H, Jia LS, Yuan W, Shi GD, Shi JG. Cauda equina syndrome: A review of clinical progress. *Chin Med J (Engl)* 2009;122:1214-22.
- Yildirim AE, Ozdol C, Divanlioglu D, Cetinalp NE, Belen AD. Cauda equine syndrome due to spinal schwannoma with intradural hemorrhage. *J Turk Spinal Surg* 2013;24:293-329.
- Bina MS, Ghahvechi AM, Afshin H, Behnaz S, Kamyar G. Effect of body mass index on inpatient rehabilitation outcomes after single-level discectomy. *Neurosurg Q* 2013.
- Bakhsh A. Role of conventional lumbar myelography in the management of sciatica: An experience from Pakistan. *Asian J Neurosurg* 2012;7:25-8.
- Kanat A, Epstein CR. Challenges to neurosurgical professionalism. *Clin Neurol Neurosurg* 2010;112:839-43.
- Dzierzanowski M, Dzierzanowski M, Wrzecion K, Słomko W, Radzińska A, Kaźmierczak U, et al. Discopathy of the lumbar-sacral segment and its influence on sexual dysfunction. *Adv Clin Exp Med* 2013;22:93-100.
- Akbaş NB, Dalbayrak S, Külcü DG, Yılmaz M, Yılmaz T, Naderi S. Assessment of sexual dysfunction before and after surgery for lumbar disc herniation. *J Neurosurg Spine* 2010;13:581-6.
- Nesathurai S, Jessiman TL. L4-5 disk lesion resulting in back pain with bowel, bladder and sexual dysfunction without paraparesis. *Spinal Cord* 1999;37:228-30.
- Ferrara D, Zaslau S. Success of sildenafil treatment in neurogenic female sexual dysfunction caused by L5-S1 intervertebral disk rupture: A case report. *Int J Urol* 2007;14:566-7.
- Jarrett CD, Heller JG, Tsai L. Anterior exposure of the lumbar spine with and without an "access surgeon": Morbidity analysis of 265 consecutive cases. *J Spinal Disord Tech* 2009;22:559-64.
- Schultz DM. Inferior hypogastric plexus blockade. *Pain Physician* 2007;10:757-63.
- Rampin O, Bernabe J, Giuliano F. Spinal control of penile erection. *World J Urol* 1997;15:2-13.
- Korse NS, Jacobs WC, Elzevier HW, Vleggeert-Lankamp CL. Complaints of micturition, defecation and sexual function in cauda equina syndrome due to lumbar disc herniation: A systematic review. *Eur Spine J* 2013;22:1019-29.

**How to cite this article:** Akca N, Ozdemir B, Kanat A, Batcik OE, Yazar U, Zorba OU. Describing a new syndrome in L5-S1 disc herniation: Sexual and sphincter dysfunction without pain and muscle weakness. *J Craniovertebr Jun Spine* 2014;5:146-50.

**Source of Support:** Nil, **Conflict of Interest:** None declared.

## Staying in touch with the journal

### 1) Table of Contents (TOC) email alert

Receive an email alert containing the TOC when a new complete issue of the journal is made available online. To register for TOC alerts go to [www.jcvjs.com/signup.asp](http://www.jcvjs.com/signup.asp).

### 2) RSS feeds

Really Simple Syndication (RSS) helps you to get alerts on new publication right on your desktop without going to the journal's website. You need a software (e.g. RSSReader, Feed Demon, FeedReader, My Yahoo!, NewsGator and NewzCrawler) to get advantage of this tool. RSS feeds can also be read through FireFox or Microsoft Outlook 2007. Once any of these small (and mostly free) software is installed, add [www.jcvjs.com/rssfeed.asp](http://www.jcvjs.com/rssfeed.asp) as one of the feeds.