



## Case Report

# Fondaparinux for systemic anticoagulation during continuous hemofiltration in a patient with heparin-induced thrombocytopenia and limb ischemia – a case report



Eduardo Atsushi Osawa<sup>a</sup>, Antonio Adolfo Guerra Soares Brandão <sup>b</sup>,  
André Dias Américo <sup>b</sup>, Alexandre Toledo Maciel <sup>a,\*</sup>

<sup>a</sup> Imed Research group, Adult Intensive Care Unit, São Camilo Hospital, São Paulo, SP, Brazil

<sup>b</sup> Hematology Department, São Camilo Hospital, São Paulo, SP, Brazil

## ARTICLE INFO

## Article history:

Received 25 November 2019

Accepted 21 May 2020

Available online 12 July 2020

## Introduction

Heparin-induced thrombocytopenia (HIT) is a potentially life-threatening prothrombotic complication that affects 0,5–3% of patients exposed to unfractionated heparin (UFH).<sup>1,2</sup> HIT occurs due to antibodies produced against platelet factor 4 (PF4) and heparin complex. Those antibodies may cause intravascular platelet consumption and increased thrombin generation, resulting in thrombocytopenia and thromboembolic phenomena, which are the main clinical features of HIT.<sup>1</sup>

Evaluation of suspected HIT involves the application of probability score systems: 4T score<sup>3</sup> or HEP score.<sup>4</sup> Patients with intermediate or high HIT probability, should undergo additional laboratory tests. The anti-PF4-heparin enzyme immunoassays are very useful due to their very high negative predictive value. Additionally, functional assays with washed platelets may help in some cases.

Management of patients with thrombosis when acute HIT is highly suspected or confirmed requires immediate heparin suspension and the introduction of an alternative anticoagulant, preferably direct thrombin inhibitors like danaparoid and bivalirudin.<sup>5,6</sup> Treatment of HIT when direct thrombin inhibitors use is not possible, especially in patients with severe renal dysfunction, is challenging and there are few studies addressing how to manage this clinical scenario.<sup>7–9</sup> We herein describe a case of a patient with HIT and acute kidney injury requiring both renal replacement therapy and therapeutic anticoagulation in the absence of direct thrombin inhibitors.

## Case presentation

A 38-year-old Caucasian woman presented to our Emergency Department (ED) with a complaint of malaise, fever, coughing and diarrhea in the preceding 4 days. Her past medical history was remarkable for the diagnosis of scleroderma, for

\* Corresponding author at: Imed Research Group, Rua Fabia 610 24A, São Paulo, SP, 05051-030, Brazil.

E-mail address: alexandre.toledo@imedgroup.com.br (A.T. Maciel).

<https://doi.org/10.1016/j.htct.2020.05.008>

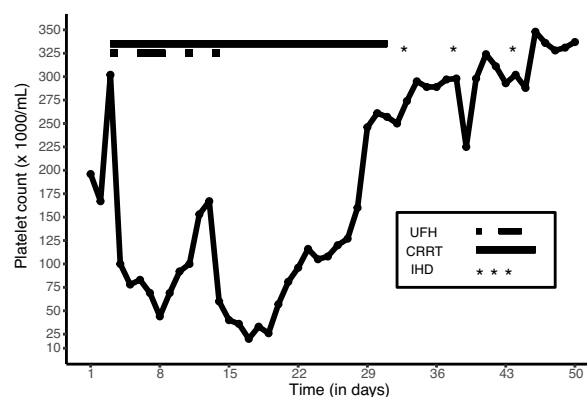
2531-1379/© 2020 Associação Brasileira de Hematologia, Hemoterapia e Terapia Celular. Published by Elsevier Editora Ltda. This is an open access article under the CC BY-NC-ND license (<http://creativecommons.org/licenses/by-nc-nd/4.0/>).

which she was treated with chloroquine. Upon arrival to the ED, she was hypotensive (blood pressure 80/50 mmHg), tachycardic (heart rate 108 beats per minute) and had a prolonged capillary refill time, which prompted clinicians to administer 3 L of crystalloid fluid, and she was then transferred to the Intensive Care Unit (ICU).

After 20 h of ICU admission, the patient developed arterial hypotension requiring continuous infusion of norepinephrine. Over the following hours, she had a marked deterioration of her hemodynamic state as the lactate level peaked 8.5 mmol/L and norepinephrine infusion reached 0.4 mcg/kg/min. A bedside echocardiogram revealed a moderate left ventricular impairment [left ventricular ejection fraction (LVEF) of 40%] along with a moderate pericardial effusion but no signs of cardiac tamponade. An infusion of dobutamine was subsequently initiated. Due to the worsening nature of the shock, she was intubated and sedated, and received large spectrum antibiotic (piperacillin-tazobactam). Despite the hemodynamic resuscitative measures, the patient had a cardiac arrest for which cardiopulmonary resuscitation was delivered for 18 min. A repeat echocardiogram showed cardiac tamponade with a significant left ventricular dysfunction (LVEF of 30%) and, as a result, a pericardiocentesis was performed. Since circulatory shock had not been resolved after the procedure, a peripheral venoarterial non-heparin-coated extracorporeal membrane oxygenation (ECMO) was inserted through the femoral vessels of the right lower limb along with the commencement of heparin infusion to achieve an activated partial thromboplastin time ratio between 1.5 to 2.5. In addition, continuous renal replacement therapy (CRRT) was started due to anuria and metabolic acidosis. On the following day, the persistence of clinical signs of low tissue perfusion prompted the medical team to place an intra-aortic balloon pump (IABP) through the left femoral artery.

Over the course of 48 h following the initiation of extracorporeal support, the patient presented a substantial improvement of her hemodynamic condition characterized by a drop in the lactate levels, lessened requirement of vasopressor agents (norepinephrine and vasopressin) and improvement of peripheral tissue perfusion. The diagnostic hypothesis of viral myocarditis was raised but never actually confirmed. Moreover, a gradual reversion of the organ failures was observed and daily-performed echocardiograms showed a progressive recovery of the left ventricular function. Nevertheless, the patient developed pulseless acute left lower limb ischemia which urged clinicians to remove IABP. She was weaned off ECMO successfully on the 5th day and extubated on the following day. Vasopressor administration was discontinued after 10 days of therapy. Despite IABP removal and ongoing anticoagulation, the patient required left femoral artery thrombectomy and angioplasty. These measures did not prevent irreversible limb ischemia and an additional procedure was delayed until necrosis delimitation. Furthermore, an ultrasound scan demonstrated a deep venous thrombosis of the left fibular veins despite ongoing heparin infusion. At that moment, her platelet count was 179,000/mm<sup>3</sup> (Figure 1).

On day 12 after ICU admission, she developed hypoxemic respiratory failure and septic shock secondary to ventilator-associated pneumonia requiring reintubation, continuous sedation and a new course of broad-spectrum antibiotics

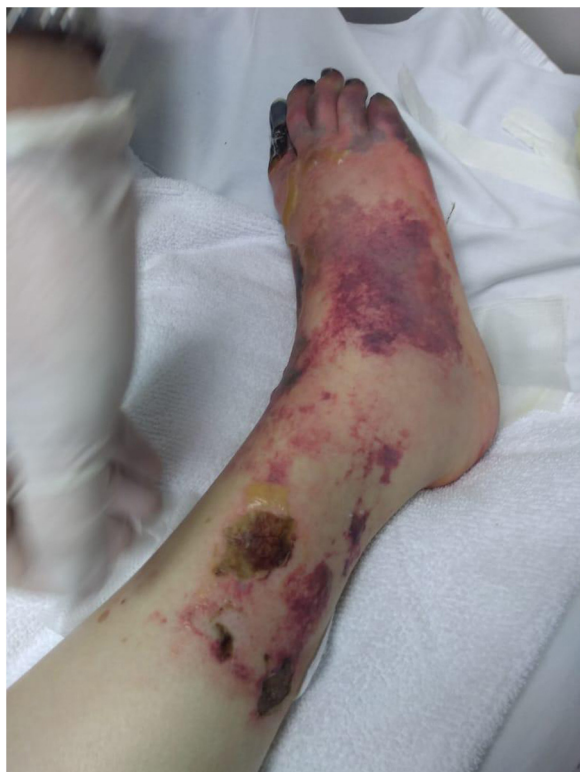

**Figure 1 – Daily platelet count in the course of ICU stay. UFH: unfractionated heparin infusion CRRT: continuous renal replacement therapy. IHD: intermittent hemodialysis.**

**Table 1 – HIT score applied to the patient.**

	Result	Points
Thrombocytopenia	Platelet count fall > 50 % and nadir 20,000/mm <sup>3</sup>	2
Timing of platelet count fall	Onset after day 10 (day 11)	1
Thrombosis or other sequelae	New thrombosis and skin necrosis	2
Other causes for thrombocytopenia	Possible	1
HIT: heparin-induced thrombocytopenia.		

(meropenem and vancomycin). In addition, she received again high-dose of vasopressors and CRRT was maintained. Her platelet count has progressively fallen (Figure 1) from the eleventh day of heparin infusion and reached a nadir of 20,000/mm<sup>3</sup> after four days. Even though the patient had other causes for thrombocytopenia, such as septic shock and administration of drugs that may cause thrombocytopenia like vancomycin, the diagnosis of heparin-induced thrombocytopenia was suspected. Disseminated intravascular coagulation was ruled out as clotting times and fibrinogen level were within normal range. The 4Ts score was then applied and summed 6 points (Table 1) suggesting a high probability of HIT. Additional investigation showed that anti-platelet factor 4/heparin enzyme-linked immunosorbent assay (Quest Diagnostics) was positive (optical density 1,406, reference range: ≤0,300 OD Units). A functional assay was not available to confirm HIT diagnosis. Since HIT probability was high and the immunological assay was positive, heparin infusion was ceased. Although the patient still needed CRRT, a decision was made to provide anticoagulant therapy with fondaparinux 2.5 mg once a day to treat acute thrombosis in a setting where direct thrombin inhibitors were not available. Fondaparinux administration was initiated on day 20 after ICU admission. The efficacy and safety of anticoagulation was monitored with measurements of anti-factor Xa chromogenic assays, with a goal of 0.5–1.0 IU/mL (therapeutic level). Platelet count started to improve 3 days after heparin withdrawal, reaching 160,000/mm<sup>3</sup> on the tenth day following suspension (Figure 1).



**Figure 2 – Ischemic right lower limb with necrotic areas in the toe.**

During the recovery period of her organ failures, the patient required surgical procedures including tracheostomy, debridement of necrotic areas in the right foot (Figure 2) and transtibial amputation of the left lower limb. Before those procedures, fondaparinux was ceased for 24 h and 72 h, respectively, and she experienced clinically relevant non major bleeding (CRNMB) with the need of blood products (red blood cells (RBC) and platelet transfusion) and reoperation for hemostasis at the tracheostomy site. Her hemodynamic improvement enabled CRRT to be transitioned to intermittent hemodialysis (IHD) on day 32, and this was accompanied by a slow recovery of the renal function until her last hemodialysis session on day 46 (Figure 1).

On day 60 of ICU admission, the patient developed left sided pleural effusion. A diagnostic thoracentesis was performed 48 h after fondaparinux withdrawal; however, the procedure was complicated by hemothorax which required RBC transfusion and chest tube placement. Analysis of the pleural fluid and CT scan demonstrated pleural empyema and pulmonary abscess caused by *Enterobacter aerogenes* and, subsequently, she underwent lung decortication after stopping anticoagulant therapy for 72 h. Following that intervention, she received an extended regimen of antimicrobial therapy (meropenem) and her clinical course in the ICU was uneventful. The anticoagulant therapy was transitioned to oral apixaban 2.5 mg bid which was well tolerated as no relevant bleeding events occurred after its introduction. Following a period of rehabilitation, she was discharged home after 3 months of hospital stay.

## Discussion

HIT is a diagnosis that must be considered in critically ill patients who develop thrombocytopenia even if there are other etiologies involved.<sup>10</sup> Patients exposed to extracorporeal life support such as ECMO comprise a higher risk group and the reported HIT prevalence in those cases is 8,3%.<sup>11</sup> Therefore, early clinical suspicion is crucial for better outcomes.

The probability score systems for HIT, 4T score and HEP score, are useful tools to guide the investigation<sup>3,4</sup> and there is some evidence that the HEP score may perform better in ICU patients, classifying 48.2% of patients correctly versus 40.0% with the 4T score in a prospective comparison.<sup>12</sup> In patients with intermediate/high clinical probability an immunoassay must be performed and, if positive, a functional assay evaluation is recommended, notably when the optical density is below 2.0 OD units. However, when functional assays are not available, the diagnosis can be made with strongly positive immunoassays results.<sup>6</sup> An ELISA optical density (OD) value higher than 1.0 is associated with higher thrombosis risk<sup>13</sup> and in combination with 4Ts delivers sensitivity of 69% and specificity of 85%.<sup>14</sup>

In the case presentation, before the diagnosis of HIT was made, our patient presented a first phase of platelet count decline which started 48 h after the initiation of heparin infusion. HIT was not suspected at that stage due to the short timeframe between commencement of heparin and development of thrombocytopenia, along with the coexistence of factors that could justify this condition. As the patient developed multiple organ dysfunction and sepsis was a diagnostic hypothesis, we attributed thrombocytopenia to hematological dysfunction caused by a profound systemic inflammatory state. Moreover, aside from heparin infusion, the patient received high dose of vasopressor agents, antibiotics and two methods of mechanical circulatory support. We hypothesize that the recovery of platelet count by day 8 was followed by the resolution of shock of shock/systemic inflammation; so much so that it occurred despite the ongoing infusion of heparin.

Patients with HIT that require anticoagulant treatment due to acute thrombosis should receive parenteral direct thrombin inhibitors according to guidelines.<sup>5,6</sup> Unfortunately, those anticoagulants are not easily available everywhere, so the therapeutic options rely on fondaparinux<sup>8</sup> and direct oral anticoagulants<sup>14</sup> which are contraindicated in severe renal impairment.

In our patient, due to HIT with acute thrombosis, heparin was interrupted and an alternative anticoagulant regimen was deemed necessary. At this stage, we faced a challenging scenario as the patient had acute kidney injury requiring renal replacement therapy and none of the recommended anticoagulants are currently available in Brazil. The decision to use fondaparinux was based on the grounds of the availability of drug activity monitoring<sup>15</sup> and the safety of this therapy previously reported in a similar situation.<sup>9</sup> Since fondaparinux-calibrated assays are routinely unavailable in Brazil, a decision was made to monitor activity with low molecular heparins calibrated anti-Xa. This approach should be cautiously interpreted because low molecular heparin assays allow only for an approximation of the fondaparinux



level.<sup>16,17</sup> We preferred to administer a daily dose of 2.5 mg due to the risk of anticoagulant accumulation in view of kidney function compromise. This approach was similar to the therapy reported by other investigators.<sup>18,19</sup>

Although anti-Xa activity was monitored and the results were in the therapeutic range (0.7 to 0.8 in three measurements at 2, 12 and 26 days after fondaparinux initiation), the patient developed CRNMB episodes related to invasive procedures. Those episodes occurred despite the recommended period of fondaparinux suspension was respected, and it might be related to the poor correlation between anti-Xa activity and bleeding in patients with renal dysfunction.<sup>20</sup> Nevertheless, from the perspective of the primary goal of HIT treatment, we believe that fondaparinux was effective in the treatment of deep vein thrombosis and in the prevention of thrombosis at other sites.

In conclusion, fondaparinux may be a reasonable option for HIT treatment in dialysis patients as long as used with caution, when other options are not available. Bleeding episodes may occur even with anti-Xa monitoring, and discretion is advised when interpreting the results, particularly in high-risk of bleeding scenarios. The documentation of lower anti-Xa activity levels before invasive procedures may be a safe strategy to mitigate this risk. However, there are other limitations for the anti-Xa monitoring: the results are not available promptly, and the fondaparinux specific assay is not routinely performed in most hospitals. Efforts should be made to provide easier access to fondaparinux calibrated anti-Xa assay which may be helpful in challenging clinical situations as the one we described. We believe that longer periods of fondaparinux withdrawal might be recommended prior to surgical procedures in dialytic patients, perhaps a timeframe greater than 72 h.

After renal function improvement, switching to apixaban was feasible in this case. Since this clinical presentation is rare, it is unlikely that large prospective studies will be conducted, so case series and reports may be the only evidence available to guide decision making.

## Conflicts of interest

The authors declare no conflicts of interest.

## REFERENCES

- Greinacher A. Clinical practice. Heparin-induced thrombocytopenia. *N Engl J Med*. 2015;373:252–61.
- Martel N, Lee J, Wells PS. Risk for heparin-induced thrombocytopenia with unfractionated and low-molecular-weight heparin thromboprophylaxis: a meta-analysis. *Blood*. 2005;106(8):2710–5.
- Lo GK, Juhl D, Warkentin TE, Sigouin CS, Eichler P, Greinacher A. Evaluation of pretest clinical score (4 T's) for the diagnosis of heparin-induced thrombocytopenia in two clinical settings. *J Thromb Haemost*. 2006;4(4):759–65.
- Cuker A, Arepally G, Crowther MA, Rice L, Datko F, Hook K, et al. The HIT Expert Probability (HEP) Score: a novel pre-test probability model for heparin-induced thrombocytopenia based on broad expert opinion. *J Thromb Haemost*. 2010;8:2642–50.
- Watson H, Davidson S, Keeling D. Guidelines on the diagnosis and management of heparin-induced thrombocytopenia: second edition. *Br J Haematol*. 2012;159:528–40.
- Cuker A, Arepally GM, Chong BH, Cines DB, Greinacher A, Gruel Y, et al. American Society of Hematology 2018 guidelines for management of venous thromboembolism: heparin-induced thrombocytopenia. *Blood Adv*. 2018;2(22):3360–92.
- Lobo B, Finch C, Howard A, Minhas S. Fondaparinux for the treatment of patients with acute heparin-induced thrombocytopenia. *Thromb Haemost*. 2008;99(1):208–14.
- Kang M, Alahmadi M, Sawh S, Kovacs MJ, Lazo-Langner A. Fondaparinux for the treatment of suspected heparin-induced thrombocytopenia: a propensity score-matched study. *Blood*. 2015;125(6):924–9.
- Haase M, Bellomo R, Rocktaeschel J, Ziemer S, Kiesewetter H, Morgera S, et al. Use of fondaparinux (ARIXTRA®) in a dialysis patient with symptomatic heparin-induced thrombocytopenia type II. *Nephrol Dial Transplant*. 2005;20(2):444–6.
- Greinacher A, Selleng S. How I evaluate and treat thrombocytopenia in the intensive care unit patient. *Blood*. 2016;128(26):3032–42.
- Sokolovic M, Pratt AK, Vukicevic V, Sarumi M, Johnson LS, Shah NS. Platelet Count Trends and Prevalence of Heparin-Induced Thrombocytopenia in a Cohort of Extracorporeal Membrane Oxygenator Patients. *Crit Care Med*. 2016;44(11):e1031–7.
- Pishko AM, Fardin S, Lefler DS, Paydary K, Vega R, Arepally GM, et al. Prospective comparison of the HEP score and 4Ts score for the diagnosis of heparin-induced thrombocytopenia. *Blood Adv*. 2018;2(22):3155–62.
- Zwicker JI, Uhl L, Huang WY, Shaz BH, Bauer KA. Thrombosis and ELISA optical density values in hospitalized patients with heparin-induced thrombocytopenia. *J Thromb Haemost*. 2004;2(12):2133–7.
- Warkentin TE, Pai M, Linkins LA. Direct oral anticoagulants for treatment of HIT: update of Hamilton experience and literature review. *Blood*. 2017;130(9):1104–13.
- Paolucci F, Frasa H, Van Aarle F, Capdevila A, Clavies MC, van Dinther T, et al. Two sensitive and rapid chromogenic assays of fondaparinux sodium (Arixtra) in human plasma and other biological matrices. *Clin Lab*. 2003;49(9–10):451–60.
- Smogorzewska A, Brandt JT, Chandler WL, Cunningham MT, Hayes TE, Olson JD, et al. Effect of fondaparinux on coagulation assays: results of College of American Pathologists proficiency testing. *Arch Pathol Lab Med*. 2006;130(11):1605–11.
- Boshkov Lk, Kirby A, Heuschkel M. Pharmacokinetics of Fondaparinux by Anti-Xa Levels and Clinical Response to Anticoagulation in a 4-Month Old Congenital Cardiac Patient with Heparin-Induced Thrombocytopenia (HIT) and Established Venous Thrombosis Transitioned from Argatroban to Fondaparinux. *Blood*. 2004;104(11):4072.
- Wester JP, Leyte A, Oudemans-van Straaten HM, Bosman RJ, van der Spoel JI, Haak EA, et al. Low-dose fondaparinux in suspected heparin-induced thrombocytopenia in the critically ill. *Neth J Med*. 2007;65(3):101–8.
- Cegarra-Sanmartín V, González-Rodríguez R, Paniagua-Iglesias P, Santamaría-Ortiz A, Cueva LF, Galán-Serrano J, et al. Fondaparinux as a safe alternative for managing heparin-induced thrombocytopenia in postoperative cardiac surgery patients. *J Cardiothorac Vasc Anesth*. 2014;28(4):1008–12.
- Brophy DF, Martin EJ, Best AM, Gehr TW, Carr ME. Antifactor Xa activity correlates to thrombin generation time, platelet contractile force and clot elastic modulus following ex vivo enoxaparin exposure in patients with and without renal dysfunction. *J Thromb Haemost*. 2004;2(8):1299–304.