

Iatrogenic type A aortic dissection during idiopathic ventricular tachycardia ablation



Srinath C. Yeshwant, MD,* Mitchell H. Tsai, MD, MMM,^{†‡} Bradley R. Jones, MD,[†]
Mark P. Hamlin, MD, MS, FCCM,^{†§} Ariel D. Bensimhon, MD,[†]
Daniel L. Lustgarten, MD, PhD, FHRS*

From the *Department of Internal Medicine, Division of Cardiology, University of Vermont College of Medicine, Burlington, Vermont, [†]Department of Anesthesiology, University of Vermont College of Medicine, Burlington, Vermont, [‡]Department of Orthopaedics and Rehabilitation (by courtesy), University of Vermont College of Medicine, Burlington, Vermont, and [§]Department of Surgery, University of Vermont College of Medicine, Burlington, Vermont.

Introduction

Iatrogenic ascending aorta dissection has been reported as a rare and potentially life-threatening complication of coronary angiography procedures¹; however, there are no reports of this complication occurring during a cardiac ablation. Idiopathic ventricular tachycardia (VT) is an arrhythmia that occurs in structurally normal hearts and can often be definitively treated by catheter ablation. These cases occasionally require a retrograde aortic approach. We present an instance of a type A aortic dissection resulting from ablation catheter manipulation during retrograde mapping of idiopathic VT.

Case report

An 80-year-old previously healthy woman presented with a history of recurrent episodes of presyncope and syncope. As part of her evaluation for these symptoms, she was given an event monitor, which demonstrated a period of sustained VT that correlated with an episode of dizziness and terminated spontaneously. The patient was advised to come to the emergency room. On admission to the hospital, she was asymptomatic and her electrocardiogram showed normal sinus rhythm with frequent pre-ventricular contractions. Echocardiography showed normal biventricular function and structure with no significant valvular pathology. A pharmacologic nuclear stress test demonstrated no perfusion defects.

KEYWORDS Ventricular tachycardia; Idiopathic ventricular tachycardia; Catheter ablation; Aortic dissection; Complication; Retrograde approach (Heart Rhythm Case Reports 2017;3:396–399)

Address reprint requests and correspondence: Dr Srinath C. Yeshwant, The University of Vermont Medical Center, Cardiology, 111 Colchester Ave, Med. Ctr, McClure 1, Burlington, VT 05401. E-mail address: srinath.yeshwant@uvmhealth.org.

Owing to the severity of the patient's symptoms and her strong preference against pharmacologic therapies, we opted to perform an ablation to treat her arrhythmia. The patient was brought to the electrophysiology lab for an electrophysiology study and VT ablation performed under conscious sedation. Right and left femoral vein access was established with 8.5 F and 7 F sheaths and standard electrode-tipped catheters were advanced into the right atrium, right ventricle, and coronary sinus. Burst pacing from the right ventricle initiated a hemodynamically stable sustained VT that was characterized by a right bundle branch morphology and positive concordance throughout the precordial leads (Figure 1). We felt that this pattern was suggestive of a left-sided origin, likely along the mitral annulus. Right femoral artery access was subsequently established with an 8 F sheath and an irrigated deflectable quadripolar 3.5-mm-tip ablation catheter (Thermocool Navistar SF; Biosense Webster, Inc, Diamond Bar, CA) was advanced retrograde through the aorta using fluoroscopic guidance. Anticoagulation with heparin was initiated to maintain an activated clotting time between 300 and 350 seconds.

A mild amount of resistance was encountered while navigating the ablation catheter around the aortic arch to the aortic root, but the catheter tip moved freely and reached the aortic valve on fluoroscopic imaging. The catheter was curled into a pigtail shape in the aortic arch and manipulated to prolapse through the aortic valve with some difficulty, but access to the left ventricle (LV) was achieved after several attempts. The left ventricular endocardial surface was mapped using the CARTO 3 system (Biosense Webster, Inc, Diamond Bar, CA); however, mapping was stopped when the contact force sensor on the catheter tip malfunctioned, resulting in erroneous measurements. The faulty ablation catheter was withdrawn and exchanged for a new catheter. During advancement of the new ablation catheter around the aortic arch, the patient complained of moderate, unremitting chest

KEY TEACHING POINTS

- The risk of injury to the aorta may be reduced by manipulating the ablation catheter into a protected shape prior to engaging the aorta, aortic root, and aortic valve.
- Prompt recognition of the signs of iatrogenic aortic dissection during cardiac ablation and prompt use of available diagnostic testing is essential to a favorable outcome.
- A collaborative approach from cardiologists, radiologists, anesthesiologists, and surgeons is necessary for a rapid response to a life-threatening complication from cardiac ablation.

pain with radiation to the back. As the patient had not received any therapy at that point in the procedure and was adequately anticoagulated, we felt there was little concern for ablation-related pain or pulmonary embolism. A 12-lead electrocardiogram demonstrated no ST-segment changes to indicate injury to a coronary artery. Fluoroscopy demonstrated normal excursion of the left heart border and urgent transthoracic echocardiography demonstrated no pericardial effusion suggestive of a cardiac perforation or injury to the aortic valve. Our remaining concern was for injury to the aorta. The procedure was aborted and anticoagulation was reversed with protamine sulfate. All femoral sheaths were removed and hemostasis was achieved with manual pressure and a closure device for the arterial access site. Urgent computed tomography angiogram of the chest was performed to evaluate the patient's aorta and coronary arteries and these images demonstrated a type A aortic dissection with a thrombus in the false lumen (Figure 2). The cardiothoracic surgery service recommended emergent surgical repair.

The patient received metoprolol for episodes of VT during transport to the operating room. Pre-cardiopulmonary bypass transesophageal echocardiography demonstrated normal left and right ventricular function, mild mitral regurgitation, mild-to-moderate aortic regurgitation with a jet directed toward the anterior leaflet of the mitral valve, and an aortic dissection extending from the sinotubular junction to the diaphragm (the extent of view on transesophageal echocardiography). The aortic valve showed normal trileaflet anatomy without obvious disruption from the dissection.

During surgery, arterial and venous access was obtained through the left femoral artery and right atrial appendage, respectively. The aorta was transected at the level of the sinotubular junction and at the level of the innominate artery and reconstructed with a Terumo Hemashield graft, followed by resuspension of the aortic valve. Notably, there was no identifiable site of intimal disruption observed during aortic reconstruction.

The patient was separated from cardiopulmonary bypass without difficulty. Full reversal of administered heparin was achieved with protamine and confirmed with a return of activated clotting time to baseline. Postbypass transesophageal examination revealed normal left and right ventricular function and mild residual aortic regurgitation. Her postoperative course was uneventful. The patient was started on verapamil for medical management of her VT and was subsequently seen in follow-up 1 month after discharge, doing well from a surgical perspective and with no recurrent presyncope or syncope.

Discussion

We present a case of idiopathic VT ablation complicated by a type A aortic dissection with successful emergent surgical repair of the ascending aorta. In this case, the dissection was likely the result of trauma to the intima of the aortic root incurred during repeated attempts to cross the aortic valve with our first ablation catheter. In our experience, crossing the valve is typically accomplished by advancing the ablation catheter through the aorta to the aortic valve, curling the catheter into the shape of a pigtail and prolapsing the body of the catheter across the valve. To the best of our knowledge, there is no optimal method for performing this maneuver to minimize trauma. Injury to vital structures can occur in several ways:

- (1) Advancing an ablation catheter through the descending aorta can result in trauma to the aortic intima or dislodgement of aortic calcifications at any point during retrograde transit.
- (2) There is often insufficient space in the aorta to curl the ablation catheter into a pigtail shape until the tip of the catheter has entered the aortic root. Curling the catheter tip within the root has the potential to cause traumatic damage to the coronary vessels and to the aortic valve. Such events are rare, but they can be life-threatening and have been reported in the literature.^{2,3}
- (3) Manipulating the ablation catheter to cross the aortic valve can cause traumatic disruption of the intima in the aortic root, resulting in antegrade aortic dissection. This was the probable mechanism of injury in the case presented above.
- (4) Crossing the aortic valve with an ablation catheter has been reported to rarely cause injury to the aortic valve apparatus, either directly by the manipulation of the catheter tip through the valve or by persistent force on the cusps exerted by the catheter shaft after the tip has been advanced into the LV.⁴

Preventing complications during retrograde access starts with avoiding this approach in patients with known or suspected peripheral vascular disease. The risk of complication to the aorta and related structures may be further mitigated by curling the ablation catheter into a "J" or pigtail shape as close to the femoral arterial access site as possible, thereby allowing the catheter to traverse a longer distance through the

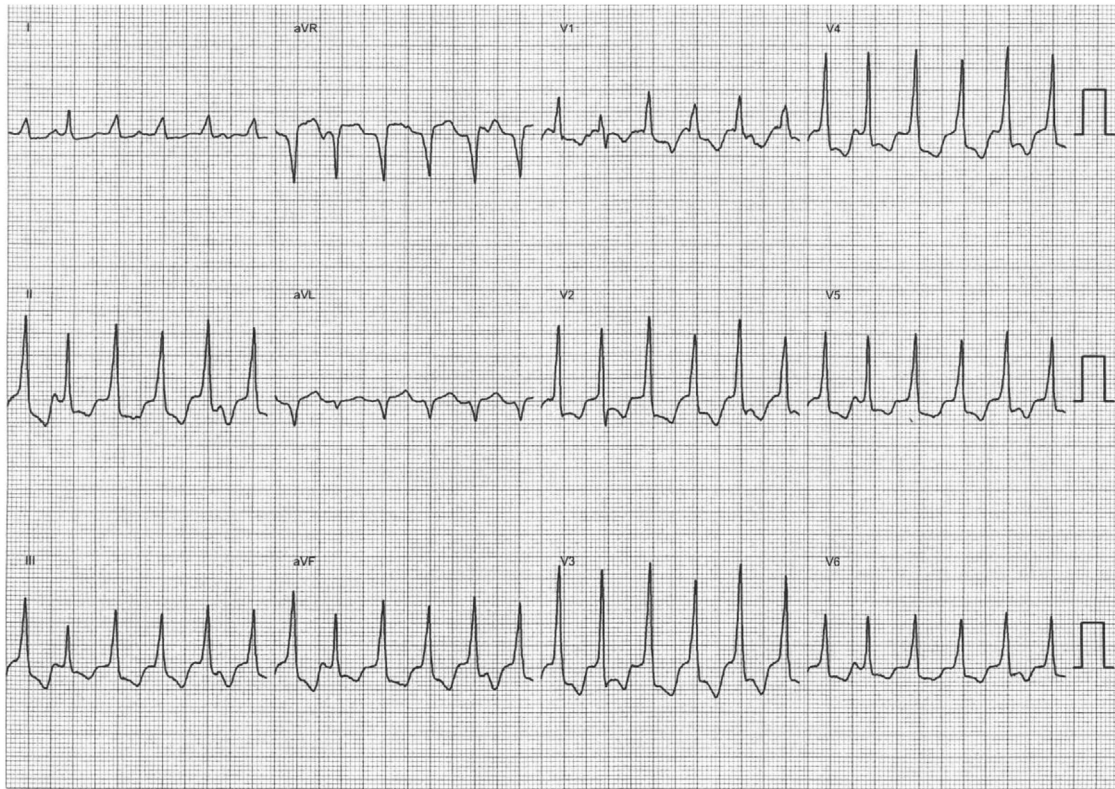


Figure 1 Twelve-lead electrocardiogram of the monomorphic ventricular tachycardia induced during electrophysiology study. The tracing is characterized by an inferior axis, right bundle branch block morphology and dominant R waves across the precordium are also present, suggesting a left-sided focus, suspected to originate from around the mitral annulus.

aorta and contact the aortic valve while in a protected conformation. This maneuver could be accomplished within the descending aorta by engaging the tip of the catheter in the contralateral common iliac artery or a subcostal artery and using gentle deflection and forward movement to manipulate the catheter tip into the desired shape.

Injury to the aorta can be avoided entirely by accessing the LV via a transeptal approach; however, we typically favor a retrograde approach when ablating idiopathic VT suspected to originate from the left heart, for 2 reasons. First, electrocardiographic information, while very useful, is imperfect at localizing VT origin for several reasons that include variability in cardiac anatomy and intramyocardial fibrosis. As such, a prudent strategy to these ablations involves collecting as much mapping data as possible. A retrograde approach allows for mapping of the left ventricular outflow tract and the aortic cusps for a potential target prior to engaging the LV and thereby provides the opportunity to obtain data from the greatest number of locations prior to deciding on an optimal location to deliver therapy. Second, with the transeptal approach it may be more challenging to achieve adequate contact and stability along the intraventricular septum and under the mitral valve. A transeptal approach should be considered in patients with a contraindication to retrograde access, such as those with severe peripheral vascular disease, known disease of the aorta, or the presence of either a prosthetic aortic valve or severe aortic valvular disease.

Although ablation-related complications involving the aorta are infrequent, they can have catastrophic consequences. Iatrogenic aortic dissection occurring during cardiac surgery or cardiac catheterization has a reported mortality rate of 35%.⁵ Though early recognition of aortic dissection

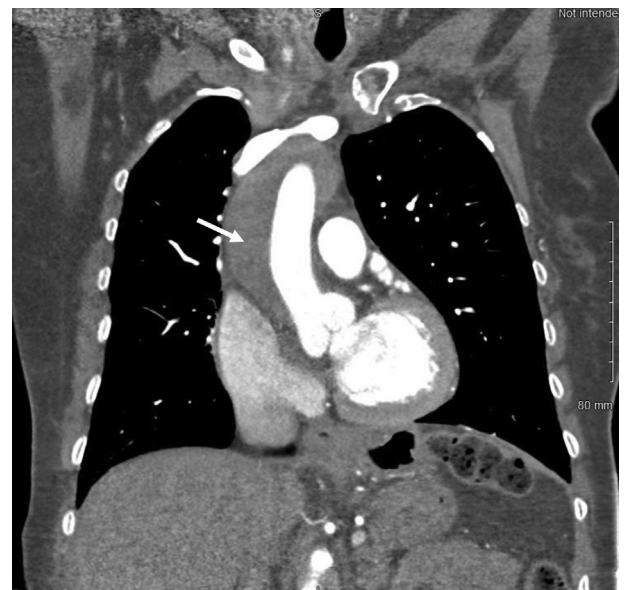

Figure 2 A computed tomography angiogram demonstrated a type A aortic dissection extending from the aortic root and involving the entire thoracic aorta (white arrow).

is vital, identifying a significant aortic injury quickly during cardiac ablation presents a problem. Unlike injury to the coronary arteries, which often can be recognized by acute ST-segment changes, early detection of acute aortic dissection is primarily made by symptoms. This assessment is not possible when patients are under general anesthesia, as is often the case for VT ablations, potentially delaying a diagnosis for several hours. Even in patients undergoing ablation with conscious sedation, chest pain is not uncommon after application of radiofrequency therapy to the heart and may also delay a diagnosis of acute aortic dissection.

If clinical suspicion for iatrogenic aortic dissection is high, transesophageal echocardiography can offer a rapid intraprocedural aortic assessment in patients under deep sedation and general anesthesia even when they are hemodynamically unstable. Identification of an intimal flap within the aorta in 2 separate views has a high sensitivity and specificity for aortic dissection and additionally allows for evaluation of the pericardial space, aortic valve function, and the coronary arteries.⁶ Intracardiac echocardiography (ICE) is also capable of rapidly providing views of the heart and the ascending aorta, particularly if an ICE catheter is already in place to guide the VT ablation. Once in the heart, an ICE catheter can be advanced to the junction of the superior vena cava and the right atrium and tilted to provide a longitudinal view of the ascending aorta. Caution must be used when interpreting ultrasound images to identify an aortic dissection, as this modality can produce false-negative results from poor visualization of the proximal aortic arch and false-positive results from misinterpretation of ultrasound images.

We report this case as an example of a rare, but potentially life-threatening, complication of VT ablation via a retrograde aortic approach. Although this was a serious complication, we could manage it quickly and effectively by promptly recognizing our patient's unexpected symptoms, utilizing the diagnostic tools at our disposal to identify the most likely etiology of these symptoms, immediately terminating the procedure when we were suspicious of a potentially catastrophic problem, and rapidly involving the surgical team.

Our patient would have been put at substantially more risk had we continued the ablation, because an extended procedure would have subjected her to a longer period of anticoagulation and additional catheter manipulation. In the setting of an acute aortic dissection, this would have likely resulted in mortality.

Conclusions

Iatrogenic ascending aorta dissection during cardiac ablation via a retrograde approach is a rare complication, but one that carries a high morbidity and mortality, particularly if unrecognized for an extended period of time. We propose that the risk of injury to the aorta can be reduced by gentle manipulation of the ablation catheter into a pigtail shape closer to the femoral access site—ideally using the contralateral common iliac artery—thereby allowing the catheter to traverse the entire aorta and engage the aortic valve in a protected conformation. We additionally suggest selecting a transseptal approach in patients with known or suspected disease in the aorta, aortic valve, or peripheral vasculature. On suspicion of an aortic complication, immediate reversal of anticoagulation, appropriate diagnostic imaging, and surgical consultation are essential.

References

1. Perez-Castellano N, Garcia-Fernandez MA, Garcia EJ, Delcan JL. Dissection of the aortic sinus of Valsalva complicating coronary catheterization: cause, mechanism, evolution, and management. *Cathet Cardiovasc Diagn* 1998;43:273–279.
2. Calkins H, Epstein A, Packer D, et al. Catheter ablation of ventricular tachycardia in patients with structural heart disease using cooled radiofrequency energy: results of a prospective multicenter study. Cooled RF Multi Center Investigators Group. *J Am Coll Cardiol* 2000;35:1905–1914.
3. Janeira LF. Coronary artery dissection complicating radiofrequency catheter ablation via the retrograde approach. *Pacing Clin Electrophysiol* 1998;21:1327–1328.
4. Olsson A, Darpo B, Bergfeldt L, Rosenqvist M. Frequency and long term follow up of valvar insufficiency caused by retrograde aortic radiofrequency catheter ablation procedures. *Heart* 1999;81:292–296.
5. Januzzi JL, Sabatine MS, Eagle KA, et al. Iatrogenic aortic dissection. *Am J Cardiol* 2002;89:623–626.
6. Cigarroa JE, Isselbacher EM, DeSanctis RW, Eagle KA. Diagnostic imaging in the evaluation of suspected aortic dissection. Old standards and new directions. *N Engl J Med* 1993;328:35–43.