

Tissue Contraction—A New Paradigm in Breast Reconstruction

Hilton Becker, MD, FACS*†‡
Olga Zhadan, MD, MSS§

Background: Skin expansion is commonly needed in order to reconstruct the breast following modified radical mastectomy. With the advent of skin-sparing and nipple-sparing techniques, expansion is no longer necessary. The natural ability of healing tissues to contract can be advantageously used to improve the outcomes of immediate prepectoral breast reconstruction.

Methods: A prospective analysis of the results of 20 prepectoral breast reconstructions following skin-sparing or nipple-sparing mastectomies was performed. Reconstruction was performed using the adjustable breast implant initially under-filled with air. No acellular dermal matrix or mesh support was used. Further air was added during the follow-up office visits. Air was replaced with normal saline when the desired breast size was achieved. The adjustable implants were replaced with silicone gel implants when necessary.

Results: Contraction of the skin flap over the underfilled implant was noticed in all patients. Five patients (25%) developed a seroma, and 2 patients had hematoma of the breast pocket. Wound-edge necrosis required debridement in 2 patients (10%). Complications were all resolved without implant loss.

Conclusions: Tissue contraction can be successfully utilized in breast reconstruction following skin-sparing and nipple-sparing mastectomy. Contraction results in thickening and elevation of the flap, eliminating the need for skin excision or the use of acellular dermal matrix. The partially filled implant functions as a spacer, preventing the flap from adhering to the underlying muscle and avoiding pressure on the skin flap. (*Plast Reconstr Surg Glob Open* 2018;6:e1865; doi: 10.1097/GOX.0000000000001865; Published online 13 July 2018.)

BACKGROUND

The shift from modified radical mastectomy to skin-sparing and nipple-sparing mastectomy offers new options for immediate breast reconstruction.¹ Tissue ex-

pansion is no longer crucial, especially with the advent of prepectoral reconstruction. In fact, with skin-sparing mastectomies, patients may have an excess of skin.^{2,3} A Wise pattern reduction type of incision is often used to excise the excess of skin.^{4,5} However, this carries the additional risk of vascular compromise and complicated wound healing.⁶

In cases in which a delayed reconstruction is performed, the skin flap contracts, thickens, elevates, and becomes adherent to the underlying muscle (Fig. 1). We have noticed that mastectomy flaps will contract in a similar fashion to the size of an underfilled implant, especially when it is partially filled with air. Because air is lighter than saline, there is less pressure exerted on the inferior skin flap. Contraction results in elevation and thickening of the flap, minimizing the need for acellular dermal matrix (ADM). Therefore, instead of performing delayed reconstruction following mastectomy, the adjustable breast

From the *Hilton Becker Clinic of Plastic Surgery, Boca Raton, Fla.; †Charles E. Schmidt College of Medicine, Florida Atlantic University, Boca Raton, Fla.; ‡Department of Plastic and Reconstructive Surgery, Cleveland Clinic Florida, Weston, Fla.; and §Charles E. Schmidt College of Medicine, Florida Atlantic University, Boca Raton, Fla.

Received for publication April 14, 2018; accepted May 22, 2018.

Presented at Plastic Surgery The Meeting 2017, Instructional Course "Pre-Pectoral Breast Augmentation and Reconstruction," October 6, 2017, Orlando, Fla.

The ethical principles stated in the 1964 Declaration of Helsinki were strictly followed.

Copyright © 2018 The Authors. Published by Wolters Kluwer Health, Inc. on behalf of The American Society of Plastic Surgeons. This is an open-access article distributed under the terms of the Creative Commons Attribution-Non Commercial-No Derivatives License 4.0 (CCBY-NC-ND), where it is permissible to download and share the work provided it is properly cited. The work cannot be changed in any way or used commercially without permission from the journal. DOI: 10.1097/GOX.0000000000001865

Disclosure: Dr. Becker is a consultant for Mentor Corp. Dr. Zhadan declares no disclosures. The Article Processing Charge was paid for by the authors.

Supplemental digital content is available for this article. Clickable URL citations appear in the text.

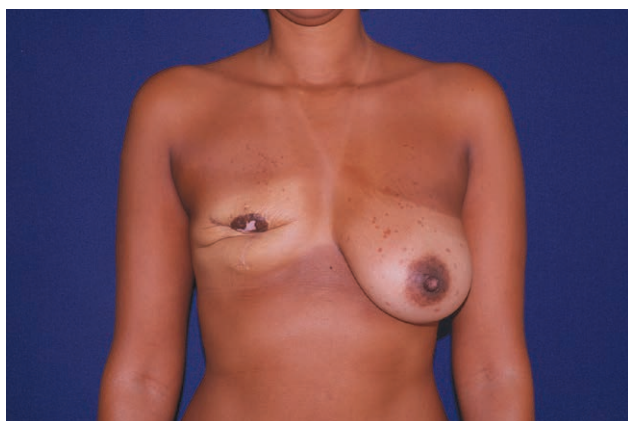


Fig. 1. Patient following skin-sparing mastectomy without reconstruction. Skin flap attaches to the chest wall, contracts, and thickens.

implant can be placed virtually empty as a spacer with little to no additional risk of skin flap compromise.

The inherent ability of the skin to contract can be utilized advantageously in immediate breast reconstruction surgery. We present a series of 20 cases in which skin contraction was shown to facilitate breast reconstruction outcomes.

PATIENTS AND METHODS

A prospective analysis of the outcome results of 20 consecutive prepectoral adjustable Spectrum implant-based breast reconstructions following skin-sparing or nipple-sparing mastectomies was performed. Patients were closely followed from May 2016 to September 2017 (mean time of follow-up was 12 months).

Patients included in the study ranged in age from 27 to 76 (mean, 53 years) with skin excess following skin-sparing or nipple-sparing mastectomy. Patients who exhibited any degree of breast ptosis preoperatively and were thought to

possibly benefit from skin contraction were included in the series. Patients who underwent sentinel lymph node biopsy or axillary lymph node dissection were not excluded from the study, and their management was not different. All the cases were performed by 1 plastic surgeon in a single institution. The analyzed data included patient's age, diagnosis, amount of air inflated to the implant initially and subsequently, timeline of additional air inflation during the office visits, postoperative complications, and additional interventions. Cosmetic outcome and patient satisfaction were documented. The ethical principles stated in the 1964 Declaration of Helsinki were strictly followed.

The nipple-sparing mastectomy was performed by a general surgeon. The axilla and lateral mastectomy pocket were closed using a running No. 1 STRATAFIX suture. The smooth Spectrum adjustable saline implant was used in all cases. The implants were placed prepectoral and initially underfilled with varying volumes of air to prevent collapse of the implant (Fig. 2B). The amount of air ranged from 10% to 70% (mean 40%) of the implant capacity. No ADM or mesh support was utilized, and skin flaps were allowed to contract over an underfilled implant.

Where skin contraction was desired, the implant was filled with the lowest volume of air that would support the implant and prevent folding of the skin flap. Close clinical follow-up was performed postoperatively in all cases. Patients were seen every day for the first 3–4 days after surgery, then once or twice a week for the following 4 weeks, and biweekly after that. Depending on the needed degree of contraction, implants were left underfilled for up to 10 weeks (average 4 weeks) (Fig. 2C). When further air was added, the air syringe filters (Cole-Parmer, Vernon Hills, Ill.) were used as a precautionary measure through the remote injection port.⁷

When the desired healing and cosmetic results were achieved, the air was replaced with saline (Fig. 2D). Rippling of the saline-filled implant was seen in 4 patients

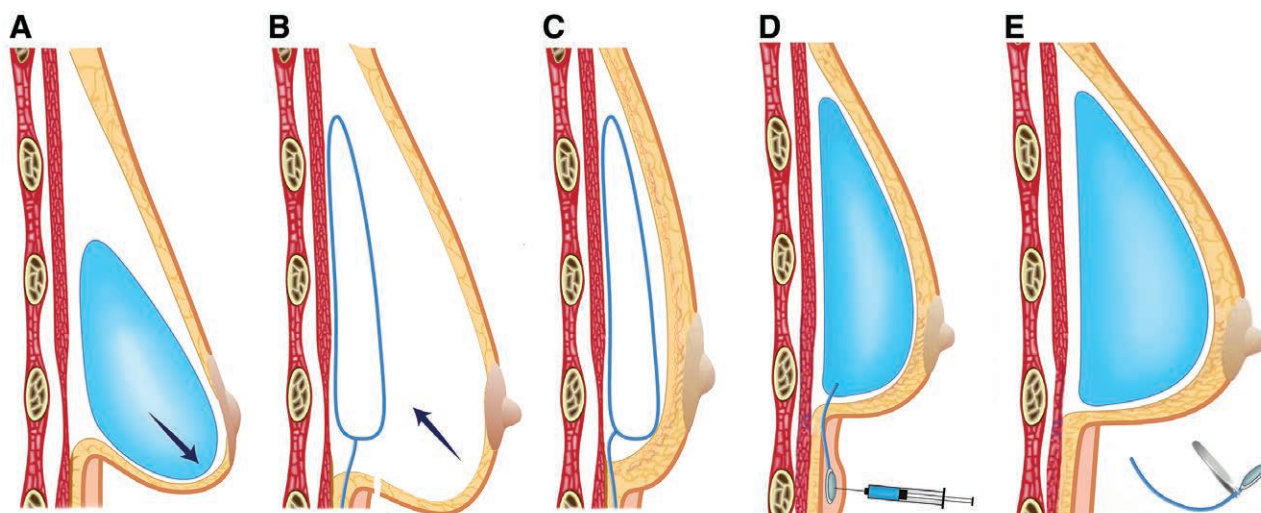


Fig. 2. Schematic diagrams of the reconstructive technique. A, Expander/implant filled with saline places pressure on the lower pole. B, Prepectoral placement of the adjustable implant underfilled with air. C, Skin contracts and thickens. D, Air is replaced with saline to achieve the desired size. E, Injection port removed.

(20%). It was successfully corrected with fat injections. The injection port was removed, and the saline implant retained as the definitive implant (Fig. 2E, **Supplemental Digital Content Fig. 1**).

If rippling was present or at the patient's request, the saline-filled implant was replaced with a silicone gel implant. At this stage, further fat injections were performed. In patients who had the adjustable Spectrum implants exchanged for gel implants, a small degree of skin adjustment was performed when necessary.

RESULTS

Twenty consecutive patients (36 breasts) underwent prepectoral breast reconstruction with the Spectrum adjustable implant.

Eighteen patients (90%) had been diagnosed with breast cancer; 15 patients (75%) chose bilateral mastectomy with immediate reconstruction. One patient (5%) had a history of contralateral breast cancer with mastectomy and implant-based reconstruction. One patient (5%) chose to undergo mastectomy and contralateral breast reduction. One patient (5%) had mastectomy of the affected side only. The other 2 patients (10%) had bilateral prophylactic mastectomy for positive BRCA2 genotype and LCIS.

All patients in the series had an excess of skin and/or breast ptosis. Tissue contraction and elevation of the flap occurred in all patients. The exact measurements were not done; however, the amount of elevation is self-evident

from the before and after photographs (Figs. 3, 4, 5; **Supplemental Digital Content Fig. 2**).

There was a small amount of air diffusion through the expander. The patients were seen at least weekly for 4 weeks, and air diffusion was not seen as a problem. Five patients (25%) developed seromas. One of them had a recurrent seroma after radiation therapy. Seromas were successfully aspirated with the Blunt SeromaCath.⁸ Hematoma evacuation in the early postoperative period was performed in 2 patients. Wound edge necrosis developed in 2 patients (10%). One patient had minimal skin necrosis, which was debrided in the office. The second patient with skin necrosis was successfully treated without implant removal. Emptying the implant completely facilitated correction of these complications. All implants were salvaged.

After the air was converted to saline, 9 patients (45%) requested to proceed with exchange for the gel implant. The time frame for conversion to silicone was a minimum of 3 months to allow wound healing.

DISCUSSION

Tissue contraction is an integral part of wound healing. Wound contraction is brought about by myofibroblasts, which are derived from fibroblasts when gaining intracellular actin microfilaments. The actin microfilaments generate the force that results in matrix contraction.⁹ Fibroblasts differentiate into myofibroblasts by a cell density-dependent mechanism. Masur et al.¹⁰ concluded

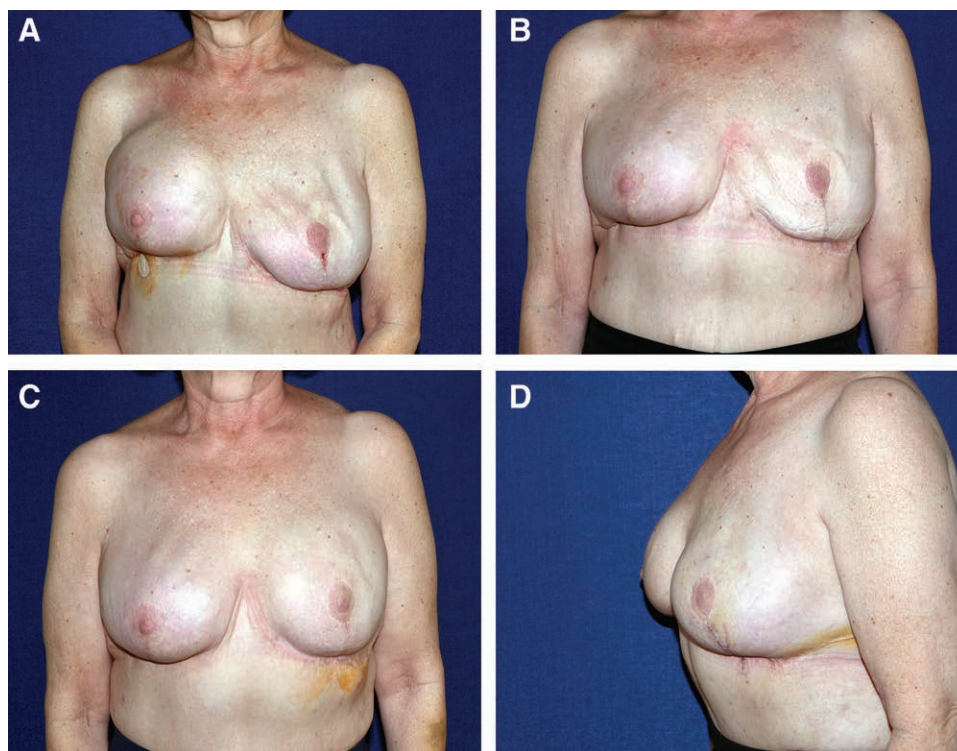


Fig. 3. Patient with carcinoma of right breast. A, Four weeks following bilateral prophylactic mastectomy with reconstruction. Left breast has become progressively more ptotic. B, Seven weeks postoperative. Left implant deflated to facilitate skin contraction. C, D, Air added. Correction was achieved without further surgery. Three months after breast reconstruction.

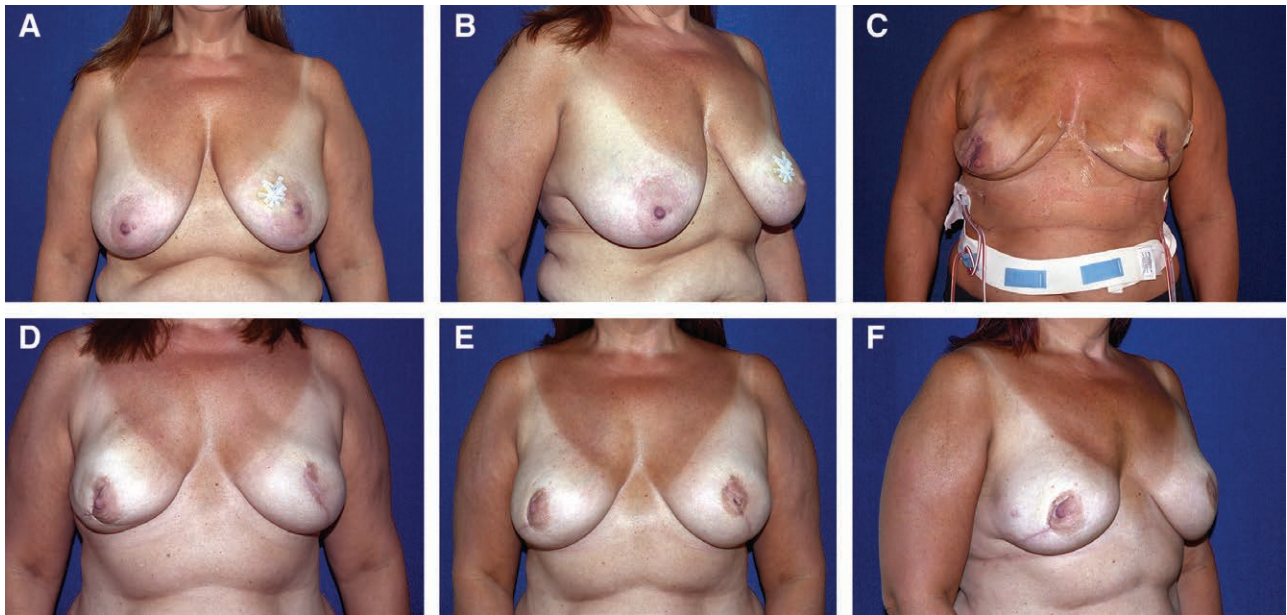


Fig. 4. Patient with carcinoma of left breast. A, B, Preoperative views. C, Early postoperative result (3 days) following bilateral mastectomy and prepectoral reconstruction. The Spectrum adjustable implants underfilled with air. D, Six months postoperative, implants filled with saline. E, F, Final result at 7 months following conversion to gel implant. Tattooing of left nipple-areola complex has been performed.

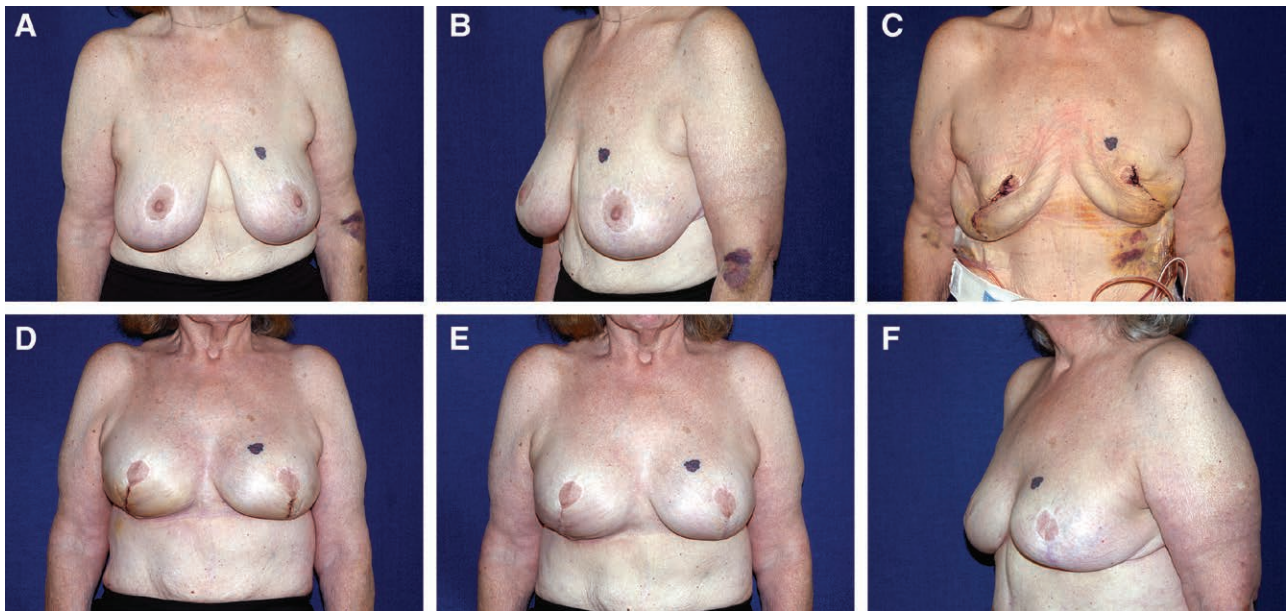


Fig. 5. Patient with carcinoma of right breast, having had previous breast reduction. A, B, Preoperative views. C, Six days following bilateral mastectomy, implants underfilled. D, Following exchange for gel implants, postoperative day 8. E, F, Final result at 2 months.

that absence of cell-cell contact is the proximate cause of myofibroblast differentiation. Myofibroblasts can differentiate back into fibroblasts with reestablishment of cell-cell contact.

Another key point in the fibroblast-myofibroblast conversion is the tissue tension. Fibroblasts experience tension in granulation tissue. Hinz et al.¹¹ revealed that fibroblasts seeded in the in vitro collagen lattice, which remained attached to the underlying surface, developed tension. These cells had myofibroblast phenotype. In

the following in vivo study, the authors¹² showed that the mechano tension causes the generation of cytoplasmic stress fibers expressing alpha smooth muscle actin, a molecular marker of myofibroblasts.

Following injury to the skin, the dermis and subcutaneous tissue of the mastectomy skin flap will contract initially as a result of reduction in weight with the action of elastin fibers. Further contraction is a part of the healing process and continues until myofibroblasts associate with collagen extracellular matrix and return to the fibroblast pheno-

type. Contact of the exposed flap with the underlying tissues or the implant surface induces this transformation as well. If the implant is smaller than the pocket, contraction will occur until the space is obliterated.

Following modified radical mastectomies, it is necessary to expand the overlying muscle and remaining skin to create a breast mound. That is achieved using a tissue expander placed in the submuscular position. With the advent of skin-sparing mastectomies and prepectoral reconstruction, there is rarely a need for expansion.¹³ In fact, in these cases, there is often an excess of skin. By allowing natural skin contraction to occur, skin excision is not required. Furthermore, skin contraction results in elevation and thickening of the skin flap, which is advantageous in terms of implant coverage, thus lowering the need for ADM. Skin contraction is commonly seen in cases in which a skin-sparing mastectomy is performed and no implant is placed. The loose skin flap contracts and starts adhering to the underlying muscle. The contraction continues until myofibroblasts of the flap convert back to fibroblasts induced by contact with the rigid muscle surface. Placing an underfilled adjustable implant beneath a skin flap prevents adhesion of the flap to the underlying muscle. The effect of delay is still achieved, and there is no further compromise to the skin flap. The surgeon is able to control the amount of contraction by varying the volume of the implant. Underfilling the implant will result in contraction of the skin pocket until the complete exposed surface is in contact with the implant. Excessive contraction is prevented by filling the implant to the desired volume. Skin contraction results in a mastopexy effect, thus reducing or even eliminating the need for skin excision. The low rate of rippling is attributable to the firmer thickened flap combined with fat injections.

The risk of skin flap necrosis or wound dehiscence is reduced by avoiding any additional pressure on the skin flap and incision. When skin flap necrosis occurs, the implant can be completely emptied, reducing all tension on the flaps, thus facilitating debridement and secondary closure. The complication rate following immediate breast reconstruction ranges between 5% and 40%. The use of an adjustable implant without ADM reduces the postoperative complication rate.¹⁴ Although ADM may reduce capsular contracture, the complications of seroma and infection, and the cost are important considerations. In our study, prepectoral breast reconstruction was performed using the Spectrum-adjustable saline implant partially filled with air. The low-pressure, low-weight implant allowed the inherent ability of the skin to contract without undue pressure on the lower flap as seen with a saline-filled expander or gel implant, and thus avoiding the vascular compromise. The implant partially filled with air placed at the time of mastectomy functions as a spacer, which prevents the flap from adhering to the underlying muscle. The air spreads in the entire lumen instead of pooling in the lower pole as seen with a saline-filled implant (Fig. 2A, **Supplemental Digital Content** Fig. 3, 4). Flap adhesion to the chest wall is thus prevented. The need for delayed or delayed-immediate reconstruction is reduced.¹⁵ The skin flap is

thickened, thereby reducing the need for ADM. Also, the lower weight and smooth surface are more comfortable for patients who have higher immediate postoperative acceptance.

We have not seen capsular contracture in the studied group of patients. There may be factors associated with flap shrinkage that play a role. Longer follow-up is necessary for clarification.

The adjustable implant (Spectrum) has volume fill recommendations as dictated by the manufacturer. However, these volumes are not clinically related and not supported by clinical data. Our consent form indicates that exceeding the volumes is considered an off-label use. Exceeding manufacturer fill volumes has been previously published.¹⁶

A major advantage of underfilling the implant with air is that the position of the implant can be modified postoperatively. If the implant is sitting too low, the volume of air can be reduced and a strap applied inferiorly for 1–2 weeks (Fig. 3). This will result in elevation of the implant, which can then subsequently be filled with saline. If the implant is sitting too high, the air is replaced with saline and an upper pressure strap applied that will lower the implant. This is as opposed to expanders with fixation patches, which cannot be repositioned postoperatively.

A textured integral valve expander gradually filled with saline would not function postoperatively as a smooth adjustable implant initially partially filled with air.

One of the potential downsides of our technique is premature skin contraction around an underfilled implant. Frequent clinical follow-up is therefore required to control the degree of pocket contraction around the implant.

Limitations of this study are the number of patients and length of follow-up. However, excellent results and low complication rate together with significant cost saving justify early publication of this techniques. A study reporting a larger cohort of patients and longer follow-up is currently underway.

CONCLUSIONS

Tissue contraction facilitates breast reconstruction following skin-sparing and nipple-sparing mastectomy by eliminating the need for skin excision. The flap is allowed to contract and elevate in a controlled fashion around the underfilled implant. The partially filled implant functions as a spacer, preventing the flap from adhering to the underlying muscle and avoiding pressure on the skin flap. The skin flap thickens, providing more effective implant coverage without the need for ADM.

Hilton Becker, MD, FACS

Hilton Becker Clinic of Plastic Surgery

670 Glades Road #220

Boca Raton, FL 33431

E-mail: hilton@beckermnd.com

REFERENCES

1. Panchal H, Matros E. Current trends in postmastectomy breast reconstruction. *Plast Reconstr Surg*. 2017;140:7S–13S.
2. Sbitany H, Piper M, Lentz R. Prepectoral breast reconstruction: a safe alternative to submuscular prosthetic reconstruction following nipple-sparing mastectomy. *Plast Reconstr Surg*. 2017;140:432–443.

3. Vidya R, Iqbal FM. A guide to prepectoral breast reconstruction: a new dimension to implant-based breast reconstruction. *Clin Breast Cancer*. 2017;17:266–271.
4. Brown RH, Siy R, Khan K, et al. The superomedial pedicle wise-pattern breast reduction: reproducible, reliable, and resilient. *Semin Plast Surg*. 2015;29:94–101.
5. Cutress RI, Simoes T, Gill J, et al. Modification of the Wise pattern breast reduction for oncological mammaplasty of upper outer and upper inner quadrant breast tumours: a technical note and case series. *J Plast Reconstr Aesthet Surg*. 2013;66:e31–e36.
6. Jagsi R, Jiang J, Momoh AO, et al. Complications after mastectomy and immediate breast reconstruction for breast cancer: a claims-based analysis. *Ann Surg*. 2016;263:219–227.
7. Becker H, Zhadan O. Filling the spectrum expander with air—a new alternative. *Plast Reconstr Surg Glob Open*. 2017;5:e1541.
8. Becker H, Klimczak J. Aspiration of periprosthetic seromas using the blunt seromaCath. *Plast Reconstr Surg*. 2016;137:473–475.
9. Desmoulière A, Chaponnier C, Gabbiani G. Tissue repair, contraction, and the myofibroblast. *Wound Repair Regen*. 2005;13:7–12.
10. Masur SK, Dewal HS, Dinh TT, et al. Myofibroblasts differentiate from fibroblasts when plated at low density. *Proc Natl Acad Sci U S A*. 1996;93:4219–4223.
11. Hinz B, Celetta G, Tomasek JJ, et al. Alpha-smooth muscle actin expression upregulates fibroblast contractile activity. *Mol Biol Cell*. 2001;12:2730–2741.
12. Hinz B, Gabbiani G, Chaponnier C. The NH2-terminal peptide of alpha-smooth muscle actin inhibits force generation by the myofibroblast *in vitro* and *in vivo*. *J Cell Biol*. 2002;157:657–663.
13. Becker H, Lind JG 2nd, Hopkins EG. Immediate implant-based prepectoral breast reconstruction using a vertical incision. *Plast Reconstr Surg Glob Open*. 2015;3:e412.
14. Inbal A, Gur E, Lemelman BT, et al. Optimizing patient selection for direct-to-implant immediate breast reconstruction using Wise-pattern skin-reducing mastectomy in large and ptotic breasts. *Aesthetic Plast Surg*. 2017;41:1058–1067.
15. Zenn MR. Staged immediate breast reconstruction. *Plast Reconstr Surg*. 2015;135:976–979.
16. Becker H, Carlisle H, Kay J. Filling of adjustable breast implants beyond the manufacturer's recommended fill volume. *Aesthetic Plast Surg*. 2008;32:432–441.