


CLINICAL ARTICLE

Using Satellite Rod Technique in Patients with Severe Kyphoscoliosis Undergoing Three-Column Osteotomy: A Minimum of 2 Years' Follow-up

Zongshan Hu, PhD^{1,2,3†}, Dun Liu, PhD^{1†}, Zezhang Zhu, MD^{1,3}, Yong Qiu, MD^{1,3}, Zhen Liu, MD^{1,3} 

¹Department of Spine Surgery, Drum Tower Hospital of Nanjing University Medical School, Nanjing and ²Department of Orthopaedics and Traumatology, The Chinese University of Hong Kong and ³The Joint Scoliosis Research Center of the Chinese University of Hong Kong and Nanjing University, Hong Kong, China

Objective: To introduce the satellite rod technique utilized in severe spinal deformity after three-column osteotomy (3CO) and to evaluate the radiographic and clinical outcomes at 2-year follow-up, further discussing its utilization in this particular cohort.

Methods: A total of 32 (19 females and 13 males) with an average age of 32.9 ± 18.3 years from December 2012 to March 2016 were retrospectively reviewed. Radiographic measurements were performed on standing full-spine anteroposterior and lateral radiographs preoperatively, postoperatively, and at last follow-up. The coronal parameters including Cobb angle and distance between C₇ plumb line and center sacral vertical line (C7PL-CSVL), as well as the sagittal parameters including global kyphosis (GK) and sagittal vertical axis (SVA) were measured at three time points. The Scoliosis Research Society-22 questionnaire (SRS-22) was fulfilled preoperatively and at each follow-up. Paired *t* test would be used to determine whether there was a significant difference between time points.

Results: A total of 32 patients were enrolled in this study with mean age of 32.9 ± 18.3 (range, 12 to 66) years old. Twenty patients underwent pedicle subluxation osteotomy (PSO) and 12 patients underwent vertebral column resection (VCR). The pathogenesis of this cohort included neuromuscular scoliosis (11 cases), congenital kyphoscoliosis (seven with hemivertebrae and five with segmentation failure), degenerative spinal deformity (five cases), and thoracolumbar tuberculosis with angular kyphosis (four cases). The post-operative Cobb angle decreased significantly from $49.1^\circ \pm 28.0^\circ$ to $19.0^\circ \pm 16.7^\circ$ with a correction rate of $65.2\% \pm 21.8\%$. At final follow-up, the average Cobb angle was $19.4^\circ \pm 16.9^\circ$ and no obvious loss of correction was found. The preoperative, postoperative, and last follow-up C7PL-CSVL were 23.9 ± 14.5 mm, 15.7 ± 11.1 mm, and 12.1 ± 7.4 mm, respectively. Significant postoperative improvement was attained while there was no change observed at last follow-up. Postoperative GK significantly improved from $73.8^\circ \pm 28.1^\circ$ to $23.2^\circ \pm 11.7^\circ$ with the correction rate of $66.0\% \pm 17.9\%$. SVA decreased significantly from 42.9 ± 33.9 mm to 24.1 ± 21.1 mm. The average GK and SVA at final follow-up were $22.7^\circ \pm 10.1^\circ$ and 23.5 ± 21.1 mm, respectively and no obvious loss of correction was observed of them during follow-up. In addition, no change or loss of motor or somatosensory evoked potential occurred during surgery. During the follow-up, two malposition screws and one rod breakage were found.

Conclusion: The satellite rod used in patients with severe kyphoscoliosis undergoing 3CO could yield favorable radiological and clinical outcomes. With the utilization of this technique, the coronal and sagittal balance could be well-maintained during follow-up.

Key words: Kyphosis; Osteotomy; Postoperative complication; Scoliosis

Address for correspondence Zhen Liu, MD, Department of Spine Surgery, the Affiliated Drum Tower Hospital of Nanjing University Medical School, Zhongshan Road 321, Jiangsu Province, Nanjing 210008, China, Tel: 86 135 8400 1928; Fax: 025 8310 2022; Email: dliuzhen@163.com

[†]These two authors contributed equally to this work.

Disclosure: Dr. Zhen Liu has received financial support from Natural Science Foundation of Jiangsu Province (BK20171116).

Received 11 May 2020; accepted 28 September 2020

Introduction

Severe spinal deformity is often involved with extensive structure abnormality in anterior and posterior column, sagittal malalignment, and coronal imbalance, which greatly increases difficulty and risk of correction surgery¹. Posterior spinal three-column osteotomies (3CO), including vertebral column resection (VCR), pedicle subtraction osteotomy (PSO), SRS-Schwab Grade IV osteotomy, and some modified techniques, have been widely used in severe spinal kyphoscoliosis with a favorable correction outcome²⁻⁴. However, undesired complications of complex spinal reconstruction remain a pressing issue, including rod breakage, correction loss, pseudarthrosis, junctional failure, and neurological injury⁵⁻⁷. In patients with severe kyphoscoliosis undergoing 3CO, the osteotomy sites and adjacent segments suffer from high mechanical stress. The deficient bone stock due to wide laminectomy and unstable bone fusion in the short-term after the operation may also increase the risks of implant-related complications. Ibrahim *et al.* concluded that the incidence of instrumentation failures in patients with adult spinal deformity undergoing PSO was about 22.0%⁸. In addition, Suk *et al.* reported that the incidence of failure rate of internal fixation was approximately 7.1% in patients with severe spinal deformity who underwent posterior VCR⁹. Therefore, the significance of the study lies in that it has the potential to decrease mechanical complications for the patients with severe kyphoscoliosis who underwent complicated spinal correction surgery, which could greatly improve satisfaction and quality of life postoperatively as well as during the long-term follow-up.

With the aim of reducing instrument-related complication, current research has reported a variety of key techniques in recent years, including “multiple rods” and outrigger rods, to create multiple-rod constructs. Technically, the supplemental rods are piggybacked from two longitudinal rods and can transfer with subsequent rod breakage either above or below the short rods. When this occurs, dissociation of the construct, loss of correction, and potential recurrence of deformity can happen¹⁰. Previous studies showed that the configuration with bilateral double parallel rods produces higher stress reduction on the implants at osteotomy segments^{11,12}, which creates a gradual transitional zone from osteotomy area to non-instrumented area to disperse stress and decrease the risk of proximal junctional kyphosis (PJK)¹³. However, the existing problems were whether this technique could be successfully and regularly used in adult patients with severe spinal deformity who underwent 3CO, and whether this technique could achieve a favorable correction and lower complication during follow-up, remained unclear.

In clinical practice, our center has routinely employed a complex satellite rod construct around osteotomy segments in the treatment of patients with severe spinal deformity. To the best of our knowledge, there are no clinical series documenting the use of satellite rod combined with duet screw in the treatment of severe spinal deformity who underwent

3CO. We hypothesized that this technique could be successfully applied in the surgical treatment for severe adult kyphoscoliosis. Therefore, the purpose of this study was: (i) to introduce the satellite rod technique utilized in severe spinal deformity after 3CO; (ii) to evaluate the radiographic and clinical outcomes of at 2-year follow-up; and (iii) to further discuss its utilization in this particular cohort.

Materials and Methods

Subjects

The inclusion criteria were as follows: (i) patients with congenital, neuromuscular, or degenerative kyphoscoliosis based on radiological criteria; (ii) treated with three-column osteotomy (vertebral column resection or pedicle subtraction osteotomy) and pedicle-screw instrumentation; (iii) satellite rods utilized at osteotomy area with or without neurological deficit before surgery; (iv) full-spine X-ray radiographs and function outcome were performed preoperatively and at 2-year follow-up. The exclusion criteria included: (i) patients with previous spinal trauma or surgery; (ii) incomplete radiological data; (iii) follow-up period less than 2 years. After the approval of institutional review board, a consecutive series of patients with severe kyphoscoliosis who underwent 3CO correction surgery with satellite rod constructs and with a minimum of 2-year follow-up were included in this study.

Surgical Technique

All surgeries were performed by one surgical team who were all experienced with the three-column osteotomy maneuver. The patients were placed in a prone position after general anesthesia. The levels to be fused were exposed and the posterior soft tissues were dissected subperiosteally according to the surgical strategies formulated preoperatively. The satellite rods were inserted *via* the following two methods.

Satellite Rod Technique with Duet Screws

Duet screws were routinely fixed into the distal and proximal pedicles adjacent to the vertebrae to be resected, which usually spanned from two vertebrae above to two vertebrae below. The traditional screws were then placed at the remaining pedicles and pre-contoured short satellite rod was fixed into the duet screws on the concave side, after which the 3CO was performed on convex side as needed. Similarly, the osteotomy at concave side was performed with satellite rod on convex side. The osteotomy gap was closed with compression force using bilateral satellite rods. Finally, the longitudinal rods connecting all the pedicle screws at each side were implanted with appropriate correction maneuvers, which formed an integral enhanced fixation and increase the stability across the osteotomy site (Fig. 1).

Satellite Rod Technique with Dual Head Connectors

Different from the above method, we firstly implanted the traditional pedicle screws into the vertebrae planned preoperatively from concave side to convex side. The 3CO was

Fig. 1 Schematic diagram of satellite rod with duet screw. (A) Pedicle screw positioning; (B) duet pedicle screw with satellite rod placing at concave side and 3CO at convex side; (C) duet pedicle screw and satellite rod placement at convex side with compression force to close osteotomy gap; (D) long rods connecting all the pedicle screws implanting at both sides with final correction maneuvers.

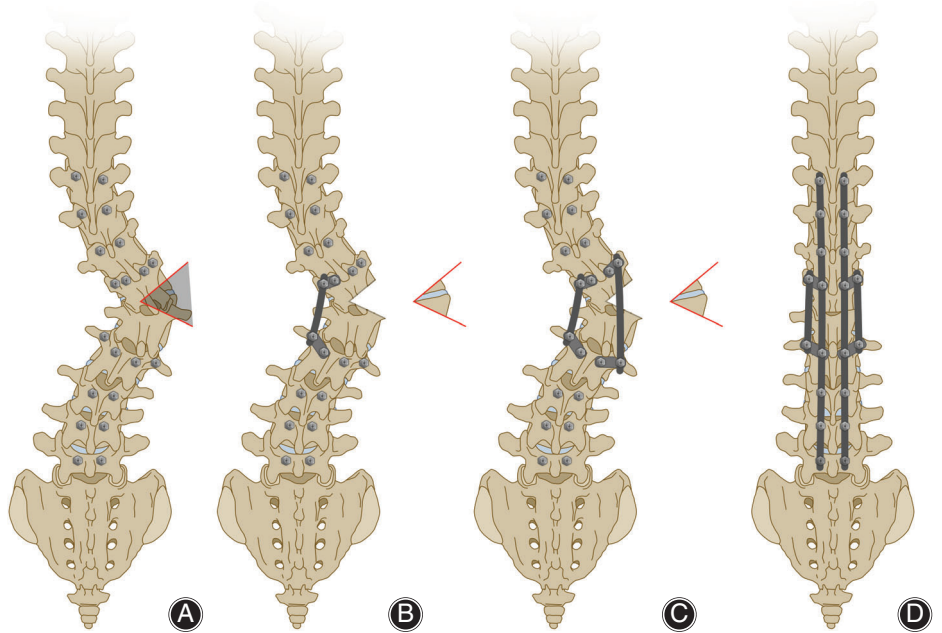
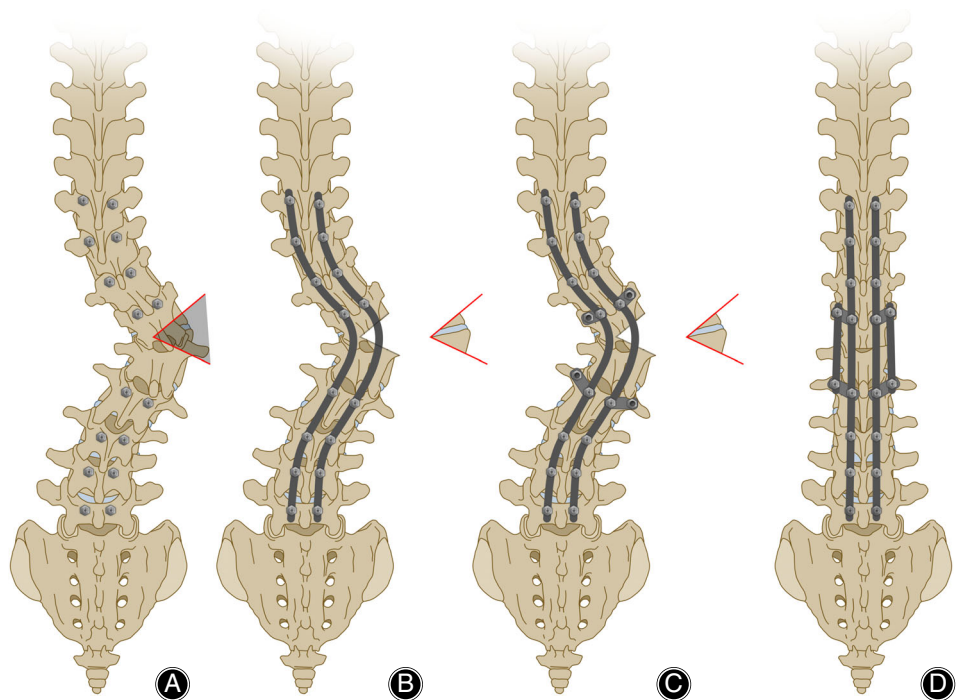


Fig. 2 Schematic diagram of satellite rod with duet-head screw. (A) Pedicle screw positioning; (B) 3CO at convex side and two traditional longitudinal rods placed at concave and convex side; (C) dual-head connectors were connected to longitudinal rods at osteotomy levels; (D) satellite rods inserted via dual-head connectors at both sides with final correction maneuvers.



performed in the same way and the two traditional longitudinal rods were attached into the screws bilaterally. At last, the satellite rods were inserted *via* dual-head connectors on one or both sides for the enhancement of local fixation¹⁴ (Fig. 2).

Finally, the mixtures of allogeneic and autologous bones were placed over the instrumented levels, and all

surgeries were monitored with intraoperative somatosensory evoked potential (SEP) and motor evoked potential (MEP).

Radiographic Measurements

Radiographic measurements were performed on standing full-spine anteroposterior and lateral radiographs. Preoperative and final follow-up parameters were measured as follows.

Cobb Angle

The angle between upper- and lower-end vertebrae of major curve in the coronal plane, which is a classical parameter to evaluate the curve magnitude of the spinal curvature in the coronal plane.

C₇ Plumb Line–Central Sacral Vertical Line (C7PL–CSVL)

The vertical distance between the plumb line across the center of C₇ (C7PL) and the vertical line across the center of S₁ (CSVL), which is a key index to evaluate trunk shift in the coronal plane.

Global Kyphosis (GK)

The angle from upper endplate of most tilted cephalad vertebrae to most tilted end vertebrae in the sagittal plane, which is a key parameter to measure the global sagittal balance.

Sagittal Vertical Axis (SVA)

The distance from the plumb line from the center of the C₇ (C7PL) to the posterior point of the upper sacral endplate surface, which is an important distance parameter of sagittal balance of the trunk.

Alignment-related complications were recorded including rod breakage and failure of foundation fixation. Alignment included proximal junctional kyphosis (PJK) and junctional kyphosis (DJK). Diagnosis of pseudarthrosis was made when there was radiographic evidence of lucency at fusion level.

Functional Outcome

Patient-reported outcomes were assessed using Scoliosis Research Society-22 questionnaire (SRS-22), which consists of five domains, including function, activity, self-image, mental health, and satisfaction. The clinical significance of the SRS-22 questionnaire is that it is a valid and well-accepted self-assessment instrument for functionally evaluating scoliosis. All the questionnaires were completed by the patients independently of the surgeons, preoperatively and at last follow-up.

Statistical Analysis

Distributions of variables were given as a mean and standard deviation (\pm). For the variables, including Cobb angle, GK, C7PL–CSVL, and SVA where data were collected preoperatively, postoperatively, and at latest follow-up, paired *t* tests were used to determine whether there was a significant difference between time points. A *P* value less than 0.05 was considered statistically significant.

Results

General Results

A total of 32 patients were enrolled in this study with mean age of 32.9 ± 18.3 (range, 12 to 66) years old. Twenty patients underwent PSO and 12 patients underwent VCR. The locations of apex were T₁₀ in one patient, T₁₁ in two, T₁₂ in seven, L₁ in 11, L₂ in eight, L₃ in two, L₅ in one, respectively. The pathogenesis of this cohort included neuromuscular scoliosis (11 cases), congenital kyphoscoliosis (seven with hemivertebrae and five with segmentation failure), degenerative spinal deformity (five cases), and thoracolumbar tuberculosis with angular kyphosis (four cases). For the comorbidity of these 32 patients, seven had associated incomplete paralysis in Frankel grade D; five had thoracic insufficiency syndrome; six had lumbar spinal stenosis. Seven patients underwent VCR, six patients underwent PSO. The osteotomy level was located at T₁₁ in six cases, at T₁₂ in nine, at L₁ in 11, and at L₂ in six, respectively. The mean levels fused were 10.4 ± 2.6 (range, 6–13) and the levels of satellite rod span were (through osteotomy area) 2.3 ± 0.7 (one to three levels superior or inferior to osteotomy level). The mean operation time was 3.5 ± 0.9 h and mean estimated blood loss was 1587 ± 545 mL.

Radiographic Outcomes

Radiographic measurements preoperatively and postoperatively and at latest follow-up were showed in Table 1.

TABLE 1 Comparison in radiographic measurements including Cobb angle, C7PL–CSVL, GK, and SVA, preoperatively, postoperatively, and at last follow-up

	Pre-op	Post-op	Last follow-up	Pre-op vs post-op	Post-op vs last follow-up
Cobb angle (°)	49.1 \pm 28.0 (10–103)	19.3 \pm 16.7 (1–65)	19.3 \pm 16.9 (1–66)	<i>P</i> = 0.000* <i>t</i> = 9.285	<i>P</i> = 0.786 <i>t</i> = –0.273
C7PL–CSVL (mm)	23.9 \pm 14.5 (4.9–69.8)	15.7 \pm 11.1 (1.8–45.0)	13.0 \pm 7.4 (1.4–28.9)	<i>P</i> = 0.023* <i>t</i> = 2.398	<i>P</i> = 0.089 <i>t</i> = 1.754
GK (°)	73.8 \pm 28.1 (20–153)	23.2 \pm 11.7 (7–56)	22.7 \pm 10.1 (10–49)	<i>P</i> = 0.000* <i>t</i> = 12.894	<i>P</i> = 0.089 <i>t</i> = 1.754
SVA (mm)	42.9 \pm 33.9 (6.9–156.6)	24.1 \pm 21.1 (1.7–84.6)	23.5 \pm 21.1 (3.9–84.6)	<i>P</i> = 0.003* <i>t</i> = 3.166	<i>P</i> = 0.827 <i>t</i> = 0.221

* Statistically significant if *P* < 0.05.; C7PL–CSVL, distance between C₇ plumb line and center sacral vertical line; GK, Global kyphosis; SVA, sagittal vertical axis.

Coronal Plane

The postoperative coronal Cobb angles significantly improved ($49.1^\circ \pm 28.0^\circ$ vs $19.3^\circ \pm 16.7^\circ$, $P < 0.001$) with a correction rate of $65.2 \pm 21.8\%$, as well as the C7PL–CSVL decreased evidently from 23.9 ± 14.5 mm to 15.7 ± 11.1 mm ($P = 0.023$). Similarly, significant improvement was attained postoperatively.

Sagittal Plane

GK ($73.8^\circ \pm 28.1^\circ$ vs $23.2^\circ \pm 11.7^\circ$, $P < 0.001$) had a correction rate of $66.0\% \pm 17.9\%$. SVA was corrected from 42.9 ± 33.9 mm to 24.1 ± 21.1 mm after operation ($P = 0.003$). At last follow-up, no significant correction loss was observed in both sagittal and coronal parameters (Fig. 3).

Functional Outcomes

The results of SRS-22 score were shown in Table 2. Compared to the preoperative result, all the domains show improvement in different levels at final follow-up. The score of pain domain was decreased from preoperative 3.2 ± 0.8 to 4.6 ± 0.5 at follow-up with the improvement of 30.3%. Self-image domain improved from 2.6 ± 0.8 to 4.3 ± 0.6 with the improvement of 16.2% ($P < 0.05$). In addition, no statistically significant improvement was observed in the domain of function/activity (4.2 ± 0.6 preoperatively, 4.4 ± 0.6 at follow-up) and mental health (4.0 ± 1.0 preoperatively, 4.4 ± 0.5 at follow-up).

Complications

One patient had incurred left longitudinal rod fracture due to traffic accident 2 years after surgery and underwent

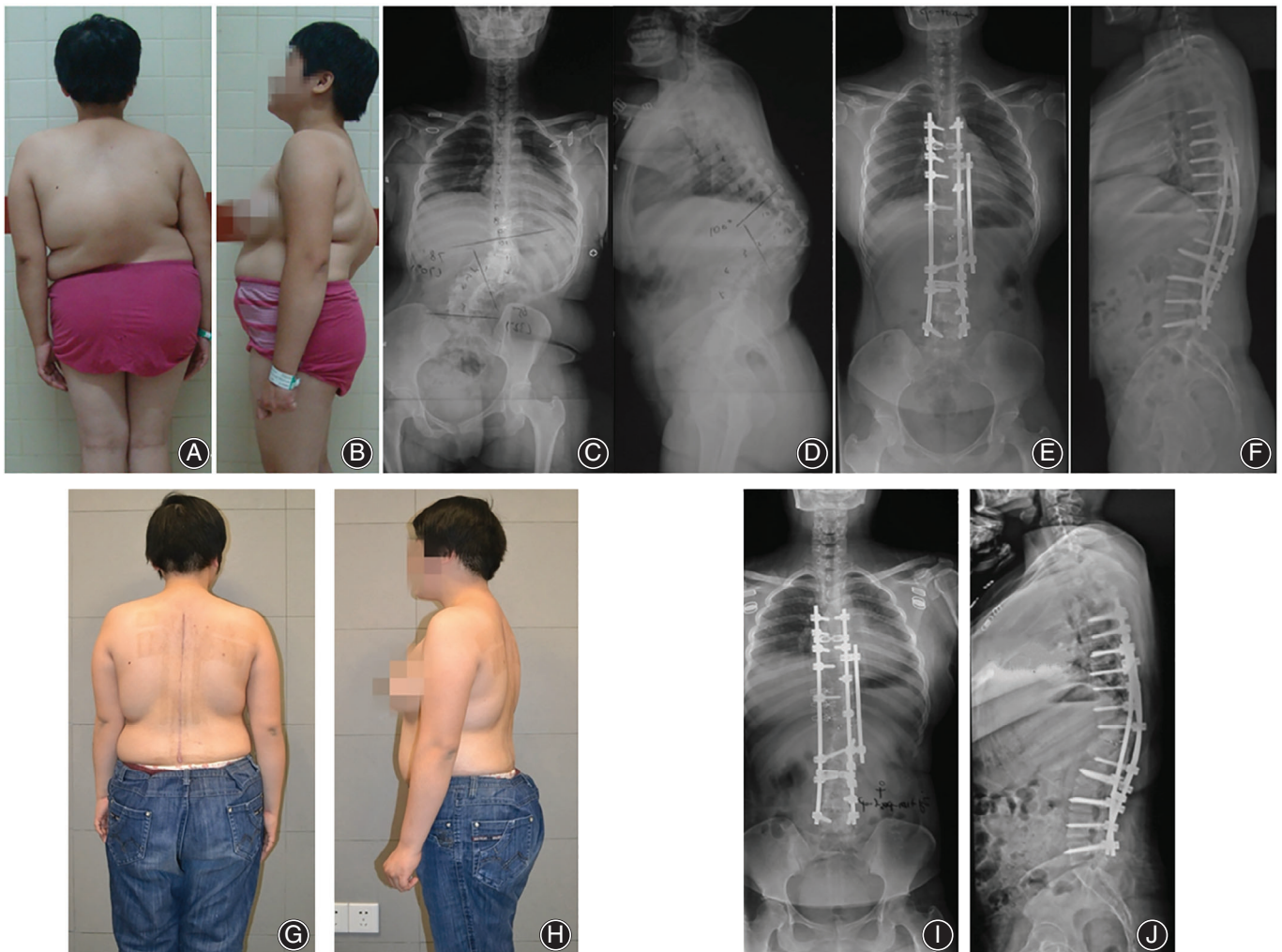


Fig. 3 A 29-year-old female with severe congenital thoracolumbar kyphoscoliosis (A, B). The coronal Cobb angle and GK were 87° (C) and 100° (D) preoperatively. The patients underwent posterior T_{12} VCR and fusion with traditional pedicle screw instrumentations from T_4 to L_5 and satellite rod from T_7 to L_2 . The coronal Cobb angle and the GK were corrected to 20° (E) and 26° (F), respectively. At 2 years' follow-up, no significant correction loss was found (G-J).

TABLE 2 Comparison of Scoliosis Research Society (SRS)-22 scoring questionnaire preoperatively and at last follow-up

SRS-22	Pre-op	Last follow-up	Pre-op vs last follow-up
Pain	3.2 ± 0.8	4.6 ± 0.5	P = 0.039*
Self-image	2.6 ± 0.8	4.3 ± 0.6	P = 0.008*
Function/Activity	4.2 ± 0.6	4.4 ± 0.6	P = 0.441
Mental health	4.0 ± 1.0	4.4 ± 0.5	P = 0.061
Management satisfaction	—	4.6 ± 0.6	—

* Statistically significant if $P < 0.05$.; SRS-22, the Scoliosis Research Society-22 questionnaire.

revision surgery. Postoperative computed tomography (CT) scan showed that there was one pedicle screw breached into upper endplate and another one malpositioned laterally, but no neurologic injury or implant-related symptom was found. No screw loosening or breakage was observed.

Discussion

This study evaluated the clinical and radiological outcome of duet screw-based satellite rod technique in the treatment of severe spinal deformity. The results showed that this novel application had significant three-column correction with satisfactory SRS-22 score and less complications. During the 2-year follow-up, the coronal and sagittal balance were well-maintained.

In severe kyphoscoliosis patients undergoing 3CO, the osteotomy level and adjacent segments suffered from high mechanical stress^{14,15}. The deficient bone stock due to wide laminectomy and unstable bony fusion in the short term after surgery increases the risks of implant-related complications. Based on a systematic review, the incidence of implant-related complication was up to 6%¹⁶. As reported by Yang *et al.*, symptomatic rod fracture occurred in 15.8% of adult patients undergoing PSO¹⁷. Therefore, it is necessary to reinforce the osteotomy area to reduce the risk of implant failure. In recent years, a variety of methods have been introduced including anterior support with titanium mesh and dual rods with maximal diameter^{18,19}. However, anterior mesh cage is difficult to insert and mesh subsidence is unlikely to avoid. The use of dual rods with larger diameter or cobalt chromium rods were considered to be a preferred strategy to lower the risk of rod breakage; however, larger diameter and cobalt chromium rods increase the cost greatly while still not completely decreasing the devastating complications. As for higher implant density, it will increase patients' financial burden but still cannot completely avoid the occurrence of rod breakage^{20,21}.

In a biomechanical study, satellite rod technique has proved to maintain stability in lateral bending and significantly improve construct stability in flexion and extension over a conventional cross-linked two-rod technique²². Our center firstly applied satellite rod technique in adult patients with severe spinal scoliosis who underwent 3CO, which employed the duet screw instead of pedicle screw in the upper and lower segments with simple maneuver. It is worth

pointing out that many of the satellite rods that we used were collected from residual parts which were cut off from longitudinal rods. In addition, there was no need to increase the pedicle screw density. Therefore, this technique can greatly reduce economic burden for patients.

In this study, the mean operation time was 3.5 ± 1.1 h and mean estimated blood loss was 1587 ± 545 mL. Previous studies reported that the three-column osteotomy surgery for severe spinal deformity was 4.3–7.9 h, and intraoperative blood loss was 1277–10,975 mL^{23–25}. This indicated that, despite an extra one or two short rods being eventually inserted, satellite rod technique did not significantly increase the intraoperative blood loss and operation time. We therefore believed that the satellite rod technique was easy to handle and, more importantly, could avoid the extra and repetitive removal of temporary rods during osteotomy. Moreover, it is reported that the correction rate of Cobb angle after 3CO in severe spinal deformity ranged from 37.2% to 67%, while the correction rate of kyphosis was 46.6%–71%^{4,26,27}. In our results, mean correction rate of Cobb angle was $65.2\% \pm 21.8\%$ and correction rate of GK was $66.0\% \pm 17.9\%$. During the longitudinal follow-up, there was no significant correction loss. Therefore, the satellite rod used in patients with severe kyphoscoliosis undergoing 3CO could attain satisfactory deformity correction, which could be well maintained during follow-up.

The outcome of SRS-22 showed that the scores for pain and self-image improved significantly at the last follow-up ($P < 0.05$); function/activity and mental health scores also improved at final follow-up, though the difference was not statistically significant ($P > 0.05$). These results indicated that satellite rod-duet screw technique can not only achieve a favorable correction on radiographs, but also increase patients' quality of life, thus yielding a good clinical outcome.

The previous literature reported that the overall complication rate of 3CO in severe spinal deformity was up to 14.1%–34.2%^{9,25,27,28}. Papadopoulos *et al.* analyzed 45 patients with severe and rigid scoliosis who had complications after VCR surgery and found that 10 cases had MEP change of which one had complete spinal cord injury and two had nerve root injury. In our study, one patient had rod breakage and needed revision surgery and two pedicle screws were malpositioned. No obvious decompensation and correction loss were found during the follow-up. Therefore, this

technique can avoid local minor motion when performing three-column osteotomy for severe deformity. In addition, there is no need to remove the satellite rod after completing reduction, which not only reduces the risk of neural injury and reduction loss during surgery, but also improves the safety and reliability of the surgery.

This study suggested that the utilization of satellite rods combined with duet screws around three-column osteotomy segments in severe deformity cases yielded a favorable correction outcome; however, several limitations remained. The relatively small sample size may result in selection bias,

and the heterogeneity of pathogenesis may influence the evaluation of radiological and clinical results. Therefore, long-term multicenter outcome study is necessary to further validate the clinical outcome and to investigate the complication rate and the risk of revision surgery.

In conclusion, this study proposed the utilization of satellite rods around osteotomy segments in severe kyphoscoliosis, which met the requirement of solid fixation and played a role in dispersing the stress of the longitudinal rods to achieve a good clinical outcome. During the follow-up, the coronal and sagittal balance could be well-maintained.

References

- Shimode M, Kojima T, Sowa K. Spinal wedge osteotomy by a single posterior approach for correction of severe and rigid kyphosis or kyphoscoliosis. *Spine (Phila Pa 1976)*, 2002, 27: 2260–2267.
- Kim KT, Lee S, Suk KS, Lee JH, Jeong BO. Outcome of pedicle subtraction osteotomies for fixed sagittal imbalance of multiple etiologies: a retrospective review of 140 patients. *Spine (Phila Pa 1976)*, 2012, 37: 1667–1675.
- Rajasekaran S, Vijay K, Shetty AP. Single-stage closing–opening wedge osteotomy of spine to correct severe post-tubercular kyphotic deformities of the spine: a 3-year follow-up of 17 patients. *Eur Spine J*, 2010, 19: 583–592.
- Hamzaoglu A, Alanay A, Ozturk C, Sarier M, Karadereler S, Ganiyusufoglu K. Posterior vertebral column resection in severe spinal deformities: a total of 102 cases. *Spine (Phila Pa 1976)*, 2011, 36: 340–344.
- Suk S, Chung E, Lee SM, Lee J, Kim S, Kim J. Posterior vertebral column resection in fixed lumbosacral deformity. *Spine (Phila Pa 1976)*, 2005, 30: 703–710.
- Kim YJ, Bridwell KH, Lenke LG, Rhim S, Cheh G. Pseudarthrosis in long adult spinal deformity instrumentation and fusion to the sacrum: prevalence and risk factor analysis of 144 cases. *Spine (Phila Pa 1976)*, 2006, 31: 2329–2336.
- Denis F, Sun EC, Winter RB. Incidence and risk factors for proximal and distal junctional kyphosis following surgical treatment for Scheuermann kyphosis: minimum five-year follow-up. *Spine (Phila Pa 1976)*, 2009, 34: 729–734.
- Ibrahimi DM, Smith JS, Klineberg EO, et al. Prospective multicenter assessment of risk factors for rod fracture following surgery for adult spinal deformity. *J Neurosurg Spine*, 2014, 21: 994–1003.
- Suk S, Kim JH, Kim WJ, Lee SM, Chung E, Nah K. Posterior vertebral column resection for severe spinal deformities. *Spine (Phila Pa 1976)*, 2002, 27: 2374–2382.
- Shen F, Harper M, Foster WC, Marks I, Arlet V. A novel “four-rod technique” for lumbo-pelvic reconstruction: theory and technical considerations. *Spine (Phila Pa 1976)*, 2006, 31: 1395–1401.
- Luca A, Ottardi C, Sasso M, et al. Instrumentation failure following pedicle subtraction osteotomy: the role of rod material, diameter, and multi-rod constructs. *Eur Spine J*, 2017, 26: 764–770.
- Hyun S, Lenke LG, Kim SY, Koester LA, Blanke K. Comparison of standard 2-rod constructs to multiple-rod constructs for fixation across 3-column spinal osteotomies. *Spine (Phila Pa 1976)*, 2014, 39: 1899–1904.
- Cahill PJ, Wang W, Asghar J, et al. The use of a transition rod may prevent proximal junctional kyphosis in the thoracic spine after scoliosis surgery: a finite element analysis. *Spine (Phila Pa 1976)*, 2012, 37: 687–695.
- Liu Z, Qiu Y, Shi BL. Using satellite rod around the osteotomy area in patients with severe spinal deformity undergoing three- column osteotomy. *Chin J Orthop*, 2015, 35: 349–356.
- Yang BP, Ondra SL, Chen LA, Jung HS, Koski TR, Salehi SA. Clinical and radiographic outcomes of thoracic and lumbar pedicle subtraction osteotomy for fixed sagittal imbalance. *J Neurosurg Spine*, 2006, 5: 9–17.
- La Barbera L, Braydabruno M, Liebsch C, et al. Biomechanical advantages of supplemental accessory and satellite rods with and without interbody cages implantation for the stabilization of pedicle subtraction osteotomy. *Eur Spine J*, 2018, 27: 2357–2366.
- Yang C, Zheng Z, Liu H, Wang J, Kim YJ, Cho S. Posterior vertebral column resection in spinal deformity: a systematic review. *Eur Spine J*, 2016, 25: 2368–2375.
- Smith JS, Shaffrey CI, Ames CP, et al. Assessment of symptomatic rod fracture after posterior instrumented fusion for adult spinal deformity. *Neurosurgery*, 2012, 71: 862–868.
- Lenke LG, Sides BA, Koester LA, Hensley M, Blanke KM. Vertebral column resection for the treatment of severe spinal deformity. *Clin Orthop Relat Res*, 2010, 468: 687–699.
- Ouellet JA, Johnson CE. Effect of grafting technique on the maintenance of coronal and sagittal correction in anterior treatment of scoliosis. *Spine (Phila Pa 1976)*, 2002, 27: 2129–2135.
- Delikaris A, Wang X, Boyer L, Larson AN, Ledonio CGT, Aubin CE. Implant density at the apex is more important than overall implant density for 3D correction in thoracic adolescent idiopathic scoliosis using rod derotation and en bloc vertebral derotation technique. *Spine (Phila Pa 1976)*, 2018;43(11): E639–E647.
- Machthong J, Ibrahim S, Parent S, Labelle H. Defining the number and type of fixation anchors for optimal main curve correction in posterior surgery for adolescent idiopathic scoliosis. *Spine J*, 2017, 17: 663–670.
- Kelly BP, Shen FH, Schwab JS, Arlet V, Diangelo DJ. Biomechanical testing of a novel four-rod technique for lumbo-pelvic reconstruction. *Spine (Phila Pa 1976)*, 2008, 33: 400–406.
- Auerbach JD, Lenke LG, Bridwell KH, et al. Major complications and comparison between 3-column osteotomy techniques in 105 consecutive spinal deformity procedures. *Spine (Phila Pa 1976)*, 2012, 37: 1198–1210.
- Ikenaga M, Shikata J, Takemoto M, Tanaka C. Clinical outcomes and complications after pedicle subtraction osteotomy for correction of thoracolumbar kyphosis. *J Neurosurg Spine*, 2007, 6: 330–336.
- Qian BP, Wang XH, Qiu Y, et al. The influence of closing-opening wedge osteotomy on sagittal balance in thoracolumbar kyphosis secondary to ankylosing spondylitis: a comparison with closing wedge osteotomy. *Spine (Phila Pa 1976)*, 2012, 37: 1415–1423.
- O’neill KR, Lenke LG, Bridwell KH, et al. Clinical and radiographic outcomes after 3-column osteotomies with 5-year follow-up. *Spine (Phila Pa 1976)*, 2014, 39: 424–432.
- Lenke LG, Newton PO, Sucato DJ, et al. Complications after 147 consecutive vertebral column resections for severe pediatric spinal deformity: a multicenter analysis. *Spine (Phila Pa 1976)*, 2013, 38: 119–132.