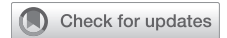



Since January 2020 Elsevier has created a COVID-19 resource centre with free information in English and Mandarin on the novel coronavirus COVID-19. The COVID-19 resource centre is hosted on Elsevier Connect, the company's public news and information website.

Elsevier hereby grants permission to make all its COVID-19-related research that is available on the COVID-19 resource centre - including this research content - immediately available in PubMed Central and other publicly funded repositories, such as the WHO COVID database with rights for unrestricted research re-use and analyses in any form or by any means with acknowledgement of the original source. These permissions are granted for free by Elsevier for as long as the COVID-19 resource centre remains active.

A Man With Malaise, Myalgia, and Rapidly Progressive Interstitial Lung Disease



Marissa O'Callaghan, MD; Leah Rooney, MD; Jehangir Khan, MD; Sinead Flanagan, MD; Michael P. Keane, MD; Aurelie Fabre, MD, PhD; Lorraine O'Neill, MD; and Cormac McCarthy, MD, PhD

CASE PRESENTATION: A 45-year-old man sought treatment at the ED during the third wave of the COVID-19 pandemic with a month-long history of fatigue, cough, myalgia, and hand stiffness. He did not report dyspnea. He had no past medical history and previously was fit and active, working as a farmer. He was a lifelong nonsmoker and had no family history of lung disease.

CHEST 2022; 162(3):e111-e116

Physical Examination Findings

On physical examination, his peripheral oxygen saturation was 96% on room air, respiratory rate was 18 breaths/min, and he was febrile with a temperature of 38.7 °C (101.6 °F). He was hemodynamically stable with a BP of 129 mm Hg/82 mm Hg and heart rate of 80 beats/min. No evidence was found of finger clubbing, synovitis, or muscle weakness. On auscultation of the chest, reduced air entry at the lung bases was observed.

Diagnostic Studies

Initial blood testing revealed a WBC count of $7.6 \times 10^9/L$, and C-reactive protein level was elevated at 50 mg/L (normal range, 0-5.0 mg/L). Renal profile findings were within normal limits. N-terminal pro-brain natriuretic peptide level was 365 pg/mL (normal range, 0-121 pg/mL). Bloods culture and urinary *Legionella* and pneumococcal antigen findings were negative. Sputum culture grew *Candida* species. SARS-CoV-2 polymerase chain reaction results were negative on three separate occasions. Chest radiography revealed diffuse infiltrates throughout both lungs (Fig 1), and CT scan pulmonary angiography revealed diffuse bilateral ground-glass

changes with reticulonodular opacifications in the lower lobes (Fig 2). Bronchoscopy and BAL cell differential demonstrated 75% macrophages and 11% lymphocytes. Microscopy and culture results for bacteria, mycobacteria, and fungi were negative on BAL.

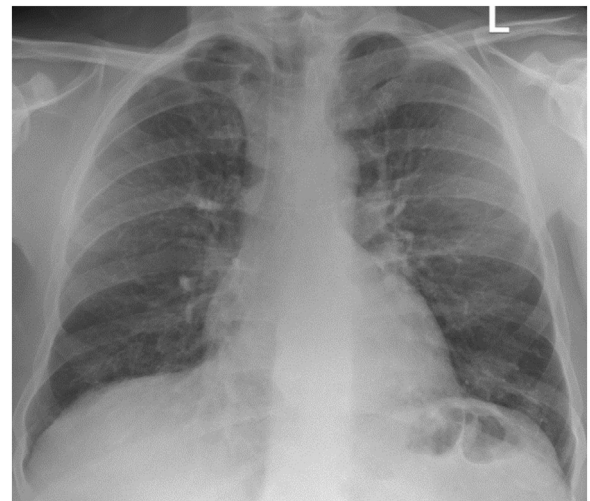


Figure 1 – Posterior anterior chest radiograph demonstrating diffuse alveolar infiltrates bilaterally.

AFFILIATIONS: From the Department of Respiratory Medicine (M. O., J. K., M. P. K., and C. M.), the Department of Rheumatology (L. R. and L. O.), the Department of Histopathology (S. F. and A. F.), St. Vincent's University Hospital, and the Department of Medicine (M. O., M. P. K., and C. M.), University College Dublin, Dublin, Ireland.

CORRESPONDENCE TO: Cormac McCarthy, MD, PhD; email: mccarthy@ucd.ie

Copyright © 2022 American College of Chest Physicians. Published by Elsevier Inc. All rights reserved.

DOI: <https://doi.org/10.1016/j.chest.2022.03.052>

Empirical broad-spectrum antimicrobials were commenced and corticosteroids were added later to cover for hypersensitivity pneumonitis, given his farming background. This was added after the BAL was performed, while results were pending. Despite this, he demonstrated progressive hypoxemia, necessitating invasive mechanical ventilation on day 8 of admission. The rapidly progressive nature of this lung disease in the absence of identifiable infection raised suspicion for an inflammatory cause.

Autoantibody screening revealed positive speckled antinuclear antibody findings with a titer of 1:200, and

anti-Ro antibodies were elevated at 131 U/mL (normal range, 0.0-6.9 U/mL). Antineutrophil cytoplasmic antibody, C3/C4, and immunoglobulin levels were normal. Creatine kinase level was elevated mildly at 686 U/L (normal range, 25-200 U/L) on admission, but normalized during his stay. He had no prior history of sicca or photosensitivity and no other features suggestive of systemic lupus erythematosus or Sjögren's syndrome. Re-examination of his skin and joints identified subtle changes on his hands, with erythematous lesions over his interphalangeal joints, periungual erythema, and dry fissured skin suggestive of mechanic's hands (Fig 3).

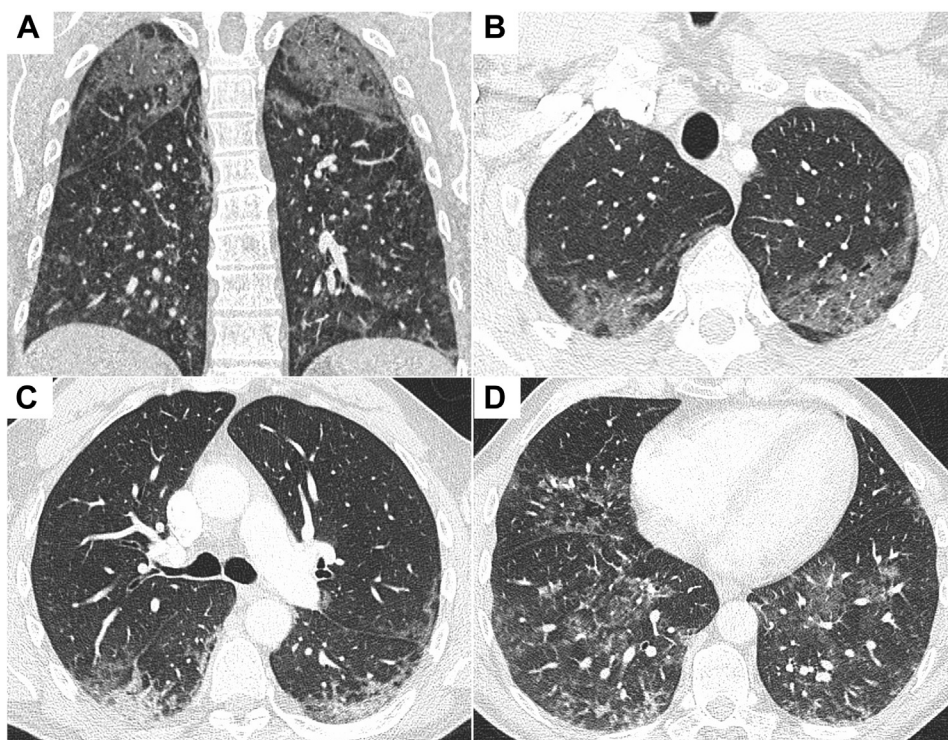


Figure 2 – A-D, CT pulmonary angiograms demonstrating diffuse bilateral ground-glass change with reticular nodular opacification in the lower lobes: coronal image (A) and axial slices from lung apices to bases (B-D).

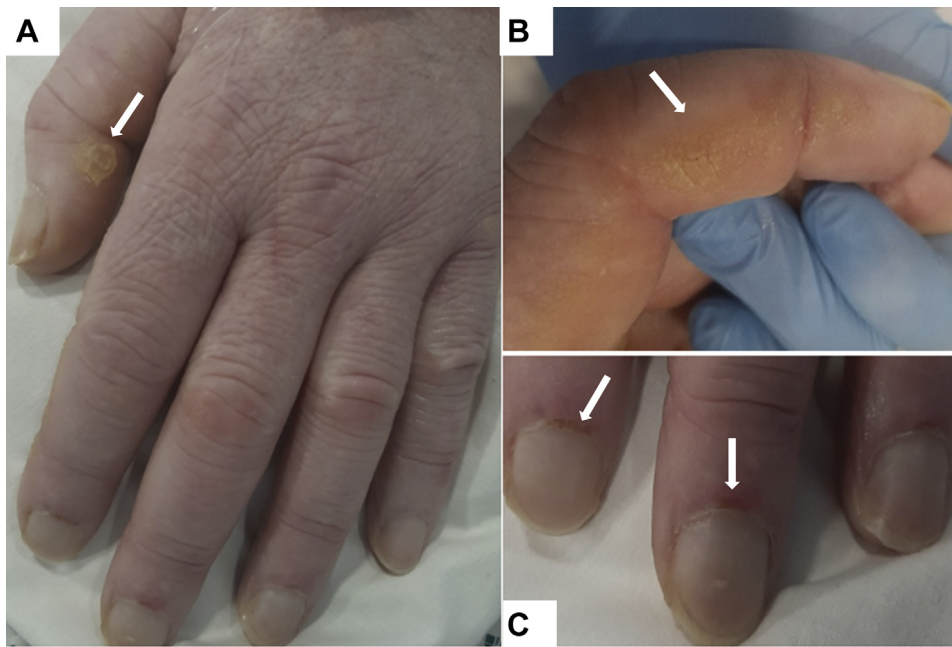


Figure 3 – A-C, Photographs showing hyperkeratosis and skin cracking (A, B) and periungual erythema and dilated nail-fold capillaries (C).

What is the diagnosis?

Diagnosis: Interstitial lung disease associated with anti-melanoma differentiation-associated protein 5 (MDA5) dermatomyositis

Discussion

Dermatomyositis is a heterogeneous disease that has many subtypes with varied clinical presentations and complications. The subtypes are identified by the presence of a myositis-specific antibody as well as their clinical presentation. Anti-MDA5 dermatomyositis is a recently recognized subtype that often presents with rapidly progressive interstitial lung disease. Without early recognition and aggressive immunosuppressive therapy, anti-MDA5 dermatomyositis has a poor prognosis and high mortality rate.

The anti-MDA5 antibody was identified first in 2005 in a Japanese cohort and initially was referred to as clinically amyopathic dermatomyositis 140 antibody. It was identified only in patients with clinically amyopathic dermatomyositis, encompassing those with amyopathic disease and hypomyopathic disease (patients with subclinical evidence of myositis). In this cohort, the presence of the clinically amyopathic dermatomyositis 140 antibody was associated with significantly more rapidly progressive interstitial lung disease compared with that in patients without the antibody. This antibody targets *MDA-5*; therefore, it is referred to as anti-MDA5. *MDA5* is a protein involved in the innate immune system. It recognizes double-stranded RNA viruses,

inducing a type 1 interferon response on recognition. Anti-MDA5 antibodies are dermatomyositis specific and help to differentiate from other connective tissue disorders or inflammatory myopathies, specifically antisynthetase syndrome, where the pathogenic antibody is directed against a transfer RNA synthetase (Table 1). Titers of anti-MDA5 antibody can correlate with disease activity and can be used to monitor response to treatment.

Anti-MDA5 dermatomyositis accounts for 20% to 40% of patients with dermatomyositis in Japan and 7% to 10% of patients with dermatomyositis in Europe. The exact pathogenesis of the disease is unknown; it likely is triggered by infectious or environmental factors in a genetically susceptible individual.

Anti-MDA5 dermatomyositis is associated with rapidly progressive interstitial lung disease and cutaneous disease, with little to no muscular involvement (amyopathic). Fevers and arthralgia or arthritis also are common features at presentation. Often, as in this patient, the extrapulmonary features of this disease are mild. The typical dermatomyositis skin manifestations of Gottron’s papules, mechanic’s hands, heliotrope rash, and shawl sign can occur. Features suggestive of a cutaneous vasculopathy—skin ulcers and palmar papules—also associated with anti-MDA5 dermatomyositis, and not with other dermatomyositis subtypes.

Anti-MDA5 dermatomyositis has a high mortality rate because of acute respiratory failure resulting from

TABLE 1] Clinical Features of Myositis-Related Interstitial Lung Diseases

Variable	Anti-MDA-5 DM	Anti-synthetase Syndrome	Other Myositis-Related ILD
Myositis-specific antibodies	Anti-MDA-5	Anti Jo-1, anti-PL7, anti-PL12, anti-OJ, anti-EJ, anti-KS, anti-Ha, and anti-Zo	Anti-PM-Scl, anti-R052, and anti-Ku
Muscle disease	Typically amyopathic or hypomyopathic	Myositis in 50%-90%; typical presentation with proximal muscle weakness	Myositis in 37%-49%; mixed pattern including proximal myopathy and myalgia
Skin disease	Ulceration and palmar papules specific to MDA-5; other DM skin manifestations: mechanic’s hands, heliotrope rash, Gottron’s papules, shawl sign	Mechanic’s hands, heliotrope rash, Gottron’s papules, shawl sign	Mechanic’s hands, subcutaneous edema, swollen hands, calcinosis, sclerodactyly, telangiectasia, malar rash, photosensitivity
ILD	Typically rapidly progressive	Typically chronic or subacute	Mixed
Frequency of ILD	50%-90%	66%-90%	25%-61%
Other clinical features	Arthritis (60%), fever (60%)	Arthritis (60%), fever (25%), Raynaud’s phenomenon	Arthritis (77%-94%), Raynaud’s phenomenon (53%-78%)

DM = dermatomyositis; ILD = interstitial lung disease; MDA-5 = melanoma differentiation-associated protein 5.

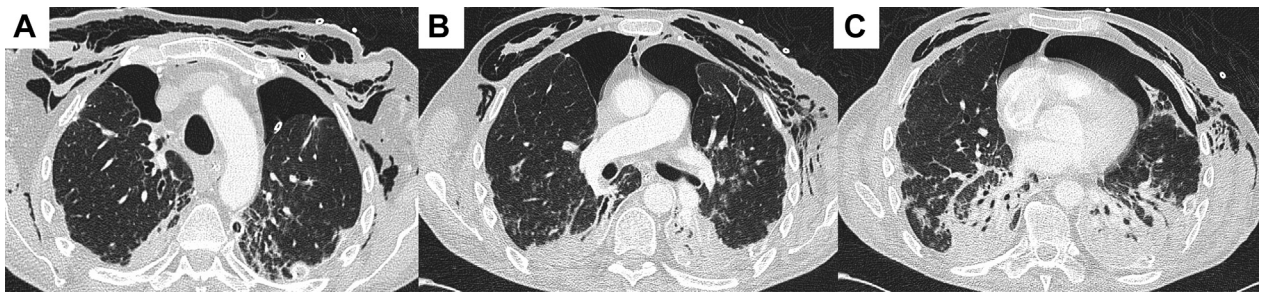


Figure 4 – A-C, Axial slices from a chest CT scan demonstrating progression of bilateral lower lobe consolidation and bilateral pneumothoraces with extensive subcutaneous emphysema throughout the superficial soft tissues of the chest extending into the mediastinum.

rapidly progressive interstitial lung disease. A retrospective French study looked at outcomes among patients with anti-MDA5 dermatomyositis and acute respiratory failure requiring ICU care between 2010 and 2017. Most of the patients had severe ARDS (PaO_2 to FiO_2 ratio of ≤ 100 mm Hg with positive end-expiratory pressure of ≥ 5 mm H_2O) and all patients ($n = 19$) received corticosteroids and other immunosuppressants (84% cyclophosphamide, 32% rituximab, 11% tacrolimus, 11% cyclosporine, and 11% basiliximab). ICU mortality was 85%. Anti-Ro positivity, present in 60% of patients with anti-MDA5 dermatomyositis, and pneumomediastinum, reported

in 15% of patients, both are associated with a poor prognosis.

Early treatment with aggressive combination immunosuppressant therapy is recommended. A multicenter study on combination immunosuppressant therapy in patients with anti-MDA5 dermatomyositis-associated interstitial lung disease showed a significantly higher 6-month survival compared with a historic group of patients who received step-up treatment (89% vs 33%). Combination treatment included high-dose corticosteroids, IV cyclophosphamide, and tacrolimus vs the step-up treatment of initial corticosteroid treatment with a later addition of other

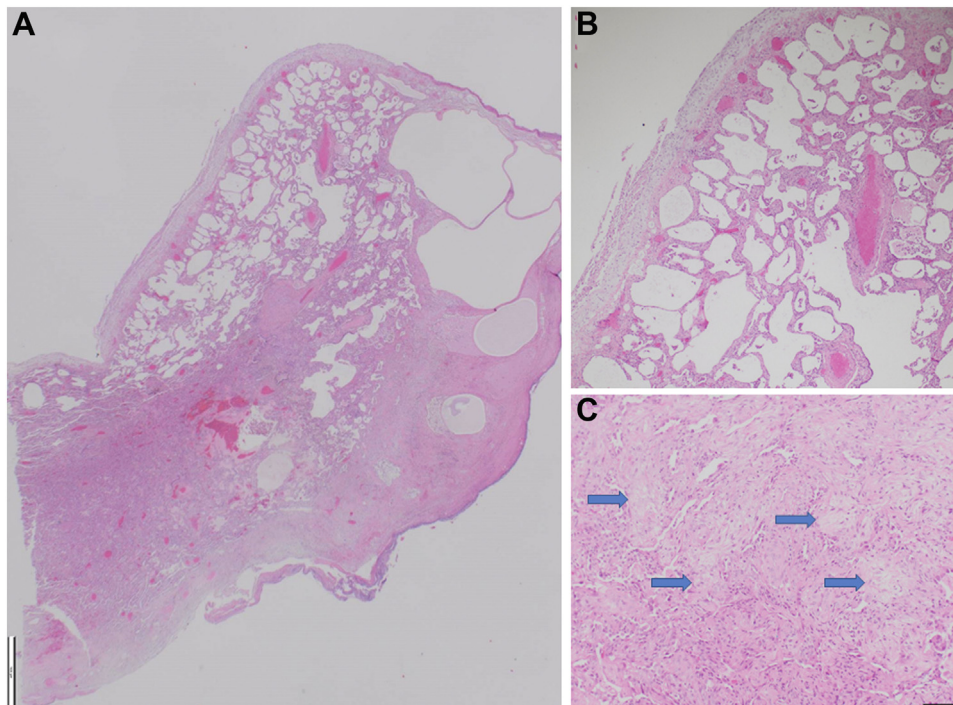


Figure 5 – A-C, Photomicrographs of video-assisted thoracoscopic surgery lung biopsy samples showing: (A) cystically dilated subpleural alveoli and rigid-appearing alveolar walls ($\times 125$ magnification; scale bar, 1,000 μm), (B) diffuse regular interstitial expansion of alveolar walls by fibrosis consistent with a nonspecific interstitial pneumonia pattern ($\times 100$ magnification; scale bar, 100 μm), and (C) focal organizing pneumonia with endoalveolar buds (blue arrows) also present ($\times 100$ magnification; scale bar, 100 μm).

immunosuppressive agents. Cyclophosphamide typically is added in cases of life-threatening or refractory disease. Other treatments described in the literature include IV immunoglobulin and rituximab. IV immunoglobulin has been shown to be an effective treatment in idiopathic inflammatory myopathies when used at high doses, and rituximab is an effective treatment in dermatomyositis for lung, muscle, and skin disease.

Clinical Course

The subtle cutaneous features in keeping with dermatomyositis and anti-Ro positivity prompted a rheumatology opinion and extended myositis panel request. This confirmed the presence of anti-MDA5 antibodies. These findings are characteristic for anti-MDA5 dermatomyositis, which may have a fatal course. He was given IV immunoglobulin 2 g/kg over 48 h, pulsed with IV methylprednisolone 750 mg for 3 days, and then given rituximab and cyclophosphamide therapy in conjunction with a corticosteroid wean.

Despite treatment, he remained hypoxic and ventilator dependent. After resuscitation subsequent to a hypoxia-induced bradycardic arrest, chest radiography demonstrated a left-sided pneumothorax. A synchronous right-sided pneumothorax developed 1 week later with pneumomediastinum (Fig 4). He later underwent video-assisted thoracoscopic surgery pleurodesis for a persistent air leak on the left side. A lung biopsy sample was obtained at this time that revealed histopathologic findings consistent with nonspecific interstitial pneumonia and diffuse alveolar damage (Fig 5). Ventilatory wean was slow despite tracheostomy, and he experienced multiple episodes of ventilator-associated pneumonia. Unfortunately, after a 12-week stay in the ICU, this patient died after an episode of ventilator-associated pneumonia.

Clinical Pearls

1. Dermatomyositis subtypes are identified by skin and muscle findings, presence and progression of associated lung disease, and the presence of a myositis-specific antibodies (Table 1).
2. Anti-MDA5 dermatomyositis is associated with rapidly progressive interstitial lung disease and cutaneous disease with little to no muscular involvement.

3. Anti-MDA5 dermatomyositis has a high mortality rate because of acute respiratory failure resulting from rapidly progressive interstitial lung disease.
4. Concurrent anti-Ro antibody positivity and the complication of pneumomediastinum both are associated individually with poor survival in anti-MDA5 dermatomyositis.
5. Treatment should be initiated early with aggressive immunosuppression and should be combined with respiratory support.

Acknowledgments

Financial/nonfinancial disclosures: None declared.

Other contributions: CHEST worked with the authors to ensure that the Journal policies on patient consent to report information were met.

Suggested Readings

Sato S, Hirakata M, Kuwana M, et al. Autoantibodies to a 140-kd polypeptide, CADM-140, in Japanese patients with clinically amyopathic dermatomyositis. *Arthritis Rheum.* 2005;52(5):1571-1576.

Fiorentino D, Chung L, Zwerner J, Rosen A, Casciola-Rosen L. The mucocutaneous and systemic phenotype of dermatomyositis patients with antibodies to MDA5 (CADM-140): a retrospective study. *J Am Acad Dermatol.* 2011;65(1):25-34.

Szodoray P, Hajas A, Kardos L, et al. Distinct phenotypes in mixed connective tissue disease: subgroups and survival. *Lupus.* 2012;21:1412-1422.

Sato S, Kuwana M, Fujita T, Suzuki Y. Anti-CADM-140/MDA5 autoantibody titer correlates with disease activity and predicts disease outcome in patients with dermatomyositis and rapidly progressive interstitial lung disease. *Mod Rheumatol.* 2013;23(3):496-502.

Ceribelli A, Fredi M, Taraborelli M, et al. Prevalence and clinical significance of anti-MDA5 antibodies in European patients with polymyositis/dermatomyositis. *Clin Exp Rheumatol.* 2014;32(6):891-897.

Labrador-Horrillo M, Martinez MA, Selva-O'Callaghan A, et al. Anti-MDA5 antibodies in a large Mediterranean population of adults with dermatomyositis. *J Immunol Res.* 2014;2014:290797.

Kurtzman DJB, Vleugels RA. Anti-melanoma differentiation-associated gene 5 (MDA5) dermatomyositis: a concise review with an emphasis on distinctive clinical features. *J Am Acad Dermatol.* 2018;78(4):776-785.

Vuillard C, Pineton de Chambrun M, de Prost N, et al. Clinical features and outcome of patients with acute respiratory failure revealing anti-synthetase or anti-MDA-5 dermato-pulmonary syndrome: a French multicenter retrospective study. *Ann Intensive Care.* 2018;8(1):87.

Tsuji H, Nakashima R, Hosono Y, et al. Multicenter prospective study of the efficacy and safety of combined immunosuppressive therapy with high-dose glucocorticoid, tacrolimus, and cyclophosphamide in interstitial lung diseases accompanied by anti-melanoma differentiation-associated gene 5-positive dermatomyositis. *Arthritis Rheumatol.* 2020;72(3):488-498.

Zhou M, Ye Y, Yan N, Lian X, Bao C, Guo Q. Noninvasive positive pressure ventilator deteriorates the outcome of pneumomediastinum in anti-MDA5 antibody-positive clinically amyopathic dermatomyositis. *Clin Rheumatol.* 2020;39(6):1919-1927.

Mehta AA, Paul T, Cb M, Haridas N. Anti-MDA5 antibody-positive dermatomyositis with rapidly progressive interstitial lung disease: report of two cases. *BMJ Case Rep.* 2021;14(4).