

Anisakis Nematodes in Fish and Shellfish- from infection to allergies

Ibukun E. Aibinu^a, Peter M. Smooker^a, Andreas L. Lopata^{b,c,d,*}

^a School of Science, Discipline of Biosciences and Food Technology, Royal Melbourne Institute of Technology (RMIT) University, Bundoora, Victoria, Australia

^b Molecular Allergy Research Laboratory, Department of Molecular and Cell Biology, James Cook University, Townsville, Queensland, Australia

^c Australian Institute of Tropical Health and Medicine, James Cook University, Townsville, Queensland, Australia

^d College of Public Health, Medical and Veterinary Sciences, James Cook University, Townsville, Queensland, Australia

ARTICLE INFO

Keywords:

Anisakis
Fish hosts
Crustacean hosts
Shellfish
Anisakiasis
Anisakis allergy
Cross-reactivity
Zoonotic
Food-borne parasite

ABSTRACT

Anisakidosis is a zoonotic parasitosis induced by members of the family Anisakidae. The anisakid genera includes *Anisakis*, *Pseudoterranova*, *Hysterothylacium* and *Contracaecum*. The final definitive hosts of these nematodes are marine mammals with a complex life cycle. These nematode parasites use different crustaceans and fish species as intermediate or paratenic hosts and humans are accidental hosts. Human anisakiasis, the infections caused by members of the genus *Anisakis*, occurs, when seafoods, particularly fish, contaminated with the infective stage (third stage larvae [L3]) of this parasite, are consumed. Pseudoterranovosis, on the other hand is induced by members of the genus *Pseudoterranova*. These two genera of anisakids have been implicated in human disease globally. There is a rise in reports of gastro-intestinal infections accompanied by allergic reactions caused by *Anisakis simplex* and *Anisakis pegreffii*. This review provides an update on current knowledge on *Anisakis* as a food-borne parasite with special focus on the increasingly reported diversity of fish and crustacean hosts, allergens and immunological cross-reactivity with invertebrate proteins rendering this parasite a significant public health issue.

1. Introduction

The World Health Organization (WHO) (World Health Organization, 2012) estimates approximately 56 million cases of parasite infections associated with the consumption of fish products. Among the parasites implicated, are the group of anisakids, known to be capable of inducing severe pathologies in humans and widely distributed geographically across all continents (Pampiglione et al., 2002).

Anisakids are parasitic nematodes belonging to the Phylum Nematelminthes, Class Nematoda, Ascarida order, suborder Ascaridina, superfamily Ascaridoidea, Anisakidae family and subfamily Anisakinae. This family includes the genera *Anisakis*, *Pseudoterranova*, *Contracaecum* and *Hysterothylacium* (Smith and Wootten, 1978). However, three species of the genus *Anisakis* are reported to be the causative agent of infections in humans: *A. simplex* sensu stricto, *Anisakis pegreffii* and *Anisakis physeteris* (Mattiucci and Nascetti, 2008). For the purpose of this review, the focus will be on *A. simplex* and *A. pegreffii*.

Anisakiasis is the zoonotic disease triggered by the third stage larvae of nematodes, *Anisakis* (Nieuwenhuizen and Lopata, 2013). This parasite habitually parasitises adult marine mammals. Intermediate and/or paratenic hosts of the larvae are crustaceans, cephalopods and fish

(Nieuwenhuizen and Lopata, 2013). Humans are however accidentally infected when hosts are ingested either as raw or inadequately cooked or treated fish/shellfish meals. Hence, the infection has been directly linked to eating habits (Pampiglione et al., 2002). Infected dishes of raw fish such as sushi and sashimi commonly found in Japan's national dishes as well as the culinary tradition of consumption of marinated or raw fish in European countries such as Italy are a significant source of the infection (Ivanovic et al., 2015; Yorimitsu et al., 2013). Globalization of such cuisine improved public health diagnosis (better diagnostic tool development) and greater awareness of anisakiasis infection has resulted in increase in the frequency of reported anisakiasis in most continents (Ivanovic et al., 2015).

Symptoms of acute anisakiasis include severe abdominal pain, nausea, and vomiting. Some of these symptoms closely mimic peptic ulcer, appendicitis, or peritonitis with the most concerning presentation being allergic sensitisation, which is usually serious and range from urticaria to anaphylactic shock (Villazanakretzer et al., 2016). The L3 larvae of the genus *Anisakis* have been found in several economically important fish species. However, the prevalence of *Anisakis* in the fish host has been reported to vary between different geographical fishing grounds and seasons in the same fish host species. Serraca and

* Corresponding author. College of Public Health, Medical and Veterinary Sciences Room 109A, DB47, Pharmacy and Medical Research, James Cook University, Angus Smith Drive, Douglas, QLD, 4811, Australia.

E-mail address: andreas.lopat@jcu.edu.au (A.L. Lopata).

<https://doi.org/10.1016/j.ijppaw.2019.04.007>

Received 4 February 2019; Received in revised form 19 April 2019; Accepted 20 April 2019

2213-2244/ © 2019 Published by Elsevier Ltd on behalf of Australian Society for Parasitology. This is an open access article under the CC BY-NC-ND license (<http://creativecommons.org/licenses/by-nc-nd/4.0/>).

colleagues (2014) attributed this to the fact that some invertebrate hosts for *Anisakis* may not be part of the habitual diet of some fish hosts in certain fishing grounds in some seasons as they may prefer other invertebrates as foods (Serracca et al., 2014). It is therefore possible for a fish host in one region to be heavily contaminated with *Anisakis* depending on the types of crustaceans eaten; and in another region, such a fish host may be free of *Anisakis*, as it may prefer other invertebrates as food than those harbouring *Anisakis* (Serracca et al., 2014). Hence, the composition of the zooplankton communities in fishing regions is a significant contributing factor to *Anisakis* parasitosis (Serracca et al., 2014). Widening our knowledge on the fish and crustacean hosts used by this parasite to propagate its life cycle, would be significant in reducing the risk for human anisakiasis via consumption of potentially infective seafoods, which are a food safety risk.

2. *Anisakis* biology and life cycle

The definitive host of anisakid, where the adult stage of the parasite is found, are cetaceans, (marine mammals such as dolphins and seals). Eggs of the parasite are passed with faeces of definitive host into the marine environment where they hatch and develop into the 2nd stage larvae of the parasite (Baird et al., 2014; Buchmann and Mehrdana, 2016). The larvae that develop from the eggs are eaten by the intermediate hosts, crustaceans (copepods, decapods, isopods, amphipods, euphausiids) and molluscs (Baird et al., 2014). It is well established that one of the most important first intermediate hosts in the *Anisakis* life cycle are the Euphausiids (Krill) (Smith and Wootton, 1978). Infected krill eaten by fish or squid become a source of the infective 3rd stage larvae of *Anisakis* for the paratenic hosts (fish or squid). The *Anisakis* larvae encyst on the intestines and other visceral organs of these hosts. The parasite does not develop further and remains at the third stage of larvae development (L3 stage) in these hosts. The life-cycle comes to a completion when infected fish/squid are eaten by marine mammals such as whales, seals and dolphins. In these definitive hosts, the larvae grow to the L4 stage and subsequently to the adult stage (Fig. 1). The nematode feeds, grows, mates and then releases eggs via the host faeces into the sea water to continue its life cycle (Pozio, 2013). As is common with parasites with complex life cycle, the morphology of *Anisakis* varies with the different stages and infected hosts. In fish, the L3 stage larvae displays a coiled shape, which when uncoiled, is about 2 cm long. Humans become accidental hosts when undercooked or raw fish and cephalopods, contaminated with the parasite are consumed.

3. Molecular identification and classification of anisakids

Classification of anisakid nematodes was previously based on some of their morphological features, which include presence, or absence of mucron at the tail tip, the length of the ventriculus position and extent of the cecum. This led to the classification of *Anisakis* into two types: *Anisakis* type 1 and II by Berland (1961). However, due to lack of precise details for species identification using morphological features, molecular tools such as sequencing of the internal transcribed spacer (ITS) region of ribosomal DNA, mitochondrial gene cytochrome oxidase subunit 2 (Cox2) and allozyme analysis, polymerase chain reaction coupled with restriction fragment length polymorphism; have been employed in species-specific identification (Iglesias et al., 2008; Shamsi et al., 2009; Umehara et al., 2006). The *cox2* gene is shown to be highly polymorphic in *Anisakis* spp. and is therefore particularly useful for identifying the parental species involved in the production of hybrids. It provides valuable information in the recognition of sibling species of *Anisakis* larvae, as independent genetic lineages (Abollo et al., 2003; Mattiucci et al., 2009; Valentini et al., 2006). It has also been established that it provides additional genetic characters useful for molecular epidemiological approach to the study of anisakiasis in human (Audicana and Kennedy, 2008).

Several studies have also shown that the first and second internal transcribed spacers (ITS-1 and ITS-2) of nuclear ribosomal DNA (rDNA) provide appropriate genetic markers for anisakid species identification irrespective of their stage of development (Jabbar et al., 2012, 2013; Shamsi et al., 2011). PCR-coupled mutation scanning of the ITS-1 and/or ITS-2, integrated with targeted sequencing (Gasser et al., 2006) and phylogenetic analysis also furnishes a powerful approach for investigating the genetic composition of populations of anisakids (Jabbar et al., 2012, 2013).

Different genera of anisakids have been described using molecular tools and classified into one of the two families: Anisakidae or Raphidascarididae (Kalay et al., 2009). Within the genus *Anisakis*, ten species and four distinct clades have been described (Mattiucci et al., 2014, 2018). *Anisakis* species identified as Clade 1 include *A. berlandi*, *A. pegreffii*, and *A. simplex* (s.s.) and are usually referred to as the *A. simplex* (s.l.) complex. *A. simplex* and *A. pegreffii* are inferred to be sister taxa (Mattiucci et al., 2014). *Anisakis* spp in clade 2 are also considered as sister taxa and have been identified as *A. ziphidarum* and *A. nascetti* (Mattiucci et al., 2014). Clade 3 *Anisakis* have been identified as *A. physeteris*, *A. paggiae* and *A. brevispiculata*. *Anisakis* sp 2, a newly

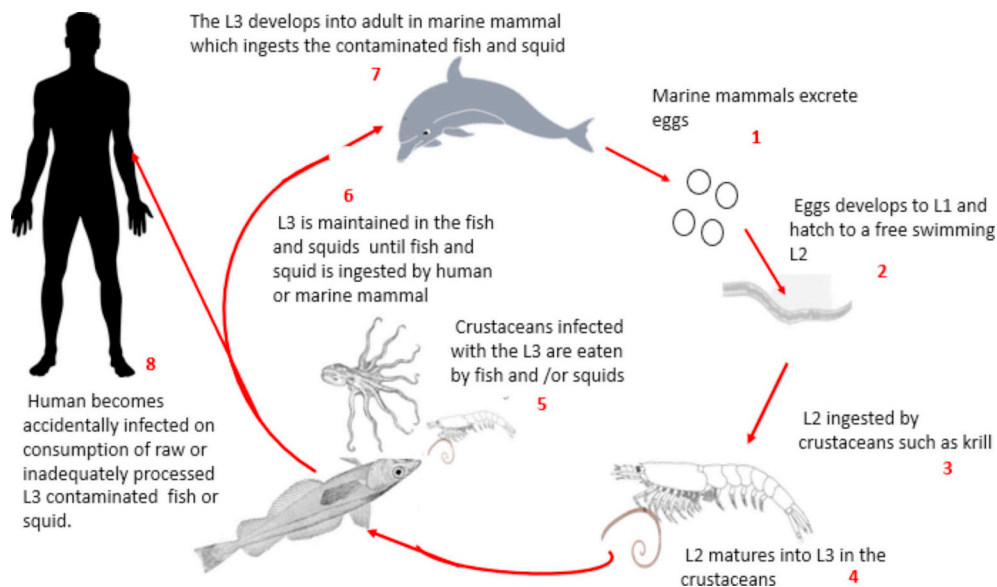


Fig. 1. *Anisakis* Life Cycle. Location of the L3 larvae may be gastric, intestinal or ectopic.

identified taxon, has been found to be closely related to *A. physeteris*, clustering closely with the clade 3 group of *Anisakis* and implying that *Anisakis* spp 2 might represent an undescribed sibling species belonging to this complex. Furthermore, *A. typica*, another species of *Anisakis*, is reported not to cluster with any of the previously identified clades. However, it was recently identified to belong to a new clade, clade four (Mattiucci et al., 2018). A recently identified *Anisakis* spp, *Anisakis* sp 1 was genetically identified in Malaysian *Nemipterus japonicus* using mitochondria DNA (mtDNA) and allozyme analysis. Though it is stated that its precise position from a phylogenetic point of view is yet to be resolved, it is however found to be genetically distinct from all previously known species of *Anisakis*, but closely related to *A. typica* from central Atlantic waters (Mattiucci et al., 2018). *A. simplex* and *A. pegreffii* have been reported as the most important zoonotic species of the genera *Anisakis* (Nieuwenhuizen and Lopata, 2013).

4. Epidemiology

The first case of anisakid disease was described in 1876 by Leuckhart (Leuckart, 1876); the disease was however only widely recognized in the 1960s, when epidemics of anisakidosis occurred in the Netherlands with the consumption of lightly salted herring (Van Thiel et al., 1960; Van Thiel, 1962). The larva was identified as *A. simplex* 3rd-stage larva. Since then, many cases of this zoonotic infection have been described in other countries such as Japan where consumption of raw fish is customary (Arizono et al., 2012; Suzuki et al., 2010). Over 20,000 cases of anisakiasis had been reported worldwide prior to 2010 (EFSA-BIOHAZ, 2010), with the highest prevalence (over 90%) from Japan (Baird et al., 2014). Infected sushi and sashimi, which are the national dishes of raw fish are the main source of human infection, with an annual report of 2000–3000 cases of anisakiasis in Japan alone (Yorimitsu et al., 2013). The worldwide adoption of different cuisine, growth of better tools for diagnosis and greater knowledge on *Anisakis* and its infection, has resulted in significantly increased reporting of anisakiasis. Other countries in which cases of anisakiasis have been reported include Korea (Sohn et al., 2015), China (Qin et al., 2013), Malaysia (Amir et al., 2016), Taiwan (Li et al., 2015), the United Kingdom (Audicana and Kennedy, 2008), Spain (Herrador et al., 2018), Italy (Mattiucci et al., 2018; Guardone et al., 2018), France (Audicana and Kennedy, 2008), Germany (Audicana and Kennedy, 2008), Denmark (Andreassen and Jorring, 1970), Norway (Jacobsen and Berland, 1969), Croatia (Mladineo et al., 2016), the United States of America (Kojima et al., 2013), Southern America (Borges et al., 2012; Eiras et al., 2018), Egypt (Audicana and Kennedy, 2008), South Africa (Audicana and Kennedy, 2008), and Australia (Shamsi and Butcher, 2011), implying anisakiasis occurrence in all continents of the globe excluding Antarctica. Recent data shown by Orphanet (Orphanet, 2016) as reported by Guardone and colleagues in a recent retrospective epidemiological study of human anisakiasis (Guardone et al., 2018), estimated a global incidence of 0.32/100,000.

A strong tradition of eating raw or undercooked fish in the form of traditional recipes such as ‘ceviche’ in South America (Eiras et al., 2018), marinated anchovies in Spain (Herrador et al., 2018), raw fish prepared according to traditional Japanese dishes, such as ‘sushi’ and ‘sashimi’ and an exponential increase in the number of restaurants serving ‘sushi’ and ‘sashimi’ globally, are risk factors for the occurrence of anisakiasis (Eiras et al., 2018). According to Shamsi and Sheorey (2018), consumption of these raw or undercooked seafoods increase the risk of infection when viable parasites are present. In a recent study of anisakiasis cases reported between 2000 and 2017 in the European union, a total of 236 cases were reported with the highest incidence in Spain, followed by Italy (Serrano-Moliner et al., 2018). Spain was identified as the country with the second highest incidence worldwide (Herrador et al., 2018). Marinated anchovies in vinegar, a dish popular in the Spanish community, was implicated as the main food vehicle of infection (Herrador et al., 2018). In Australia, it has been estimated that

1259 tonnes of raw finfish are consumed annually with 115.6 million servings per annum used for sushi and sashimi fish meal preparation (Sumner et al., 2015). As reports from certain parts of the world such as Australia on anisakiasis human infections are unexpectedly low, it is suggested that among factors implicated is the possible absence of clinical symptoms or presence of non-specific symptoms, resulting in underdiagnosis of anisakiasis (Shamsi and Sheorey, 2018). This constitutes a serious public health problem. This risk of infection could be minimised by following the recommended standard of freezing fish (FDA/CFSSAN, 2001); however, it is reported that freezing fish in some cultures, is believed to affect the taste of some of these fish meals, hence there is a reluctance to freeze fish (Iwata et al., 2015). Avoiding the consumption of raw or undercooked fish can minimise anisakiasis infection. Fish that has undergone inspection for anisakis larvae have been encouraged to be used for meal preparation in addition to freezing the fish prior to consumption (Serrano-Moliner et al., 2018).

5. Anisakiasis

Humans are an accidental host of the parasite, *Anisakis*. Infection occurs upon consumption of raw or under-processed marine fish and crustaceans contaminated with the third stage larvae (Ivanović et al., 2017). Two main mechanisms are reported to be responsible for anisakiasis: allergic reactions and direct tissue damage as a result of the penetration of the infective larvae into the target organ site (Caramello et al., 2003; Choi et al., 2009). The survival time of *Anisakis* in humans is very short and they usually become expelled or destroyed in few days or weeks (Audicana and Kennedy, 2008). However, within a few hours of ingesting this parasite through contaminated fish, the worm burrows into the human intestinal wall resulting in an acute and transient infection with symptoms such as abdominal pain, vomiting, nausea and/or diarrhea (Audicana and Kennedy, 2008). Invasion of the gut wall by the parasite sometimes results in development of eosinophilic granuloma or perforation, which causes direct tissue damage (Choi et al., 2009).

The part of the digestive tract in which *Anisakis* larvae is lodged, after consumption of raw or lightly cooked fish infected with L3 larvae and the type of *Anisakis* spp ingested, determines largely the clinical manifestation of anisakiasis observed. Penetration of the gastric mucosa results in inflammation which gives rise to some of the symptoms (Valls et al., 2003). *Anisakis* can cause gastrointestinal infection, which may be classified as acute, chronic, ectopic or allergic reactions (Bucci et al., 2013). In gastric anisakiasis, a predilection for penetration into the greater curvature of the stomach body has been suggested, with the larva embedding itself into the walls of the stomach (Kakizoe et al., 1995; Shimamura et al., 2016). Usually, a prominent gastric mucosal oedema around the area of penetration is observed endoscopically in the gastric mucosa (Kakizoe et al., 1995; Shimamura et al., 2016). Typical clinical presentation is usually reported to be acute severe epigastric pain, few hours after infected fish has been consumed, with symptoms developing within 12 h (Lee et al., 2009; Takabayashi et al., 2014). For intestinal anisakiasis, non-specific clinical characteristics such as nausea, vomiting or diarrhoea, are reported to develop within 5 days after consumption of infected fish. It is known that it takes longer time for anisakiasis symptoms to manifest in intestinal infection than in gastric anisakiasis (Takabayashi et al., 2014). Most cases of anisakiasis have previously been reported to be gastric anisakiasis and was suggested to represent about 95% of the disease burden, with intestinal anisakiasis accounting for the remaining burden of anisakiasis (Kojima et al., 2013). However, it has been recognised that in intestinal anisakiasis, patients are frequently misdiagnosed with other diseases such as inflammatory bowel disease, bowel obstruction, ulcer, acute appendicitis, diverticulitis, ileitis or cholecystitis (Miura et al., 2010) and this might have resulted in the low record of intestinal anisakiasis. In a recent report by Guardone and colleagues, it was shown that in Italy there was a similar frequency for localisation of gastric and intestinal

anisakiasis with only a slight increase for gastric lesions (Guardone et al., 2018). In another retrospective study in Japan, results were similar to Guardone's study with 47% of patients presented having gastric anisakiasis and 53% presented with small intestinal anisakiasis (Takabayashi et al., 2014). Recent cases of *Anisakis* infection have shown that contaminated raw fish may harbour several *Anisakis* larvae which may attach to multiple sites on the digestive system (Mizumura et al., 2018), with the implication that a serving of raw fish containing more than one *Anisakis* larvae results in intestinal anisakiasis after gastric anisakiasis has occurred (Mizumura et al., 2018). We speculate that in such anisakiasis infection with multiple larvae, some of the larvae may fail to embed in the walls of the stomach and after being moved by peristaltic motion, migrate into the intestine where they are able to cause intestinal anisakiasis.

Clinical manifestation of anisakiasis are not confined only to gastrointestinal symptoms but has been reported to be associated with allergy reactions in some individuals (Guardone et al., 2018; Ivanović et al., 2017; Shimamura et al., 2016). Symptoms of allergic reactions range from urticaria and angioedema to life-threatening anaphylactic shock, usually associated with gastrointestinal symptoms (Choi et al., 2009). Allergic reactions may occur after the primary infection with *Anisakis* and exposure to allergenic proteins in the food.

6. *Anisakis* as food allergen

The first allergic reaction from consumption of *Anisakis* contaminated fish was reported in Japan by Kasuya et al. (1990). The allergenic potency of *Anisakis* antigens despite the active penetration of the larvae into the gastro-intestinal tract was first pointed out in their report (Kasuya et al., 1990). Thereafter, another case of anaphylaxis allergic reaction attributed to anisakiasis was reported in a 52-year-old woman in Spain (Audicana et al., 1995). Shortly after this incidence in Spain, 28 new cases of *Anisakis* implicated allergic reaction were reported (Fernandez de Corres et al., 1996). Symptoms described for these anisakiasis cases varied and included urticaria/angioedema, facial angioedema, gastrointestinal symptoms (vomiting, diarrhea and abdominal pain), respiratory symptoms, anaphylactic shock and respiratory arrest (Fernandez de Corres et al., 1996). The fish host implicated included *Merluccius merluccius* (hake), *Engraulis encrasicolus* (anchovies) and *Gadus morhua* (cod). Importantly, some of the allergenic proteins of *Anisakis* have been found to be thermostable as well as pepsin resistant (Nieuwenhuizen and Lopata, 2013a). Not surprising, it has been documented that the ingestion of dead parasites or fragmented parts of the parasite in contaminated fish might result in allergic symptoms after consumption. Furthermore, occupational allergies in aquaculture and fishery workers, cooks as well as fishmongers have been reported, on inhalation of or contact with *A. simplex* allergens (Nieuwenhuizen et al., 2006; Nieuwenhuizen and Lopata, 2013, 2014). It is however, generally accepted that a viable larva associated with active infections is needed to induce allergic symptoms in most cases (Ivanović et al., 2017). *A. simplex* has been recognised by the WHO/IUIS nomenclature committee as the parasite with the largest number of known allergens (Fitzsimmons et al., 2014) and it has been proposed that more allergens for these parasite nematodes are yet to be discovered (Baird et al., 2016). Table 1 lists the WHO/IUIS registered *Anisakis* allergenic proteins.

A considerable problem in diagnosing and interpreting allergic reactions is the presence of cross-reactivity of *Anisakis* allergens with antigens from other nematodes as well as related invertebrates including insects, crustacean and mollusc. Some allergens of *Anisakis*, including tropomyosin and paramyosin (native and recombinant products) have demonstrated strong cross-reactivity to homologous proteins in other invertebrates, including crustaceans and mites (Nieuwenhuizen and Lopata, 2013a). Table 2 lists the identified and reported allergens in *Anisakis*, which are immunologically cross-reactive with allergenic proteins from other invertebrates. However

additional allergenic proteins in *Anisakis pegreffii* have been identified, which have cross-reactivity with proteins of shellfish (Asnoussi et al., 2017).

7. Increasing numbers of fish and crustacean hosts for *anisakis* spp

Almost three decades ago, the most common fish and shell fish sources of *A. simplex* were the spotted chub mackerel (*Scomber japonicus*) and Japanese flying squid (*Todarodes pacificus*) (Nagasawa and Moravec, 1995). However, just over a decade later, Abollo and colleagues concluded that most species of cephalopods and fish can potentially harbour these marine parasitic nematodes as 200 fish and 25 cephalopods species have been identified as hosts for *Anisakis* spp. (Abollo et al., 2001). *Anisakis* larvae are found in diverse species of fish, crustacean and cephalopods of commercial importance as detailed below (Vidaček et al., 2009).

7.1. Distribution in fish hosts

In Western Europe, herring (*Clupea harengus*) was identified as the main fish species mostly infected and involved in food-borne anisakiasis (Audicana et al., 2002), although cases with other fish species that were insufficiently cooked were also reported, these include hake (*Merluccius merluccius*), anchovy (*Engraulis encrasicolus*), mackerel (*Scomber scombrus*) and cod (*Gadus morhua*) in countries such as the Netherlands (Rodríguez et al., 2018). Most cases in Spain were related to the consumption of pickled anchovies and raw sardines (*Sardina pilchardus*) (Audicana et al., 2002; Guardone et al., 2018). Marinated anchovies are also traditional recipes in Italy and Croatia where lime may also be used to marinate the anchovies (Cipriani et al., 2018; Mladineo et al., 2016).

In Italy, most cases of human anisakidosis appear to be caused by *Anisakis pegreffii* with the L3 larvae stage of the parasite found mostly in marinated anchovies (Guardone et al., 2018). This species is the most relevant species for the Italian fishery representing 25–35% of the national fishery production (Guardone et al., 2018). In France, Salmon (*Salmo salar*) was demonstrated to be the most frequent food source associated with human anisakiasis followed by anchovies (Yera et al., 2018). In addition, European pilchards (*Sardina pilchardus*) are also reported to be frequently consumed fresh in western Mediterranean countries such as Portugal, Spain, Italy or France (Molina-Fernandez et al., 2015). Anamnesis of acute cases of anisakiasis in Spain were associated with consumption of marinated pilchards (Molina-Fernandez et al., 2015). Furthermore, in Spain, among the allergic patients with anaphylaxis a few were linked to the ingestion of pilchards that were either cooked or canned and *A. pegreffii* was found to be the predominant *Anisakis* species in pilchards from the Mediterranean basin (Buselic et al., 2018).

In Australia, *Anisakis pegreffii* L3 larvae has been identified in Tiger flathead fish (*Neoplatycephalus richardsoni*), Eastern school whiting (*Sillago flindersi*) and White trevally (*Pseudocaranx dentex*) (Asnoussi et al., 2017); but has not been associated with anisakiasis occurrence. This, has been attributed to be likely due to the high frequency of self-limiting characteristic of the infection, missed diagnosis and under-reporting since symptoms of anisakiasis are usually non-specific (EFSA-BIOHAZ, 2010), as well as probable low-level knowledge of seafood parasitology among medical experts (Shamsi and Sheorey, 2018) or low occurrence of *Anisakis* migration into the musculatures of infected fish. In China, the white-spotted conger (*Conger myriaster*) was recently reported to have a high prevalence of *Anisakis pegreffii* (Chen et al., 2018). Atlantic cod fish (*Gadus morhua*) have been associated with numerous penetrating *A. simplex* larvae (Levsen and Berland, 2012), while Atlantic salmon (*Salmo salar*) and sea trout (*Salmo trutta*) returning to rivers in Scotland, England and Wales have also been documented to be infected with a high number of *A. simplex* larvae (Buchmann and Mehrdana, 2016). In Korea, 81.3% of human anisakiasis were due to *Anisakis* type I larvae (Sohn et al., 2015); and etiologic agents of human

Table 3
List of Fish in which *Anisakis* has been found.

Continent	Fish Species	<i>Anisakis</i> found	Reference
AFRICA			
Algeria	<i>Merluccius merluccius</i> (European Hake)	<i>A. pegreffii</i> , <i>A. simplex</i>	Farjallah et al. (2008a)
	<i>Trachurus trachurus</i> (Atlantic horse mackerel)	<i>A. simplex</i>	Ichalal et al. (2015)
	<i>Boops boops</i> (Seabream fish)		
Egypt	<i>Merluccius merluccius</i> (European Hake)	<i>A. simplex</i>	Abou-Rahma et al. (2016)
Libya	<i>Merluccius merluccius</i> (European Hake)	<i>A. pegreffii</i>	(Farjallah et al., 2008a); Eissa et al. (2015)
	<i>Scorpaena porcus</i> (Scorpion fish)	<i>A. pegreffii</i>	
Mauritania	<i>Merluccius merluccius</i> (European Hake)	<i>A. pegreffii</i> , <i>A. simplex</i>	Farjallah et al. (2008b)
Morocco	<i>Scomber japonicus</i> (Chub Mackerel)	<i>A. pegreffii</i> , <i>A. simplex</i>	Abattouy et al. (2011)
	<i>Trachurus trachurus</i> (Horse mackerel)	<i>A. pegreffii</i>	Abattouy et al. (2014)
	<i>Merluccius merluccius</i> (European Hake)	<i>A. pegreffii</i> , <i>A. simplex</i>	Farjallah et al. (2008b)
Tunisia	<i>Merluccius merluccius</i> (European Hake), <i>Scomber japonicus</i> (Chub Mackerel)	<i>A. pegreffii</i>	Farjallah et al. (2008a)
ASIA			
China	<i>Conger myriaster</i> (Brevoort)	<i>A. pegreffii</i> , <i>A. simplex</i>	Chen et al. (2018)
	<i>Scomberomorus niphonius</i> (Japanese Spanish mackerel)	<i>A. simplex</i>	Kuhn et al. (2013)
	<i>Gadus macrocephalus</i> (Pacific cod)	<i>A. pegreffii</i>	
	<i>Trichiurus lepturus</i> (Largehead hairtail)	<i>A. pegreffii</i>	
Indonesia	<i>Pseudorhombus cinnamoneus</i> (Cinnamon flounder)	<i>A. pegreffii</i>	Li et al. (2017)
	<i>Auxis rochei</i> (Bullet tuna)	<i>A. pegreffii</i>	Palm et al. (2017)
Iran	<i>Saurida tumbil</i> (greater lizardfish)	<i>Anisakis</i> spp	Dadar et al. (2016)
	<i>Nemipterus japonicus</i> (Japanese thread fin bream)		
	<i>Tylosurus crocodilus crocodiles</i> (crocodile longtom)		
	<i>Carangoides armatus</i> (longfin trevally)		
	<i>Thunnus tonggol</i> (Long tail tuna fish)		
	<i>Scomberomorus commerson</i> (Narrow-barred Spanish Mackerel)		
Japan	<i>Scomber japonicus</i> (Chub Mackerel)	<i>A. simplex</i>	(Suzuki et al., 2010); Toyoda and Tanaka (2016)
		<i>A. pegreffii</i>	Fujikawa et al. (2018)
Korea	<i>Trachurus trachurus</i> (Horse mackerel)	<i>Anisakis</i> spp	
	<i>Oncorhynchus</i> spp (Salmon)		
	<i>Paralichthys olivaceus</i> (olive flounder)	<i>A. pegreffii</i>	Sohn et al. (2014)
	<i>Sebastes schlegeli</i> (Korean rockfish)		
	<i>Oncorhynchus</i> spp (Salmon)	<i>A. simplex</i>	
	<i>Gadus macrocephalus</i> (Cod)		
	<i>Sepiida</i> spp (cuttlefish)	<i>Anisakis</i> spp	Choi et al. (2017)
	<i>Conger myriaster</i> (Conger)	<i>A. pegreffii</i>	Sohn et al. (2015)
	<i>Pseudoscianea</i> spp (Croaker)		
	<i>Seriola</i> spp (Yellowtail fish)		
Taiwanese coast	<i>Trichiurus lepturus</i> (Cutlass fish)	<i>A. simplex</i>	Shih (2004)
	<i>Scomber australasicus</i> (Spotted Mackerel)	<i>A. pegreffii</i> , <i>A. simplex</i>	Chen and Shih (2015)
AUSTRALIA AND OCEANIA			
Antarctica	<i>Electrona Antarctica</i> (Lantern fishes)	<i>A. Pegreffii</i> , <i>A. simplex</i>	Klimpel et al. (2010)
South Australia	<i>Sillago findersi</i> (Eastern School Whiting)	<i>A. pegreffii</i>	Jabbar et al. (2012)
Western Australia	<i>Pseudocaranx dentex</i> (White trevally)	<i>A. pegreffii</i>	Jabbar et al. (2013)
Victoria (Melbourne)	<i>Neoplatycephalus richardsoni</i> (Flat head Tiger Fish)	<i>A. pegreffii</i>	Asnoussi et al. (2017)
EUROPE			
Adriatic Sea	<i>Engraulis encrasicolus</i> (Anchovies)	<i>A. pegreffii</i>	Cipriani et al. (2016)
Austria	<i>Clupea harengus</i> (herring)	<i>Anisakis</i> spp	Kapral et al. (2009)
Belgium	<i>Pollachius pollachius</i> (Pollock)	<i>A. simplex</i>	Piccolo et al. (1999)
	<i>Gadus morhua</i> (Cod),		
	<i>Pollachius virens</i> (Saithe),		
	<i>Merlangius merlangus</i> (Whiting)		
	<i>Micromesistius australis</i> (Southern blue whiting)		
German coast	<i>Macruronus magellanicus</i> (Hakes)		
	<i>Clupea harengus</i> (Atlantic herring)	<i>A. simplex</i>	Kuhn et al. (2013)
Italy	<i>Merluccius gayi</i> (Hake Merluza)	<i>A. pegreffii</i>	(Cipriani et al., 2015; Mattiucci et al., 2013)
			(Bucci et al., 2013; Fumarola et al., 2009)
	<i>Engraulis encrasicolus</i> (raw Anchovies)	<i>Anisakis</i> spp	Kuhn et al. (2013)
Norway	<i>Merluccius merluccius</i> (European hake)	<i>A. pegreffii</i>	
	<i>Scomber japonicus</i> (Chub Mackerel)	<i>A. pegreffii</i>	
	<i>Micrelaps muelleri</i> (Bristle-mouth fishes)	<i>A. simplex</i>	Klimpel et al. (2004)
Portugal (Madeira)	<i>Pollachius virens</i> -Pollock (White fish)		
	<i>Aphanopus carbo</i> (Black scabbardfish)	<i>A. simplex</i>	Kuhn et al. (2013)
Spain	<i>Merluccius gayi</i> (Hake Merluza)	<i>A. pegreffii</i>	Cipriani et al. (2015).
		<i>A. simplex</i>	
	<i>Trachurus trachurus</i> (Horse mackerel)	<i>A. simplex</i>	Adroher et al. (1996).
	<i>Micromesistius poutassou</i> (Blue whiting fish)	<i>A. simplex</i>	Bucci et al. (2013)
United Kingdom (UK)	<i>Engraulis encrasicolus</i> (Anchovies)	<i>A. simplex</i>	(Repiso et al., 2003)
	<i>Oncorhynchus</i> spp (Salmon) and pickled fish	<i>Anisakis</i> spp	Lucas et al. (1985)
NORTH AMERICA			

(continued on next page)

Table 3 (continued)

Continent	Fish Species	Anisakis found	Reference
Canada	<i>Salvelinus alpinus</i> (Arctic char)	<i>Anisakis</i> spp	Bhat and Cleland (2010)
	<i>Oncorhynchus</i> spp (Salmon)	<i>A. simplex</i>	(Madi et al., 2013); (Vaughan et al., 2015)
California (USA)	<i>Sebastes</i> sp (Red snapper)	<i>Anisakis</i> type 1	Kliks (1983)
	<i>Oncorhynchus</i> spp (Salmon)	<i>A. simplex</i>	(Kuhn et al., 2013)
	<i>Anoplopoma fimbria</i> (Sable fish)		
Alaska	<i>Oncorhynchus keta</i> (Chum salmon)	<i>A. simplex</i>	Kuhn et al. (2013)
	<i>Oncorhynchus nerka</i> (red salmon)		
Hawaii	<i>Cololabis saira</i> (Mackerel pike)	<i>A. simplex</i>	Kuhn et al. (2013)
SOUTH AMERICA			
Ecuador	<i>Merluccius gayi</i> (Hake Merluza)	<i>A. pegreffii</i>	Castellanos et al. (2018)
Chile	<i>Merluccius gayi</i> (Chilean hake)	<i>A. simplex</i>	Mercado et al. (2001)
	<i>Macrouronus magellanicus</i> (tail-hake)		
	<i>Genypterus chilensis</i> (redconger-eel)		
	<i>Paralichthys microps</i> (flat fish),		
	<i>Trachurus murphyi</i> (Chilean mackerel)		
	<i>Merluccius australis</i> (Southern Hake).	<i>Anisakis</i> spp	Chavez et al. (2012)
	<i>Micromesistius australis</i> (Southern blue whiting)		
	<i>Macrouronus magellanicus</i> (Hakes)		

as use of anthelmintic drugs and condiments (Brutti et al., 2010; Tejada et al., 2015). Storage, after-harvest handling and fish preparation are the focus of preventive measures. Migration of larvae into the muscle might be prevented by immediate evisceration of fish after being caught (Chen et al., 2018). However, since this immediate cleaning may most likely be performed at sea, resulting in removed contaminated viscera being thrown back into the sea and eaten by other fish, the prevalence of infection may be heightened through this practice (McClelland et al., 1990).

The recommended and common method to kill the larvae in fish before consumption is the application of high or low temperatures (Chen et al., 2014). The US Food and Drug Administration (FDA) recommended that fish be cooked to a temperature of at least 63 °C–74 °C before consumption (Beldsoe and Oria, 2001). Larvae of *Anisakis* species have been observed to be alive if frozen for a short period at –20 °C. The FDA has recommended that fish be kept frozen at –20 °C for at least 168 h or blast-frozen at –35 °C for at least 15 h (Beldsoe and Oria, 2001).

9. Food safety consideration

Parasitological surveys for *Anisakis* larvae in consumed seafoods and particularly fish host is crucial to ensure food safety. The parasite burden in the edible flesh of the fish need to be evaluated as this constitutes the main threat to public health (Cipriani et al., 2016). In addition, since the possibility of intra-vitam migration of larvae to the fish flesh has been documented (Cipriani et al., 2016), the storage temperature after fish capture becomes crucial in the post-mortem motility of *Anisakis* larvae into the flesh of fish. This emphasizes the importance of the regulations which specify freezing of fish products at –20 °C for 24 h, or at –18 °C for 96 h in domestic freezers before utilisation in food preparation, to prevent human anisakiasis. It is however important to consider that allergenic proteins from *Anisakis* may still be present in food products after removal of intact worms (Audicana et al., 1997).

10. Conclusion

In conclusion, the existence of *Anisakis* parasites in a variety of mesozooplankton organisms suggests, according to Gregori and colleagues (Gregori et al., 2015) that the transmission routes of *A. simplex* and *A. pegreffii* are much broader than previously known. This indicates that *Anisakis* species may not be specific to any intermediate host and

may use any of the named intermediate hosts to move from one habitat to another depending on the seasonal and ecological availability of such intermediate hosts. This may result in *Anisakis* species expanding their pathways to find their definitive host. The implication of this is an increase in occurrence of anisakiasis across the globe with a potential increase in anisakiasis and allergic reactions accompanied by cross-reactivity to homologous proteins in other invertebrates. More attention needs to be given to this parasite to develop better risk management system of the cascading reactions that may follow infection and sensitisation caused by consumption of *Anisakis* contaminated raw or inadequately treated fish and/shellfish.

Acknowledgement

Andreas Lopata received financial support via an Australian Research Council (FT110100635) Future Fellowship for this work.

Appendix A. Supplementary data

Supplementary data to this article can be found online at <https://doi.org/10.1016/j.ijppaw.2019.04.007>.

References

- Abattouy, N., Valero, A., Benajiba, M.H., Lozano, J., Martin-Sanchez, J., 2011. *Anisakis simplex* s.l. parasitization in mackerel (*Scomber japonicus*) caught in the North of Morocco—prevalence and analysis of risk factors. *Int. J. Food Microbiol.* 150, 136–139.
- Abattouy, N., Lopez, A.V., Maldonado, J.L., Benajiba, M.H., Martin-Sanchez, J., 2014. Epidemiology and molecular identification of *Anisakis pegreffii* (Nematoda: Anisakidae) in the horse mackerel *Trachurus trachurus* from northern Morocco. *J. Helminthol.* 88, 257–263.
- Abollo, E., Gestal, C., Lopez, A., Gonzalez, F., Guerra, A., Pascual, S., 1998. Squid as trophic bridges for parasite flow within marine ecosystems: the case of *A. simplex* (Nematoda:Anisakidae), or when the wrong way can be right. *S. Afr. J. Mar. Sci.* 20, 10.
- Abollo, E., Gestal, C., Pascual, S., 2001. *Anisakis* infestation in marine fish and cephalopods from Galician waters: an updated perspective. *Parasitol. Res.* 87, 492–499.
- Abollo, E., Paggi, L., Pascual, S., D'Amelio, S., 2003. Occurrence of recombinant genotypes of *Anisakis simplex* s.s. and *Anisakis pegreffii* (Nematoda: Anisakidae) in an area of sympatry. *Infect. Genet. Evol.* 3, 175–181.
- Abou-Rahma, Y., Abdel-Gaber, R., Kamal Ahmed, A., 2016. First record of *Anisakis simplex* third-stage larvae (Nematoda, Anisakidae) in European hake *Merluccius merluccius lessepsianus* in Egyptian water. *J. Parasitol. Res.* 2016, 9609752. <https://doi.org/10.1155/2016/9609752>.
- Adroher, F.J., Valero, A., Ruiz-Valero, J., Iglesias, L., 1996. Larval anisakids (Nematoda: Ascaridoidea) in horse mackerel (*Trachurus trachurus*) from the fish market in Granada, Spain. *Parasitol. Res.* 82, 319–322.

- Amir, A., Ngui, R., Ismail, W.H., Wong, K.T., Ong, J.S., Lim, Y.A., Lau, Y.L., Mahmud, R., 2016. Anisakiasis causing acute dysentery in Malaysia. *Am. J. Trop. Med. Hyg.* 95 (2), 410–412.
- Andreasen, J., Jorring, K., 1970. Anisakidosis in Denmark. Infection with nematode larvae from marine fishes. *Nord. Med.* 84, 1492–1495.
- Arizono, N., Yamada, M., Tegoshi, T., Yoshikawa, M., 2012. *Anisakis simplex* sensu stricto and *Anisakis pegreffii*: biological characteristics and pathogenetic potential in human anisakiasis. *Foodb. Pathog. Dis.* 9, 517–521.
- Asnoussi, A., Aibinu, I.E., Gasser, R.B., Lopata, A.L., Smooker, P.M., 2017. Molecular and immunological characterisation of tropomyosin from *Anisakis pegreffii*. *Parasitol. Res.* 116, 3291–3301.
- Asturias, J.A., Eraso, E., Moneo, I., Martinez, A., 2000. Is tropomyosin an allergen in *Anisakis*? *Allergy* 55, 898–899.
- Audicana, M.T., Kennedy, M.W., 2008. *Anisakis simplex*: from obscure infectious worm to inducer of immune hypersensitivity. *Clin. Microbiol. Rev.* 21, 360–379.
- Audicana, M.T., Fernandez de Corres, L., Munoz, D., Fernandez, E., Navarro, J.A., del Pozo, M.D., 1995. Recurrent anaphylaxis caused by *Anisakis simplex* parasitizing fish. *J. Allergy Clin. Immunol.* 96, 558–560.
- Audicana, M.T., Audicana, M.T., de Corres, L.F., Kennedy, M.W., 1997. Cooking and freezing may not protect against allergic reactions to ingested *Anisakis simplex* antigens in humans. *Vet. Rec.* 140, 235.
- Audicana, M.T., Ansotegui, I.J., de Corres, L.F., Kennedy, M.W., 2002. *Anisakis simplex*: dangerous–dead and alive? *Trends Parasitol.* 18, 20–25.
- Baird, F.J., Gasser, R.B., Jabbar, A., Lopata, A.L., 2014. Foodborne anisakiasis and allergy. *Mol. Cell. Probes* 28, 167–174.
- Baird, F.J., Su, X., Aibinu, I., Nolan, M.J., Sugiyama, H., Otranto, D., Lopata, A.L., Cantacessi, C., 2016. The *Anisakis* transcriptome provides a resource for fundamental and applied studies on allergy-causing parasites. *PLoS Neglected Trop. Dis.* 10, e0004845. <https://doi.org/10.1371/journal.pntd.0004845>.
- Beldsoe, G.E., Oria, M.P., 2001. Potential hazards in cold-smoked fish: parasites. *J. Food Sci.* 66, S1100–S1103.
- Berland, B., 1961. Nematodes from some Norwegian marine fishes. *Sarsia* 2, 1–50.
- Bhat, M., Cleland, P., 2010. Gastric anisakiasis. *Clin. Gastroenterol. Hepatol.* 8, A20. <https://doi.org/10.1016/j.cgh.2009.12.020>.
- Borges, J.N., Cunha, L.F., Santos, H.L., Monteiro-Neto, C., Portes Santos, C., 2012. Morphological and molecular diagnosis of anisakid nematode larvae from cutlassfish (*Trichiurus lepturus*) off the coast of Rio de Janeiro, Brazil. *PLoS One* 7, e40447. <https://doi.org/10.1371/journal.pone.0040447>.
- Brutti, A., Rovere, P., Cavallero, S., D'Amelio, S., Danesi, P., Arcangeli, G., 2010. Inactivation of *Anisakis simplex* larvae in raw fish using high hydrostatic pressure treatments. *Food Control* 21, 331–333.
- Bucci, C., Gallotta, S., Morra, I., Fortunato, A., Ciacci, C., Iovino, P., 2013. *Anisakis*, just think about it in an emergency!. *Int. J. Infect. Dis.* 17, e1071–1072. <https://doi.org/10.1016/j.ijid.2013.05.008>.
- Buchmann, K., Mehrdana, F., 2016. Effects of anisakid nematodes *Anisakis simplex* (s.l.), *Pseudoterranova decipiens* (s.l.) and *Contracaecum osculatatum* (s.l.) on fish and consumer Health. *Food Waterborn Parasitol* 4, 13–22. <https://doi.org/10.1016/j.fawpar.2016.07.003>.
- Buselic, I., Botić, A., Hrabar, J., Stagic, N., Cipriani, P., Mattiucci, S., Mladineo, I., 2018. Geographic and host size variations as indicators of *Anisakis pegreffii* infection in European pilchard (*Sardina pilchardus*) from the Mediterranean Sea: food safety implications. *Int. J. Food Microbiol.* 266, 126–132. <https://doi.org/10.1016/j.ijfoodmicro.2017.11.021>.
- Caballero, M.L., Umpierrez, A., Moneo, I., Rodriguez-Perez, R., 2011. Ani s 10, a new *Anisakis simplex* allergen: cloning and heterologous expression. *Parasitol. Int.* 60, 209–212.
- Caramello, P., Vitali, A., Canta, F., Caldana, A., Santi, F., Caputo, A., Lipani, F., Balbiano, R., 2003. Intestinal localization of anisakiasis manifested as acute abdomen. *Clin. Microbiol. Infect.* 9, 734–737.
- Castellanos, J.A., Santana-Pineros, A.M., Mercado, R., Pena, S., Pustovrh, C., Cruz-Quintana, Y., 2018. Presence of anisakid larvae in commercial fishes landed in the pacific coast of Ecuador and Colombia. *Infectio* 22, 206.
- Chavez, R.A., Gonzalez, M.T., Oliva, M.E., Valdivia, I.M., 2012. Endoparasite fauna of five Gadiformes fish species from the coast of Chile: host ecology versus phylogeny. *J. Helminthol.* 86, 10–15.
- Chen, H.Y., Shih, H.H., 2015. Occurrence and prevalence of fish-borne *Anisakis* larvae in the spotted mackerel *Scomber australasicus* from Taiwanese waters. *Acta Trop.* 145, 61–67.
- Chen, H.Y., Cheng, Y.S., Grabner, D.S., Chang, S.H., Shih, H.H., 2014. Effect of different temperatures on the expression of the newly characterized heat shock protein 90 (Hsp90) in L3 of *Anisakis* spp. isolated from *Scomber australasicus*. *Vet. Parasitol.* 205, 540–550.
- Chen, H.X., Zhang, L.P., Gibson, D.I., Lu, L., Xu, Z., Li, H.T., Ju, H.D., Li, L., 2018. Detection of ascaridoid nematode parasites in the important marine food-fish *Conger myriaster* (Brevoort) (Anguilliformes: Congridae) from the Zhoushan Fishery, China. *Parasites Vectors* 11, 274. <https://doi.org/10.1186/s13071-018-2850-4>.
- Choi, S.J., Lee, J.C., Kim, M.J., Hur, G.Y., Shin, S.Y., Park, H.S., 2009. The clinical characteristics of *Anisakis* allergy in Korea. *Korean J. Intern. Med.* 24, 160–163.
- Choi, S.K., Kim, C.K., Kim, S.H., Jo, D.I., 2017. Anisakiasis involving the oral mucosa. *Arch. Craniofac. Surg.* 18, 261–263.
- Cipriani, P., Smaldone, G., Acerra, V., D'Angelo, L., Anastasio, A., Bellisario, B., Palma, G., Nascetti, G., Mattiucci, S., 2015. Genetic identification and distribution of the parasitic larvae of *Anisakis pegreffii* and *Anisakis simplex* (s. s.) in European hake *Merluccius merluccius* from the Tyrrhenian Sea and Spanish Atlantic coast: implications for food safety. *Int. J. Food Microbiol.* 198, 1–8.
- Cipriani, P., Acerra, V., Bellisario, B., Sbaraglia, G.L., Chelieschi, R., Nascetti, G., Mattiucci, S., 2016. Larval migration of the zoonotic parasite *Anisakis pegreffii* (Nematoda: Anisakidae) in European anchovy, *Engraulis encrasicolus*: implications to seafood safety. *Food Control* 59, 148–157.
- Cipriani, P., Sbaraglia, G.L., Palomba, M., Giulietti, L., Bellisario, B., Bušelić, I., Mladineo, I., Chelieschi, R., Nascetti, G., Mattiucci, S., 2018. *Anisakis pegreffii* (Nematoda: Anisakidae) in European anchovy, *Engraulis encrasicolus*, from the mediterranean sea: fishing ground as a predictor of parasite distribution. *Fish. Res.* 202, 59–68.
- Dadar, M., Alborzi, A., Peyghan, R., Adel, M., 2016. Occurrence and intensity of anisakid nematode larvae in some commercially important fish species in Persian Gulf. *Iran. J. Parasitol.* 11, 239–246.
- EFSA-BIOHAZ, 2010. Scientific opinion on risk assessment of parasites in fishery products. *EFSA J.* 8, 1543.
- Eiras, J.C., Pavanelli, G.C., Takemoto, R.M., Nawa, Y., 2018. Fish-borne nematodiasis in South America: neglected emerging diseases. *J. Helminthol.* 92, 649–654.
- Eissa, A.E., Abdelsalam, M., Abumhara, A., Kammon, A., Gammoudi, F.T., Naser, K., Borhan, T., Asheg, A., 2015. First Record of *Vibrio vulnificus*/*Anisakis pegreffii* concurrent infection in black scorpionfish (*Scorpaena porcus*) from the South Mediterranean basin. *Res. J. Pharmaceut. Biol. Chem. Sci.* 6, 1537–1548.
- Farjallah, S., Slimane, B.B., Busi, M., Paggi, L., Amor, N., Blel, H., Said, K., D'Amelio, S., 2008a. Occurrence and molecular identification of *Anisakis* spp. from the North African coasts of mediterranean sea. *Parasitol. Res.* 102, 371–379.
- Farjallah, S., Busi, M., Mahjoub, M.O., Slimane, B.B., Paggi, L., Said, K., D'Amelio, S., 2008b. Molecular characterization of larval anisakid nematodes from marine fishes off the Moroccan and Mauritanian coasts. *Parasitol. Int.* 57, 430–436.
- Fernandez de Corres, L., Audicana, M., Del Pozo, M.D., Munoz, D., Fernandez, E., Navarro, J.A., Garcia, M., Diez, J., 1996. *Anisakis simplex* induces not only anisakiasis: report on 28 cases of allergy caused by this nematode. *J. Investig. Allergol. Clin. Immunol.* 6, 315–319.
- Fitzsimmons, C.M., Falcone, F.H., Dunne, D.W., 2014. Helminth allergens, parasite-specific IgE, and its protective role in human immunity. *Front. Immunol.* 5, 61. <https://doi.org/10.3389/fimmu.2014.00061>.
- Fujikawa, H., Kuwai, T., Yamaguchi, T., Miura, R., Sumida, Y., Takasago, T., Miyasako, Y., Nishimura, T., Iio, S., Imagawa, H., Yamaguchi, A., Kouno, H., Kohno, H., 2018. Gastric and enteric anisakiasis successfully treated with gastrografin therapy: a case report. *World J. Gastrointest. Endosc.* 10, 69–73.
- Fumarola, L., Monno, R., Lerardi, E., Rizzo, G., Giannelli, G., Lalle, M., 2009. *Anisakis pegreffii* etiological agent of gastric infections in two Italian women. *Foodb. Pathog. Dis.* 6, 1157–1159.
- Gasser, R.B., Hu, M., Chilton, N.B., Campbell, B.E., Jex, A.J., Otranto, D., Cafarchia, C., Beveridge, I., Zhu, X., 2006. Single-strand conformation polymorphism (SSCP) for the analysis of genetic variation. *Nat. Protoc.* 1, 3121–3128.
- Gomez-Gutierrez, J., Robinson, C.J., Kawaguchi, S., Nicol, S., 2010. Parasite diversity of *Nyctiphanes simplex* and *Nematoscelis diffilis* (Crustacea: euphausiacea) along the northwestern coast of Mexico. *Dis. Aquat. Org.* 88, 249–266.
- Gonzalez-Fernandez, J., Daschner, A., Nieuwenhuizen, N.E., Lopata, A.L., Frutos, C.D., Valls, A., Cuellar, C., 2015. Haemoglobin, a new major allergen of *Anisakis simplex*. *Int. J. Parasitol.* 45, 399–407.
- Gregori, M., Roura, A., Abollo, E., Gonzalez, A.F., Pascual, S., 2015. *Anisakis simplex* complex (Nematoda: Anisakidae) in zooplankton communities from temperate NE Atlantic waters. *J. Nat. Hist.* 49, 755–773.
- Guardone, L., Armani, A., Nucera, D., Costanzo, F., Mattiucci, S., Bruschi, F., 2018. Human anisakiasis in Italy: a retrospective epidemiological study over two decades. *Parasite* 25, 41. <https://doi.org/10.1051/parasite/2018034>.
- Guarneri, F., Guarneri, C., Benvenega, S., 2007. Cross-reactivity of *Anisakis simplex*: possible role of Ani s 2 and Ani s 3. *46, 146–150.*
- Herrador, S., Daschner, A., Perteguer, M.J., Benito, A., 2018. Epidemiological scenario of anisakidosis in Spain based on associated hospitalizations: the tipping point of the iceberg. *Clin. Infect. Dis.* ciy853. <https://doi.org/10.1093/cid/ciy853>.
- Højgaard, D.P., 1999. Food and parasitic nematodes of saithe, *Pollachius virens* (L.), from the Faroe Islands. *Sarsia* 84, 6.
- Ichalal, K., Ramdane, Z., Ider, D., Kacher, M., Iguerouada, M., Trilles, J.P., Courcot, L., Amara, R., 2015. Nematodes parasitizing *Trachurus trachurus* (L.) and *Boops boops* (L.) from Algeria. *Parasitol. Res.* 114, 4059–4068.
- Iglesias, R., D'Amelio, S., Ingrassio, S., Farjallah, S., Martinez-Cedeira, J.A., Garcia-Estevez, J.M., 2008. Molecular and morphological evidence for the occurrence of *Anisakis* sp. A (Nematoda, Anisakidae) in the Blainville's beaked whale *Mesoplodon densirostris*. *J. Helminthol.* 82, 305–308.
- Ivanovic, J., Baltić, M.Z., Bosković, M., Kilbarda, N., Dokmanović, M., Marković, R., Janjić, J., Baltić, B., 2015. *Anisakis* infection and allergy in humans. *Procedia Food Sci.* 5, 101–104.
- Ivanović, J., Baltić, M.Ž., Bošković, M., Kilbarda, N., Dokmanović, M., Marković, R., Janjić, J., Baltić, B., 2017. *Anisakis* allergy in human. *Trends Food Sci. Technol.* 59, 25–29.
- Iwata, K., Fukuchi, T., Yoshimura, K., 2015. Is the quality of sushi ruined by freezing raw fish and squid? A randomized double-blind trial with sensory evaluation using discrimination testing. *Clin Infect Dis.* 60 (9), e43–e48.
- Jabbar, A., Khoon, A.T., Hui, T.X., Schaeffner, B.C., Jex, A.R., Nolan, M.J., Lopata, A., Gasser, R.B., Beveridge, I., 2012. Mutation scanning-based analysis of anisakid larvae from *Sillago flindersi* from Bass Strait, Australia. *Electrophoresis* 33, 499–505.
- Jabbar, A., Fong, R.W., Kok, K.X., Lopata, A.L., Gasser, R.B., Beveridge, I., 2013. Molecular characterization of anisakid nematode larvae from 13 species of fish from Western Australia. *Int. J. Food Microbiol.* 161, 247–253.
- Jacobsen, K.B., Berland, B., 1969. Fish nematodes as a cause of acute and chronic gastroenteritis with tissue eosinophilia. *Nord. Med.* 82, 1104–1111.
- Kakizoe, S., Kakizoe, H., Kakizoe, K., Kakizoe, Y., Maruta, M., Kakizoe, T., Kakizoe, S., 1995. Endoscopic findings and clinical manifestation of gastric anisakiasis. *Am. J.*

- Gastroenterol. 90, 761–763.
- Kalay, M., Donmez, A.E., Koyuncu, C.E., Genc, E., Sahin, G., 2009. Seasonal variation of *Hysterothylacium aduncum* (Nematoda: Raphidascarididae) infestation in sparid fishes in the Northeast Mediterranean sea. *Turk. J. Vet. Anim. Sci.* 33, 517–523.
- Kapral, C., Haditsch, M., Wewalka, F., Schatzlmayr, W., Lenz, K., Auer, H., 2009. The first case of anisakiasis acquired in Austria. *Z. Gastroenterol.* 47, 1059–1061.
- Kasuya, S., Hamano, H., Izumi, S., 1990. Mackerel-induced urticaria and *anisakis*. *Lancet* 335, 665.
- Klicks, M.M., 1983. Anisakiasis in the western United States: four new case reports from California. *Am. J. Trop. Med. Hyg.* 32, 526–532.
- Klimpel, S., Palm, H.W., Ruckert, S., Piatkowski, U., 2004. The life cycle of *Anisakis simplex* in the Norwegian Deep (northern North Sea). *Parasitol. Res.* 94, 1–9.
- Klimpel, S., Busch, M.W., Kuhn, T., Rohde, A., Palm, H.W., 2010. The *Anisakis simplex* complex off the South Shetland Islands (Antarctica): endemic populations versus introduction through migratory hosts. *Mar. Ecol. Prog. Ser.* 403, 12.
- Kobayashi, Y., Ishizaki, S., Shimakura, K., Nagashima, Y., Shiomi, K., 2007. Molecular cloning and expression of two new allergens from *Anisakis simplex*. *Parasitol. Res.* 100, 1233–1241.
- Kobayashi, Y., Ohsaki, K., Ikeda, K., Kakemoto, S., Ishizaki, S., Shimakura, K., Nagashima, Y., Shiomi, K., 2011. Identification of novel three allergens from *Anisakis simplex* by chemiluminescent immunoscreening of an expression cDNA library. *Parasitol. Int.* 60, 144–150.
- Kobayashi, Y., Kakemoto, S., Shimakura, K., Shiomi, K., 2015. Molecular cloning and expression of a new major allergen, Ani s 14, from *Anisakis simplex*. *Shokuhin Eiseigaku Zasshi* 56, 194–199.
- Kojima, G., Usuki, S., Mizokami, K., Tanabe, M., Machi, J., 2013. Intestinal anisakiasis as a rare cause of small bowel obstruction. *Am. J. Emerg. Med.* 31 <https://doi.org/10.1016/j.ajem.2013.05.015>. 1422.e1–2.
- Kuhn, T., Hailer, F., Palm, H.W., Klimpel, S., 2013. Global assessment of molecularly identified *Anisakis* Dujardin, 1845 (Nematoda: Anisakidae) in their teleost intermediate hosts. *Folia Parasitol.* 60, 123–134.
- Lee, E.J., Kim, Y.C., Jeong, H.G., Lee, O.J., 2009. The mucosal changes and influencing factors in upper gastrointestinal anisakiasis: analysis of 141 cases. *Korean J. Gastroenterol.* 53, 90–97.
- Leuckart, R., 1876. Die menschlichen Parasiten und die von ihnen herrührenden Krankheiten, 2,3. 513–882 Leipzig.
- Levsen, A., Berland, B., 2012. *Anisakis* species. In: Woo, P.T.K., Buchmann, K. (Eds.), *Fish Parasites, Pathobiology and Protection*. CAB International, pp. 298–309.
- Li, S.W., Shiao, S.H., Weng, S.C., Liu, T.H., Su, K.E., Chen, C.C., 2015. A case of human infection with *Anisakis simplex* in Taiwan. *Gastrointest. Endosc.* 82, 757–758.
- Li, L., Zhao, J., Chen, H., Ju, H., An, M., Xu, Z., Zhang, L., 2017. Survey for the presence of ascaridoid larvae in the cinnamon flounder *Pseudorhombus cinnamomeus* (Temminck & Schlegel) (Pleuronectiformes: Paralichthyidae). *Int. J. Food Microbiol.* 241, 108–116.
- Lim, H., Jung, B.K., Cho, J., Yooyen, T., Shin, E.H., Chai, J.Y., 2015. Molecular diagnosis of cause of anisakiasis in humans, South Korea. *Emerg. Infect. Dis.* 21, 342–344.
- Lucas, S.B., Cruse, J.P., Lewis, A.A., 1985. Anisakiasis in the United Kingdom. *Lancet* 2, 843–844.
- Madi, L., Ali, M., Legace-Wiens, P., Duerksen, D.R., 2013. Gastrointestinal manifestations and management of anisakiasis. *Can. J. Gastroenterol.* 27, 126–127.
- Mattiucci, S., Nascetti, G., 2006. Molecular systematics, phylogeny and ecology of anisakid nematodes of the genus *Anisakis* Dujardin, 1845: an update. *Parasite* 13, 99–113.
- Mattiucci, S., Nascetti, G., 2008. Advances and trends in the molecular systematics of anisakid nematodes, with implications for their evolutionary ecology and host-parasite co-evolutionary processes. *Adv. Parasitol.* 66, 47–148.
- Mattiucci, S., Paoletti, M., Webb, S.C., 2009. *Anisakis nascettii* n. sp. (Nematoda: Anisakidae) from beaked whales of the southern hemisphere: morphological description, genetic relationships between congeners and ecological data. *Syst. Parasitol.* 74, 199–217.
- Mattiucci, S., Fazii, P., De Rosa, A., Paoletti, M., Megna, A.S., Glielmo, A., De Angelis, M., Costa, A., Meucci, C., Calvaruso, V., Sorrentini, I., Palma, G., Bruschi, F., Nascetti, G., 2013. Anisakiasis and gastroallergic reactions associated with *Anisakis pegreffii* infection. *Italy. Emerg Infect Dis.* 19, 496–499.
- Mattiucci, S., Cipriani, P., Webb, S.C., Paoletti, M., Marcer, F., Bellisario, B., Gibson, D.I., Nascetti, G., 2014. Genetic and morphological approaches distinguishing the three sibling species of the *Anisakis simplex* species complex, with a species designation as *Anisakis berlandi* n. sp. for *A. simplex* sp. C (Nematoda: Anisakidae). *J. Parasitol.* 100, 199–214.
- Mattiucci, S., Cipriani, P., Levsen, A., Paoletti, M., Nascetti, G., 2018. Molecular epidemiology of *anisakis* and anisakiasis: an ecological and evolutionary road map. *Adv. Parasitol.* 99, 93–263.
- McClelland, G., R.K., M.D.J., 1990. Larval anisakine nematodes in various fish species from Sable Island Bank and vicinity. *Can. Bull. Fish. Aquat. Sci.* 222, 83–118.
- Mercado, R., Torres, P., Munoz, V., Apt, W., 2001. Human infection by *Pseudoterranova decipiens* (Nematoda, Anisakidae) in Chile: report of seven cases. *Mem. Inst. Oswaldo Cruz* 96, 653–655.
- Miura, T., Iwaya, A., Shimizu, T., Tsuchiya, J., Nakamura, J., Yamada, S., Miura, T., Yanagi, M., Usuda, H., Emura, I., Takahashi, T., 2010. Intestinal anisakiasis can cause intussusception in adults: an extremely rare condition. *World J. Gastroenterol.* 16, 1804–1807.
- Mizumura, N., Okumura, S., Tsuchihashi, H., Ogawa, M., Kawasaki, M., 2018. A Second Attack of *Anisakis*: intestinal anisakiasis following gastric anisakiasis. *ACG Case Rep. J.* 5, e65. <https://doi.org/10.14309/crj.2018.65>.
- Mladineo, I., Popovic, M., Drmic-Hofman, I., Poljak, V., 2016. A case report of *Anisakis pegreffii* (Nematoda, Anisakidae) identified from archival paraffin sections of a Croatian patient. *BMC Infect. Dis.* 16, 42. <https://doi.org/10.1186/s12879-016-1401-x>.
- Molina-Fernandez, D., Malagon, D., Gomez-Mateos, M., Benitez, R., Martin-Sanchez, J., Adroher, F.J., 2015. Fishing area and fish size as risk factors of *Anisakis* infection in sardines (*Sardina pilchardus*) from Iberian waters, southwestern Europe. *Int. J. Food Microbiol.* 203, 27–34.
- Moneo, I., Caballero, M.L., Gómez, F., Ortega, E., Alonso, M.J., 2000. Isolation and characterization of a major allergen from the fish parasite *Anisakis simplex*. *J. Allergy Clin. Immunol.* 106, 177–182.
- Moneo, I., Caballero, M.L., Gonzalez-Munoz, M., Rodriguez-Mahillo, A.I., Rodriguez-Perez, R., Silva, A., 2005. Isolation of a heat-resistant allergen from the fish parasite *Anisakis simplex*. *Parasitol. Res.* 96, 285–289.
- Mouritsen, K.N., Hedeholm, R., Schack, H.B., Møller, L.N., Storr-Paulsen, M., Dzido, J., Rokicki, J., 2010. Occurrence of anisakid nematodes in Atlantic cod (*Gadus morhua*) and Greenland cod (*Gadus ogac*). *West Greenland. Acta Parasitol.* 55, 81–89.
- Nagasawa, K., Moravec, F., 1995. Larval anisakid nematodes of Japanese common squid (*Todarodes pacificus*) from the Sea of Japan. *J. Parasitol.* 81, 69–75.
- Nieuwenhuizen, N.E., Lopata, A.L., 2013. *Anisakis* – a food-borne parasite that triggers allergic host defences. *Int. J. Parasitol.* 43, 1047–1057.
- Nieuwenhuizen, N.E., Lopata, A.L., 2014. Allergic reactions to *Anisakis* found in fish. *Curr. Allergy Asthma Rep.* 14, 455. <https://doi.org/10.1007/s11882-014-0455-3>.
- Nieuwenhuizen, N., Lopata, A.L., Jeebhay, M.F., Herbert, D.R., Robins, T.G., Brombacher, F., 2006. Exposure to the fish parasite *Anisakis* causes allergic airway hyperreactivity and dermatitis. *J. Allergy Clin. Immunol.* 117, 1098–1105.
- Orphanet, 2016. Prevalence and incidence of rare diseases: bibliographic data. Orphanet Rep. Ser. 1 Available at: http://www.orpha.net/orphacom/cahires/docs/GB/Prevalence_of_rare_diseases_by_alphabetical_list.pdf.
- Palm, H.W., Theisen, S., Damriyasa, I.M., Kusmintarsih, E.S., Oka, I.B., Setyowati, E.A., Suratna, N.A., Wibowo, S., Kleiner, S., 2017. *Anisakis* (Nematoda: Ascaridoidea) from Indonesia. *Dis. Aquat. Org.* 123, 141–157.
- Pampiglione, S., Rivasi, F., Criscuolo, M., De Benedittis, A., Gentile, A., Russo, S., Testini, M., Villan, M., 2002. Human anisakiasis in Italy: a report of eleven new cases. *Pathol. Res. Pract.* 198, 429–434.
- Perez-Perez, J., Fernandez-Caldas, E., Maranon, F., Sastre, J., Bernal, M.L., Rodriguez, J., Bedate, C.A., 2000. Molecular cloning of paramyosin, a new allergen of *Anisakis simplex*. *Int. Arch. Allergy Immunol.* 123, 120–129.
- Piccolo, G., Manfredi, M., Hoste, L., Vercruyse, J., 1999. Anisakidae larval infection in fish filets sold in Belgium. *Vet. Q.* 21, 66–67.
- Pozio, E., 2013. Integrating animal health surveillance and food safety: the example of *Anisakis*. *Rev. Sci. Tech.* 32, 487–496.
- Qin, Y., Zhao, Y., Ren, Y., Zheng, L., Dai, X., Li, Y., Mao, W., Cui, Y., 2013. Anisakiasis in China: the first clinical case report. *Foodb. Pathog. Dis.* 10, 472–474.
- Repiso, O.A., Alcántara, T.M., González, F.C., Artaza, V.T., Rodríguez, M.R., Valle, M.J., Martínez, P.J.L., 2003. Gastrointestinal anisakiasis. Study of a series of 25 patients. *Gastroenterol. Hepatol.* 26, 341–346.
- Rodriguez, E., Anadon, A.M., Garcia-Bodas, E., Romaris, F., Iglesias, R., Garate, T., Ubeira, F.M., 2008. Novel sequences and epitopes of diagnostic value derived from the *Anisakis simplex* Ani s 7 major allergen. *Allergy* 63, 219–225.
- Rodríguez, H., González, Á.F., Abollo, E., Pascual, S., 2018. Re-evaluation of anchovies (*Engraulis encrasicolus*) as an important risk factor for sensitization to zoonotic nematodes in Spain. *Fish. Res.* 202, 49–58.
- Rodriguez-Mahillo, A.I., Gonzalez-Munoz, M., Gomez-Aguado, F., Rodriguez-Perez, R., Corcuera, M.T., Caballero, M.L., Moneo, I., 2007. Cloning and characterisation of the *Anisakis simplex* allergen Ani s 4 as a cysteine-protease inhibitor. *Int. J. Parasitol.* 37, 907–917.
- Rodriguez-Perez, R., Moneo, I., Rodriguez-Mahillo, A., Caballero, M.L., 2008. Cloning and expression of Ani s 9, a new *Anisakis simplex* allergen. *Mol. Biochem. Parasitol.* 159, 92–97.
- Rodriguez-Perez, R., Monsalve, R.I., Galan, A., Perez-Pinar, T., Umpierrez, A., Lluich-Bernal, M., Polo, F., Caballero, M.L., 2014. Cross-reactivity between *Anisakis* spp. and wasp venom allergens. *Int. Arch. Allergy Immunol.* 163, 179–184.
- Serracra, L., Battistini, R., Rossini, I., Carducci, A., Verani, M., Prearo, M., Tomei, L., De Montis, G., Ercolini, C., 2014. Food safety considerations in relation to *Anisakis pegreffii* in anchovies (*Engraulis encrasicolus*) and sardines (*Sardina pilchardus*) fished off the Ligurian coast (Cinque Terre national Park, NW Mediterranean). *Int. J. Food Microbiol.* 190, 79–83.
- Serrano-Moliner, M., Morales-Suarez-Varela, M., Valero, M.A., 2018. Epidemiology and management of foodborne nematodiasis in the European Union, systematic review 2000–2016. *Pathog. Glob. Health* 112, 249–258.
- Shamsi, S., Butcher, A.R., 2011. First report of human anisakidosis in Australia. *Med. J. Aust.* 194, 199–200.
- Shamsi, S., Sheorey, H., 2018. Seafood-borne parasitic diseases in Australia: are they rare or underdiagnosed? *Intern. Med. J.* 48, 591–596.
- Shamsi, S., Norman, R., Gasser, R., Beveridge, I., 2009. Genetic and morphological evidences for the existence of sibling species within *Contracaecum rudolphii* (Hartwich, 1964) (Nematoda: Anisakidae) in Australia. *Parasitol. Res.* 105, 529–538.
- Shamsi, S., Eisenbarth, A., Saptarshi, S., Beveridge, I., Gasser, R.B., Lopata, A.L., 2011. Occurrence and abundance of anisakid nematode larvae in five species of fish from southern Australian waters. *Parasitol. Res.* 108, 927–934.
- Shih, H.H., 2004. Parasitic helminth fauna of the cutlass fish, *Trichiurus lepturus* L., and the differentiation of four anisakid nematode third-stage larvae by nuclear ribosomal DNA sequences. *Parasitol. Res.* 93, 188–195.
- Shimamura, Y., Muwanwella, N., Chandran, S., Kandel, G., Marcon, N., 2016. Common symptoms from an uncommon infection: gastrointestinal anisakiasis. *Chin. J. Gastroenterol. Hepatol.* 6, 5176502.
- Smith, J.W., Wootton, R., 1978. *Anisakis* and anisakiasis. *Adv. Parasitol.* 16, 93–163.
- Sohn, W.M., Kang, J.M., Na, B.K., 2014. Molecular analysis of *Anisakis* type I larvae in

- marine fish from three different sea areas in Korea. *Korean J. Parasitol.* 52, 383–389.
- Sohn, W.M., Na, B.K., Kim, T.H., Park, T.J., 2015. Anisakiasis: report of 15 gastric cases caused by *Anisakis* type I larvae and a brief review of Korean anisakiasis cases. *Korean J. Parasitol.* 53, 465–470.
- Sumner, J., Anantanawat, S., Kiermeier, A., McLeod, C., Shamsi, S., 2015. Raw fish consumption in Australia: how safe is it? *Food Aust.* 67, 24–26.
- Suzuki, J., Murata, R., Hosaka, M., Araki, J., 2010. Risk factors for human *Anisakis* infection and association between the geographic origins of *Scomber japonicus* and anisakid nematodes. *Int. J. Food Microbiol.* 137, 88–93.
- Takabayashi, T., Mochizuki, T., Otani, N., Nishiyama, K., Ishimatsu, S., 2014. Anisakiasis presenting to the ED: clinical manifestations, time course, hematologic tests, computed tomographic findings, and treatment. *Am. J. Emerg. Med.* 32, 1485–1489.
- Tejada, M., Olivares, F., de las Heras, C., Careche, M., Solas, M.T., Garcia, M.L., Fernandez, A., Mendizabal, A., Navas, A., Rodriguez-Mahillo, A.I., Gonzalez-Munoz, M., 2015. Antigenicity of *Anisakis simplex* s.s. L3 in parasitized fish after heating conditions used in the canning processing. *J. Sci. Food Agric.* 95, 922–927.
- Toyoda, H., Tanaka, K., 2016. Intestinal anisakiasis treated successfully with prednisolone and olopatadine hydrochloride. *Case Rep. Gastroenterol.* 10, 30–35.
- Umebara, A., Kawakami, Y., Matsui, T., Araki, J., Uchida, A., 2006. Molecular identification of *Anisakis simplex* sensu stricto and *Anisakis pegreffii* (Nematoda: Anisakidae) from fish and cetacean in Japanese waters. *Parasitol. Int.* 55, 267–271.
- Valentini, A., Mattiucci, S., Bondanelli, P., Webb, S.C., Mignucci-Giannone, A., Colom-Llavina, M.M., Nascetti, G., 2006. Genetic relationships among *Anisakis* species (Nematoda: Anisakidae) inferred from mitochondrial cox-2 sequences, and comparison with allozyme data. *J. Parasitol.* 92, 156–166. <https://doi.org/10.1645/GE-3504.1>.
- Valls, A., Pascual, C.Y., Martin, E.M., Cavanna, J., 2003. *Anisakis* and anisakiosis. *Allergol. Immunopathol.* 31, 348–355.
- Van Thiel, P.H., Kuipers, F.C., Roskam, R.T., 1960. A nematode parasitic to herring, causing acute abdominal syndromes in man. *Trop Geogr. Med.* 2, 97–113.
- Van Thiel, P.H., 1962. In: *Anisakiasis. Parasitol.* vol. 52. pp. 16–17.
- Vaughan, S., Sadler, M., Jayakumar, S., Missaghi, B., Chan, W., Church, D.L., 2015. An unusual case of abdominal pain. *Can. J. Infect Dis. Med. Microbiol.* 26, 297–298.
- Vidaček, S., de las Heras, C., Solas, M.T., Mendizabal, A., Rodriguez-Mahillo, A.I., González-Muñoz, M., Tejada, M., 2009. *Anisakis simplex* allergens remain active after conventional or microwave heating and pepsin treatments of chilled and frozen L3 larvae. *J. Sci. Food Agric.* 89, 1997–2002.
- Villazanakretzer, D.L., Napolitano, P.G., Cummings, K.F., Magann, E.F., 2016. Fish parasites: a growing concern during pregnancy. *Obstet. Gynecol. Surv.* 71, 253–259.
- World Health Organization, 2012. Soil-transmitted Helminths. World Health Organization. Accessed on 31-03-2019 from. http://www.who.int/intestinal_worms/en/.
- Yera, H., Frealle, E., Dutoit, E., Dupouy-Camet, J., 2018. A national retrospective survey of anisakidosis in France (2010-2014): decreasing incidence, female predominance and emerging allergic potential. *Parasite* 25, 23. <https://doi.org/10.1051/parasite/2018016>.
- Yorimitsu, N., Hiraoka, A., Utsunomiya, H., Imai, Y., Tatsukawa, H., Tazuya, N., Yamago, H., Shimizu, Y., Hidaka, S., Tanihira, T., Hasebe, A., Miyamoto, Y., Ninomiya, T., Abe, M., Hiasa, Y., Matsuura, B., Onji, M., Michitaka, K., 2013. Colonic intussusception caused by anisakiasis: a case report and review of the literature. *Intern. Med.* 52, 223–226.
- Zhao, W.T., Lu, L., Chen, H.X., Yang, Y., Zhang, L.P., Li, L., 2016. Ascaridoid parasites infecting in the frequently consumed marine fishes in the coastal area of China: a preliminary investigation. *Parasitol. Int.* 65, 87–98.