

Letter to the Editor

Administration of anti-HER2 antibody after nonmyeloablative allogeneic stem cell transplantation in metastatic breast cancer

GL Banna^{*,1}, SML Aversa¹, G Crivellari¹, C Ghiotto¹, V Chiarion-Sileni¹ and S Monfardini¹¹Division of Medical Oncology, Istituto Oncologico Veneto, Via Gattamelata 64, Padova 35100, Italy

British Journal of Cancer (2006) 94, 1550–1552. doi:10.1038/sj.bjc.6603114 www.bjcancer.com

Published online 25 April 2006

© 2006 Cancer Research UK

Sir,

We read with great interest the article by Arnould *et al* (2006). In their study, they investigated by immunohistochemistry (IHC) immune cell response during neoadjuvant primary systemic therapy with trastuzumab and docetaxel in patients with IHC 3+ HER2-positive primary breast cancer. Trastuzumab treatment was associated with significantly increased numbers of tumour-associated NK cells and lymphocyte expression of granzyme B and TiAI compared with controls. This suggests that trastuzumab plus taxanes lead to enhanced NK cell activity, thus confirming that NK cell activity via antibody-dependent cellular cytotoxicity (ADCC) is one of the mechanisms of action of trastuzumab, as similarly reported *in vivo* by other authors (Repka *et al*, 2003; Gennari *et al*, 2004). Furthermore, this observation may partially account for the synergistic activity of trastuzumab and docetaxel in breast cancer. In fact, taxanes lead to increased serum concentrations of some cytokines and enhancement of NK cell activity (Tsavaris *et al*, 2002).

Moving from the same considerations, along with the observation that graft-versus-tumour responses in metastatic breast cancer amount to 25–40% following nonmyeloablative allogeneic haemopoietic stem cell transplantation (NST) (Bishop, 2004), and that recognition by donor immune cells of minor histocompatibility antigens and tumour-specific and/or overexpressed antigens is the theoretical background for these alloimmune responses, we treated two patients with IHC 3+ HER2-positive metastatic progressive breast cancer with weekly trastuzumab administrations (4 mg kg⁻¹ intravenously (i.v.) the first dose, 2 mg kg⁻¹ i.v. the other doses) in case of disease progression (PD) following NST. In fact, we hypothesised that the use of antitumour monoclonal antibodies (moAbs) (such as trastuzumab) following NST might enhance the allogeneic ADCC against tumour cell targets, possibly avoiding undesirable graft-versus-host reactions; conversely, a cellular component might enhance the effects of antitumoural moAbs and vaccines directed against the HER2 antigen (Reilly *et al*, 2001; Disis *et al*, 2002; zum Buschenfelde *et al*, 2002; Wolpoe *et al*, 2003). Patients were treated in a clinical trial approved by an independent ethical committee and in accordance with the Helsinki Declaration. Written informed consent was obtained from the two patients before enrolment.

Patients were aged 40 and 49 years, respectively. Both were heavily pretreated with five and three chemotherapy lines (including docetaxel), respectively. Trastuzumab, radiotherapy and several hormonal treatments were administered to both patients and both had PD at the time of transplant; the first one had bone and liver metastases, and the second liver metastases.

Doses of 8.0 and 5.0 × 10⁶ kg⁻¹ lenograstim-stimulated CD34+ cells were given to the two patients, respectively, in both cases from an HLA-identical sibling (on day 0) following a reduced-intensity conditioning with thiotepa 10 and 5 mg kg⁻¹ i.v., cyclophosphamide 120 mg kg⁻¹ i.v. and fludarabine 120 mg m⁻² i.v. Graft-versus-host disease (GVHD) prophylaxis consisted of cyclosporin A and short-course methotrexate.

Neutrophils and platelets engraftment were rapidly achieved on days +13/+10 and +9/+11 after NST, respectively. Stable full donor chimerism (FDC) (by PCR analysis) on total cells was reached on day +28 in both patients. On separated peripheral myeloid and lymphoid cells, stable FDC was achieved on day +28 in the first patient and on days +130 and +170, respectively, in the second patient. Lymphoid FDC was reached following the first donor lymphocyte infusion (DLI) on day +140 in the second patient.

The first patient started weekly trastuzumab administrations on day +48, because of early liver PD. However, no disease response and/or GVHD were observed and the patient eventually died of liver PD 6 months later.

The second patient developed on day +71 grade 3 liver failure (according to NCI criteria v3.0) with jaundice, in the absence of other clinical signs of acute GVHD but with liver and right breast PD evidence. The patient was hospitalised and weekly trastuzumab was started. Trastuzumab resulted in a rapid decrease of serum bilirubin, transaminases, jaundice and hepatomegaly. Right breast recurrence disappeared, but subsequent liver PD was shown by a CT scan on day +98. Two DLIs were then administered on day +140 (dose of 1 × 10⁶ CD3+ kg⁻¹) and on day +178 (dose of 1 × 10⁷ CD3+ kg⁻¹), and 24 h later, the 10th and the 14th trastuzumab administration, respectively. On day +154, left supraclavicular nodes and right breast PD, along with an increase of CEA and CA15.3 serum markers and the development of a grade 4 liver failure occurred. A Kehr drain was positioned. On day +195, weekly paclitaxel 60 mg i.v. was added to trastuzumab, resulting in liver partial remission (PR) on day +288 (Figure 1) and clinical remission of left supraclavicular, right breast

*Correspondence: Dr GL Banna; E-mail: gbanna@yahoo.com

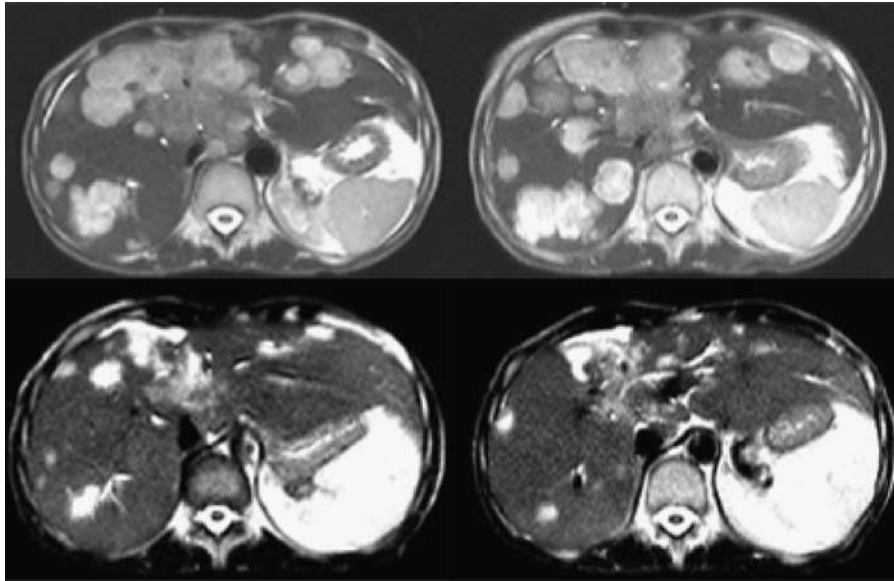


Figure 1 Abdomen T2-weighted MRI of day +220 after NST showing liver disease progression (upper images). Partial disease remission on day +288 after the addition of paclitaxel to trastuzumab (lower images).

Table 1 Blood T- and B-cell immunophenotypical analysis

Day after NST	+30	+60	+90	+135	+165	+250
WBC (μ l)	2750	13800	7150	4880	5710	2670
Lymphocytes (μ l)	750	170	350	680	2450	860
CD3+ (T cells) (%)	(68–82)	50	44	57	90	75
CD4+CD3+ (Th/ind) (%)	(36–52)	34	24	41	14	20
CD8+CD3+ (Ts/CTL) (%)	(20–34)	12	10	14	38	48
CD19+ (B cells) (%)	(5–16)	1	1	12	2	4
CD16+CD56+ (NK) (%)	(1.5–15)	43	31.3	25.7	39.7	20.9
CD3+CD16+						
CD56+ (Non-MHC-restr. CTLs) (%)	(1–9.7)	6	3	4	2	2
CD4+/CD8+	(1.5–2.1)	2.8	2.4	2.9	0.4	0.1

CTL, cytotoxic T-lymphocyte; MHC, major histocompatibility complex; NK, natural killer cells; Non-MHC-restr, non-major histocompatibility complex-restricted; NST, nonmyeloablative allogeneic haemopoietic stem cell transplantation; WBC, white blood cell.

relapse and normalization of serum tumour markers. Kehr's drain was removed on day +364. No signs of chronic GVHD were observed. The patient remained well and in PR until day +405, when liver PD reoccurred. Chemotherapies with gemcitabine, carboplatin and capecitabine were sequentially added to trastuzumab, but they were ineffective and the patient died on day +658. Of note, an increase of CD8 + CD3 + cytotoxic T cells and CD16 + CD56 + NKs was observed after NST by immunophenotypical blood T- and B-cell analysis, and a CD19 + cells peak was registered after the start of trastuzumab (see Table 1).

REFERENCES

- Arnould L, Gelly M, Penault-Llorca F, Benoit L, Bonnetain F, Migeon C, Cabaret V, Fermeaux V, Bertheau P, Garnier J, Jeannin JF, Coudert B (2006) Trastuzumab-based treatment of HER2-positive breast cancer: an antibody-dependent cellular cytotoxicity mechanism? *Br J Cancer* **94**: 259–267
- Bishop MR (2004) Allogeneic hematopoietic stem cell transplantation for metastatic breast cancer. *Haematologica* **89**: 599–605
- Disis ML, Gooley TA, Rinn K, Davis D, Piepkorn M, Cheever MA, Knutson KL, Schiffman K (2002) Generation of T-cell immunity to the HER-2/neu protein after active immunization with HER-2/neu peptide-based vaccine. *J Clin Oncol* **20**: 2624–2632
- Gennari R, Menard S, Fagnoni F, Ponchio L, Scelsi M, Tagliabue E, Castiglioni F, Villani L, Magalotti C, Gibelli N, Oliviero B, Ballardini B, Da Prada G, Zambelli A, Costa A (2004) Pilot study of the mechanism of

- action of preoperative trastuzumab in patients with primary operable breast tumors overexpressing HER2. *Clin Cancer Res* 10: 5650–5655
- Reilly RT, Machiels JP, Emens LA, Ercolini AM, Okoye FI, Lei RY, Weintraub D, Jaffee EM (2001) The collaboration of both humoral and cellular HER-2/neu-targeted immune response is required for the complete eradication of HER-2/neu-expressing tumors. *Cancer Res* 61: 880–883
- Repka T, Chiorean EG, Gay J, Herwig KE, Kohl VK, Yee D, Miller JS (2003) Trastuzumab and interleukin-2 in HER2-positive metastatic breast cancer: a pilot study. *Clin Cancer Res* 9: 2440–2446
- Tsavaris N, Kosmas C, Vadiaka M, Kanelopoulos P, Boulamatsis D (2002) Immune changes in patients with advanced breast cancer undergoing chemotherapy with taxanes. *Br J Cancer* 87: 21–27
- Wolpoe ME, Lutz ER, Ercolini AM, Murata S, Ivie SE, Garrett ES, Emens LA, Jaffee EM, Reilly RT (2003) HER-2/neu-specific monoclonal antibodies collaborate with HER-2/neu-targeted granulocyte macrophage colony-stimulating factor secreting whole-cell vaccination to augment CD8(+) T cell effector function and tumor-free survival in HER-2/neu-transgenic mice. *J Immunol* 171: 2161–2169
- zum Buschenfelde CM, Hermann C, Schmidt B, Peschel C, Bernhard H (2002) Anti-human epidermal growth factor receptor 2 (HER2) monoclonal antibody trastuzumab enhances cytolytic activity of class I-restricted HER-2-specific T lymphocytes against HER2-overexpressing tumor cells. *Cancer Res* 62: 2244–2247